



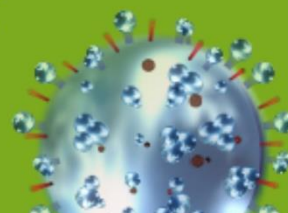
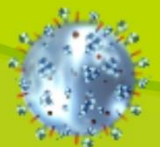
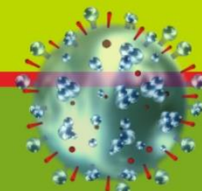
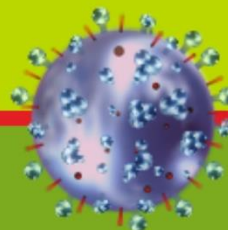
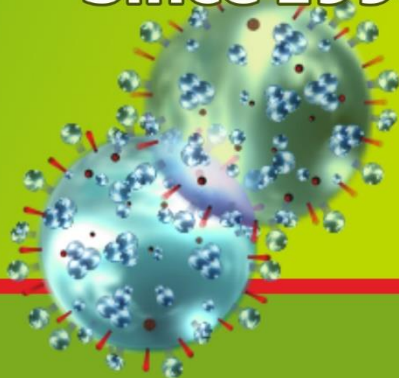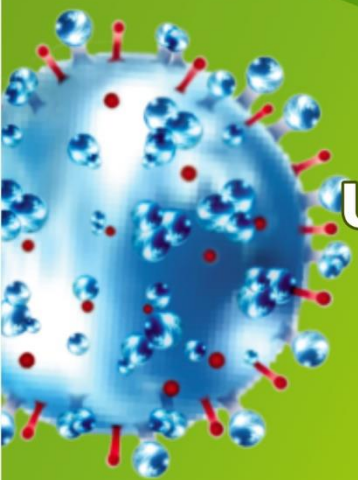
Jorge Derna, M.D.

PROLONGED INFLUENZA

- The New Influenza Epidemic -

A Pandemic and Endemic Disease 2013 / 2017

**Description of a New and
Until Now Unknown Disease
Since 1998 until now**



MISIONES - ARGENTINA

Descripción de una nueva enfermedad desconocida hasta la fecha
Description of a New and Until-now-unknown Disease

Description of a New and Until-now-unknown Disease
Jorge A. Derna

1st. Edition – Misiones: La Impresión S.A., 2007
257 pages; 15x21 cm (science – medicine)
ISBN 978 – 987-05-3604-8
1. Viral Diseases. I. Title

CDD 616.925

La Impresión, S.A.
Córdoba 1738 – Posadas, Misiones –Argentina
Graphic and Cover by Lilian López
With help from Ignacio Bernal
Secretary: Andrés A. Kozlowski

1st. Edition: December 2007

Printed in Argentina

The bank deposit prescribed by Act 11723 is done.
All rights reserved; no part of this publication may be reproduced, stored in a retrieval system, or transmitted in any form or by any means, electronic, mechanical, photocopying, recording, or otherwise without the prior written permission of the Publishers.

www.prolongedinfluenza.com
www.prolongedflu.com
www.prolongedflubymutation.com
www.influenzabymutation.com
www.anewunknowndisease.com

www.gripeprolongada.com
www.gripeprolongadamutacion.com
www.enfermedadesdesconocida.com
www.gripeprolongada.com.ar

**5TH UPDATED DIGITAL EDITION
THIS EDITION IS RELEASED IN FEBRUARY 2017**

DESCRIPTION OF A NEW AND UNTIL NOW UNKNOWN DISEASE

“Prolonged Influenza”

New prolonged viral disease of the respiratory system, other organs and systems. Caused by the influenza vaccine.

“Prolonged Influenza by Mutation”

- The New Influenza Epidemic -

New prolonged viral disease of the respiratory system, and other organs and systems.

It is produced by the virus of the influenza vaccine that has mutated and combined with the common influenza virus.

This books is dedicated to

- Thousands of people victims of this disease.
- Thousands of people who suffer this disease year after year.
- And to life defenders.
- Let's not regret any more deaths ever again.
- Let's prevent future epidemics and pandemics through new mutations.

December 2007

PROLOGUE

The main reason why this book has been published is to let people know about this new undiagnosed disease. So far this information has not been reported in any medical literature.

This undiagnosed disease is described in this book so that doctors will know it and recognize it so as to agree on a diagnosis and apply the correct medical treatment in order to heal, improve and prevent or diminish complications, and of course to save lives. Also, it is important that all medical centres and other concerned entities get aware of this problem. This new disease is a prolonged viral one that affects mainly the respiratory system and other organs and systems of the body. It is called "prolonged influenza" because of its resemblance to the common flu. However, in this case, it is more severe and it lasts longer -up to 30, 60, 90 days or more, with relapses.

The "prolonged influenza" was described in the year 1998 and its mutation, **so called** "prolonged influenza by mutation", in the year 2000. The latter has caused an increasing number of cases which led to an epidemic in the years 2004, 2005. It is still going on in 2013, displacing in that way the common flu.

This disease is produced due to the action of the virus of the influenza vaccine in 30 % of those who have been vaccinated. The "prolonged influenza" starts a few days after the vaccination, it lasts a long time and it leads to complications; it can be transmitted to others and it can even cause death. Also, the mutation that is produced from the combination with the virus of the common flu has brought about a new mutated virus which is more contagious. The new disease is called "Prolonged Influenza by Mutation".

Because of its major contagious effect, the "Prolonged Influenza by Mutation" has not only replaced the common flu but it also has exceeded it. This is a serious problem as we have suffered an epidemic during the last years, which can still cause a pandemic. If that happened, the virus would absolutely take a foothold in the world.

The influenza virus will mutate and combine with the avian flu virus, increasing its contagious capacity and duration. Its pathological effects and mortality will increase from 50 % to 80 or 90 %, thus producing new epidemics and pandemics killing millions of people. Thus, it is a more lethal and pathological avian flu virus which will bring about economical, social,

political, geographical, strategic and other consequences which are impossible to define yet.

For all the reasons mentioned above, this book is dedicated to safeguard life above anything else. Once again, this matter is presented to the national and international authorities. The mutation already exists, though it is still possible to take the corresponding health measures urgently so as to stop and solve this epidemic.

Other mutations will occur in the avian flu virus and in swine flu virus - type A, B and C and other known and unknown viruses. This will also lead to epidemics and pandemics which will kill millions of people.

This global warning is to avoid a new mutation of the avian flu virus and therefore avoid another serious disease.

The medical description of this disease is essentially based on clinical studies and epidemiology. This clinical description is complete, wide and detailed, **and is fundamentally based on the questioning to the patient or his relatives. This questioning is very lengthy, performed in the necessary time – longer than the common questioning – thus, there is 95% accuracy in the diagnostic.**

There is a clear epidemiologic relationship between this diagnosis and other similar cases along the years, even in those years of investigation.

Physical examinations and complementary methods help doctor to diagnose.

This description has seven parts:

Part I or main part. In this part the "Prolonged Influenza" is clinically explained together with its diagnosis and treatment. Then, there is a description and explanation of the "Prolonged Influenza by Mutation".

Part II includes other diseases that are treated with the antiviral **Oseltamivir** and other possible diseases that take the same treatment. It is important to be aware of these diseases since they can be treated efficiently despite the fact that the treatment is not known in worldwide medical literature.

Part III presents common testimonials provided by people who were affected by the influenza vaccine and suffered the "Prolonged influenza" - 1700 cases in the last 17 years.

Part IV. In this part, important medical observations on the people affected by the influenza vaccine are shown, data which is very important from the medical descriptive point of view.

Part V shows two clinical cases of sick people who were treated with the antiviral **Oseltamivir** and got good results: a viral **meningoencephalitis** due to the common type B flu and a primary viral pneumonia due to the common flu as well.

Part VI presents clinical cases of "Prolonged Influenza" affecting eleven patients. Some cases did not bring about complications and others not only did have complications but also caused death. In this way, we have a complete description of the different clinical cases and the seriousness of this disease.

Part VII presents five clinical cases of "Prolonged Influenza by Mutation". These patients had complications with different clinical presentations and a different level of seriousness.

Acknowledgments

Bibliography

INTRODUCTION

This descriptive medical research has been written in limited time due to the seriousness and importance of the matter, although data collection and laboratory analysis have been going on for 17 years in a deep and uninterrupted investigation. More than 1.700 interviews were held with people who had been given the influenza vaccine. 1000 out of them were infected afterwards. Since it cannot wait any longer to be presented, I am making this information available. This is A NEW DISEASE UNKNOWN UP TO DATE, which is the "Prolonged Influenza", and with mutations, the "Prolonged Influenza by Mutation". The purpose is that doctors become aware so as to diagnose, treat patients and save them from death.

Also, and once again, it is important to insist that Argentine and International authorities encourage the proper investigations and thus avoid Epidemics and Pandemics with the result of millions of sick people, deaths and the final establishment of a NEW INFLUENZA VIRUS and a NEW MUTATED INFLUENZA VIRUS in the world, which will surely have lasting consequences. Also, its mutations may once again mutate with another influenza virus, like the avian influenza virus or other. As a result this will have another mutated virus with a major lethal or pathogenic and contagious effect. Then, there will be Epidemics and Pandemics with millions of sick and dead people, not to mention the economic, social, cultural, geographic and political damage which is still impossible to define.

REQUEST

I request doctors, health professionals, health authorities, provincial, national and international authorities, Provincial, National, International or private institutions or any person or persons to help clarify, improve and go on with this investigation and thus to try to avoid this very serious situation.

This petition has to do with the scarce possibilities I have myself, because of a range of reasons, such as time, money and different kinds of pressure exercised on me, threats and persecutions of every kind to hide this disease.

In the following pages, I will describe my investigation step by step, in its level of development, consequences and final connotations.

WORLD ANNUAL TURNOVER

INFLUENZA VACCINE ESTIMATED ANNUAL REVENUE - SALES

20,000 MILLION DOLLARS
From Vaccine sales

+

10,000 million DOLLARS
In medications for Prolonged
Influenza (through the VACCINE)

TOTAL

30,000 million DOLLARS
From Prolonged Influenza
(Influenza acquired through the vaccine)

ESTIMATED ANNUAL SALES FROM MEDICATIONS FOR THE EPIDEMIC PROLONGED INFLUENZA (NOT FROM THE VACCINE)

Since 2006

100,000 million DOLLARS and going up

Annual Revenues Year 2006 = 100,000 million dollars

Annual Revenues Year 2013 = 140,000 million dollars

Annual Revenues Year 2014 = 200,000 million dollars

Annual Revenues Year 2015 = 250,000 million dollars

Annual Revenues Year 2016 = 300,000 million dollars

Annual Revenues Year 2017 = 350,000 million dollars

Annual Revenues Year 2018 = 400,000 million dollars

PART I

1 - "PROLONGED INFLUENZA"

New prolonged viral disease of the respiratory system, other organs and systems. Caused by the influenza vaccine.

2 - "PROLONGED INFLUENZA BY MUTATION" - The New Influenza Epidemic -

New prolonged viral disease of the respiratory system, and other organs and systems.

It is produced by the virus of the influenza vaccine that has mutated and combined with the common influenza virus.

PART I

1. "PROLONGED INFLUENZA"

A new prolonged viral disease of the respiratory system, other organs and systems. Caused by the influenza vaccine.

1. DEFINITION

- It is an acute infectious disease that affects the respiratory system, the high and low respiratory tree. It has a viral origin, it is contagious and prolonged, with various relapses.
- It can also present with a "retarded effect".
- It affects other organs and systems, besides the respiratory system.
- The viral etiology is unknown up to now and it is stated to be an influenza virus.
- This virus may be an unknown influenza virus, a mutated influenza virus or a new unknown virus.

Diseases - other from the respiratory system:

1- Cardiologic	1. Coronary disease	Unstable angina. Acute myocardial infarction
	2. Alterations in the conduction - Blocking.	
	3. Valve alterations - Aortic valve.	
	4. Myocardial alterations. Acute myocarditis.	
	5. Cardiac insufficiency.	
	6. Pericarditis.	
	7. Sudden death.	
	8. Cardiac arrhythmia - Acute atrial fibrillation.	
2- Hematologic	1. Thrombocytopenia.	
	2. Thrombocytosis.	
	3. Leukopenia.	
	4. Leukocytosis.	
3- Nephrologic	1. Acute and chronic kidney insufficiency	
	2. Temporary kidney damage (vascularitis). (A <u>well known and reported disease</u>).	
4- Neurologic	1. Stroke.	
	2. Encephalitis.	
	3. Neuritis (Limbs) .	

	4. Guillain Barré. 5. Encephalomyelitis. 6. Narcolepsy	Well-known reported diseases.
5- Eye trouble	1. Decrease in vision.	
6- Ear trouble	1. Hearing loss.	
7- Smell trouble	1. Smell loss.	
8- Dermatologic	1. Atopic dermatitis. 2. Pigmented Purpuric Dermatitis. 3. Red Lichen Planus (Confirmed by biopsy).	
9- Arterial	1. Possible arterial hypertension. 2. Possible arteritis with endarteritis or vasculitis. 3. Possible thrombosis – embolism.	
10- Psychiatric	1- <u>Depression</u> : due to a medical condition. <ul style="list-style-type: none"> • Sadness. • Anguish. • Tears. • Lack of interest. • Sleep alterations. 2- <u>Anxiety</u> : as a reaction to uncertainty from a disease that is unexplained and threatens life. <ul style="list-style-type: none"> • Worry. • Uncertainty. • Nightmares. 	
11- Gynecologic:	Possible inflammation of the endometrium with or without metrorrhagia.	
12- Obstetric:	Fetal death, abortion, hand agenesis and polyhydramnios.	
13- Endocrinologic:	Type II diabetes.	
14- Other conditions not described yet.		

2. ETIOLOGY

- Unknown virus until now
- It has affected people since the 50s.
- It is transmitted by the anti-influenza vaccine
- It is said to be a flu virus
- Viral etiology, shown by 1. Clinical examination 2. Epidemiology 3. Contagion

Hypothesis stated	1- Known mutated flu virus (Type A or other).
	2- New unknown flu virus.
	3- New unknown virus.

Possible hypothesis	4- Other known virus. Flu or another virus.
	5- Other microorganisms.
	6- Other causes.

1- **Known mutated flu virus:**

- A mutated flu virus from the flu vaccine from two of the three strains, in the chicken egg (culture), in the vaccine or in a man.
- A mutated flu virus from the three strains of the flu vaccine, a recombination or a mutation of the three strains, produced in the egg (culture), in the vaccine or in a man
- A mutated flu virus from the two-strain combination vaccine, originating a new virus which combined with the third strain giving origin to another mutated virus (double mutation). In the chicken egg, in the vaccine or in a man.
- A flu virus mutated from the flu vaccine made from a combination of a flu virus present in the chicken egg (host) and a vaccine strain that evolved into a new mutated type-A flu virus which is not highly contagious but is very aggressive . Produced in the chicken egg, in the vaccine or in a man.

Other possible combination variants:

- Either with two or three strains or a re-combination or double or triple mutation or a diverse interrelationship
- other variants of mutated flu viruses
 - Other mutated variants or a combination between a flu virus and another microorganism that is not a virus: i.e. Chlamydia, mycoplasma or known or unknown microorganisms.

2 – New unknown flu virus:

- A new unknown flu virus has appeared and combined with a flu virus strain. It is a double or triple recombination or a diverse interrelationship, in the chicken egg or in the vaccine.
- A new unknown flu virus has appeared in the egg or in the vaccine, alone and independent.
- A new unknown flu virus, added in the egg or in the vaccine, alone and independent.

3 – New unknown virus:

- a) A new unknown virus has appeared, combined with a flu virus strain or a double or triple recombination or a diverse interrelationship, in the chicken egg or in the vaccine.
- b) A new unknown virus has appeared in the egg or in the vaccine, alone and independent.
- c) A new unknown virus, added in the egg or in the vaccine, alone and independent.

4 – Other known viruses:

- a) Other known viruses appeared in the egg or in the vaccine.
- b) Other known viruses have appeared, with a mutation of a flu virus strain, of two or three strains, or other variants, in the egg or in the vaccine.

5- Other microorganisms:

- a) Other microorganisms not identified yet, alone or mutated with a flu virus or another virus, in the egg or in the vaccine.

6- Other causes:

- a) Other causes which have not been identified yet.

3. THE FUNDAMENTALS OF THE DIAGNOSIS OF THIS NEW DISEASE

The diagnosis of this new disease is based on the following four fundamental pillars:

- 1) Clinical practice: a respiratory disease, which is acute, infectious, viral, prolonged and contagious, called "prolonged influenza", which started after the anti-influenza vaccine was injected.
- 2) Epidemiology: It is the spread of the same disease at the same time
 - a) To thousands of people, hundreds of thousands and millions of people.
 - b) In different geographical areas, either in several cities of one province or several provinces at the same time, throughout the Argentine Republic, and in other countries such as Paraguay, the United States of America, Brazil, Spain and other countries in the whole world.
 - c) The repeat outbreaks of this disease every year from 1998 to 2013 and they still occur. According to patients, this disease was first seen in the 50s, and every year since then, there have been repeat progressive outbreaks.
- 3) Transmission: people who became ill after they were given the anti-influenza vaccine have transmitted the virus to healthy non-vaccinated people, mainly close relatives.
- 4) Lab tests of the anti-influenza vaccines have been requested since 1999 until this year 2013. The vaccines – commercial brands and batch numbers are available – were held responsible for the disease in the years 1999, 2000, 2005, 2006, 2007, 2008, 2010, 2011 and 2012. There tests were never performed although they were urgently asked lots of times.

In 1999, the Instituto Malbrán performed lab test of some vaccines, but not the ones request. The suspected vaccines were replaced by other brand names and batches. It was reported that there was no bacterial or fungal contamination and lab animals had not been affected. But the suspected vaccines were NOT analyzed. No tests were performed to detect live virus because these kinds of tests are only performed abroad.

Comments:

The diagnosis of this disease is mainly based on points 1) and 2) above, i.e. the clinical examination and Epidemiology. These are basic important fundamentals on which this strong diagnostic assertion is based.

Furthermore, contagion is very important to make this diagnostic affirmation of a clinically viral contagious disease, as it is explained in point 3) above As regards point 4) above, it is important to say that no complete, clear, true and etiological vaccine laboratory analysis has been performed.

4. ANATOMY

An important inflammation of all the respiratory system, in the upper and lower respiratory tract, the arterial blood vessels and other organs and systems.

Pathological Anatomy:

Most logical hypothesis.

- a) The severe inflammatory process of all the respiratory system (upper and lower respiratory tract).
 - a.1 the injury and necrosis of the epithelium of the respiratory tract.
 - a.2 the injury of the mucosa and sub mucosa of the respiratory tract.
 - a.3 the injury of the nose, paranasal sinuses, pharynx, larynx, trachea, bronchial tubes, and all the respiratory tract, bronchioles, bronchia, alveoli and alveolar membrane.
- b) the inflammatory process of the arteries.
 - b.1 the injury of the endothelium of small and medium arterial blood vessels and arterioles; due to an important inflammatory process in the arteries causing an "unspecific arteritis", endarteritis or vasculitis, with a possible complication with thrombosis and / or embolism, causing ischemia or infarctions in different organs or systems (heart, brain, kidneys, skin and others).

Corroboration

- It has been confirmed that this disease causes a temporary kidney injury due to vasculitis, a well-known reported illness.
- An extremely inflammatory reaction was detected in the sputum analysis and in a C.R.P and an E.S.R.
- Using a laryngoscope, the important inflammation of the larynx and vocal chords.
- Also rhinitis, pharyngitis and sinusitis.
- Diagnosis: Red Lichen Planus (Confirmed by biopsy).

Comments

I insist that all physicians, professionals, or just any people or any kind of institutions or countries that could carry on a research should do so, so as to complete and upgrade this diagnosis of the disease.

Such research would ensure better medical knowledge and would benefit lots of people.

5. PATHOPHYSIOLOGY

The pathophysiological mechanism is caused by an important inflammatory process.

Due to the following hypothesis:

- 1- **A direct viral injury to the whole respiratory system**, the epithelium, mucosa and sub mucosa of the whole respiratory tract, upper and lower respiratory tract, bronchioles, alveoli and alveolar membrane.
- 2- **A direct viral injury to arterial blood vessels**, of medium or small calibre and arterioles by an important inflammatory process that causes "unspecific arteritis", which injures the endothelium, endarteritis, and a complication such as thrombosis and/or emboli, which causes ischemias or infarctum to tissues and organs, is possible.
- 3- **A direct injury in arteries caused by immune complex**, "unspecific arteritis", endarteritis, and a complication such as thrombosis and/or emboli, which causes ischemias or infarctum to tissues and organs, is possible.

Confirmed injuries

The inflammation of blood vessels, vasculitis, with temporary kidney injury, a well known reported disease.

Comments:

In arteries previously damaged in all its structure or in the endothelium due to different basic diseases, such as atherosclerosis (plaques), metabolic diseases or rheumatism, degenerative conditions, could predispose patients to a direct injury or by immune complexes, that would affect selective or partially these areas with previous conditions, and a complication such as thrombosis and/or emboli, which causes ischemias or infarctum to tissues and organs, is possible.

6 . DESCRIPTION OF CLINICAL SYMPTOMS AND DIAGNOSIS

- The symptoms of the disease start after the influenza vaccine is taken.
- A period of incubation of seven days average with the appearance of the clinical symptoms of an acute viral infectious disease, that affects the general well-being and the high and low respiratory tract. The incubation period can change and the symptoms can start just after a few hours - the minimum incubation period is 5 (five) hours
- There is a 15 or 30-day acute period, and then a subacute period of thirty to sixty days; then, it worsens again during a period of one to three months or longer. The clinical symptoms last three months average.
- After three months the subacute symptoms can go on with relapses which last one, three, six, nine, twelve or more months, in a frequent and recurrent way, its severity diminishing progressively and slowly until the patient recovers.
- After a few months, or one year or more after the patient has become sick, there may be a relapse, but shorter and less severe, which would be a delayed effect with a duration of 15, 30, 60 days or more (30 days average)
- There are lots of complications of the respiratory system, and other organs and systems.
- Lots of patients have different consequences such as rhino-sinusitis, larynx complications, tone and pitch of the voice, bronchial, pulmonary, cardiac complications, kidney trouble, neurological, vascular problems, trouble with the ears, eyes, olfactory senses, etc.
- It is worth pointing out that the disease can appear in a few hours or days, with the same intensity, very quickly, in an over-acute clinical way.
- The different clinical forms vary according to the duration and the intensity of the disease (they generally occur in a period of 90 days after the patient is given the shot, in average)
-

Clinical Forms : classification according to its duration

- 1- Severely acute (it starts a few hours after the patient has been given the shot and lasts up to one month).
- 2- Acute (it lasts up to 3 months)
- 3- Sub-acute (it lasts up to 6 months)
- 4- Chronical (it lasts more than 6 months)
- 5- Delayed Effect (short, medium and long term)

1. Severely acute: this clinical form has a shorter incubation period (less than 7 days), that begins a few hours after the vaccine is given and lasts up to one month. It shows more complications and a higher mortality rate.
2. Acute: it is the most frequent clinical form.(It is described in the clinical table)
- 3- 4- 5 The sub-acute, chronical and delayed effect forms have the same frequency as the acute clinical form.

Clinical Forms: classification according to its intensity:

1. Mild
 2. Moderate
 3. Severe
 4. Extremely serious
-
1. Mild: when life is not at risk and the symptoms can be controlled.
 2. Moderate: when life is already at risk and there is respiratory insufficiency, with or without bronchospasm and little or no alteration of gases in blood.
 3. Severe: when life is at risk with more serious respiratory insufficiency, greater alteration of gases in blood and/or pulmonary complications and or cardiac, renal, brain or other symptoms.
 4. Extremely serious: when life is at risk, the clinical examination shows extreme respiratory insufficiency, with severe alteration of gases in blood that requires mechanical ventilation, respiratory distress, viral primary unilateral or bilateral viral pneumonia, combined viral and bacterial or over-infected with bacteria (secondary pneumonia). There may be complications with the heart, the kidneys, the brain, etc. See chart 1.

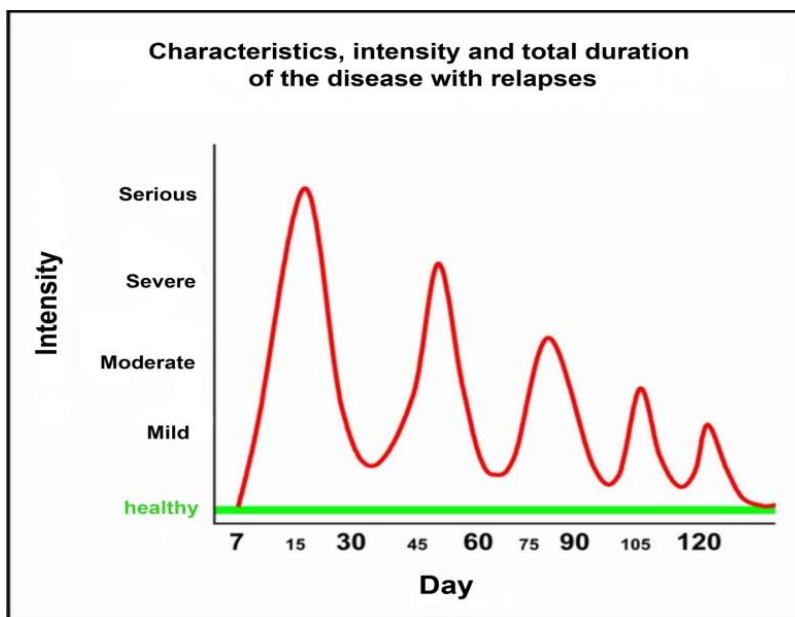


Chart 1 Prolonged influenza

Description of the Delayed Effect at short, medium and long term

DEFINITION:

The delayed effect is defined as the repeated onset of a disease after some time has passed since the patient was cured, presenting with complications or the disease becoming acute again.

The cure is defined as the absence of symptoms and signs of the disease in the patient and shows a 100% recovery or the patient feels as he felt before he became ill.

This delayed effect is classified according to the moment when it appears:

- Short term: it is the second onset of the disease during the first, the second or the third month after the recovery.
- Medium Term: it is the second onset of the disease from the fourth month to the year after the person was cured.
- Long term: it is the second onset of the disease after a year or years.

This delayed effect has the same clinical signs and symptoms that the prolonged influenza has, but it is less intense and shorter; with direct complications such as rhinitis, sinusitis, laryngitis, bronchitis, bronchial spasm, bronchiolitis (in adults, young people and children), pneumonia, bronchial pneumonia, unstable angina, myocardial infarction, pericarditis, kidney failure, stroke and other pathologies already described or others not described yet.

The delayed effect may last 15, 30, 60 or more days (average 30 days). This effect can appear at any time of the year, but mainly in autumn, winter and spring (with the cold weather).

It can also appear more than once in the same year, either during the first month or the next ones.

For example, a patient can develop two pneumonias or two pulmonary decompensations in the same year.

This could happen because the virus could stay latent alive in a healthy carrier. The virus could have some pathogenic characteristics that would reactivate it and the same disease would develop, mainly in autumn, winter and spring in the following years, favoured by the cold weather. Never does this disease develop before the influenza vaccine is given, with these clinical characteristics, with pulmonary or non-pulmonary complications and with delayed effect. (See chart 2 and the case of medium-term delayed effect)

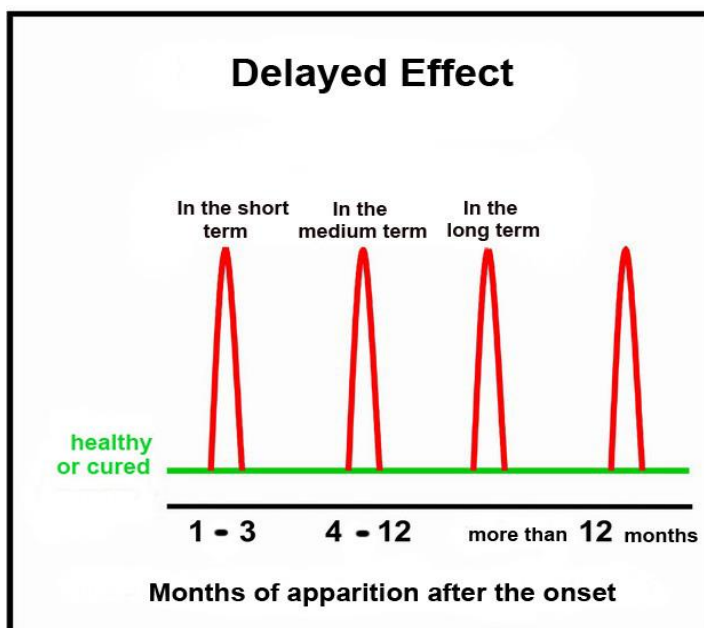


Chart 2 Delayed Effect

DESCRIPTION OF A CASE OF MEDIUM-TERM DELAYED EFFECT

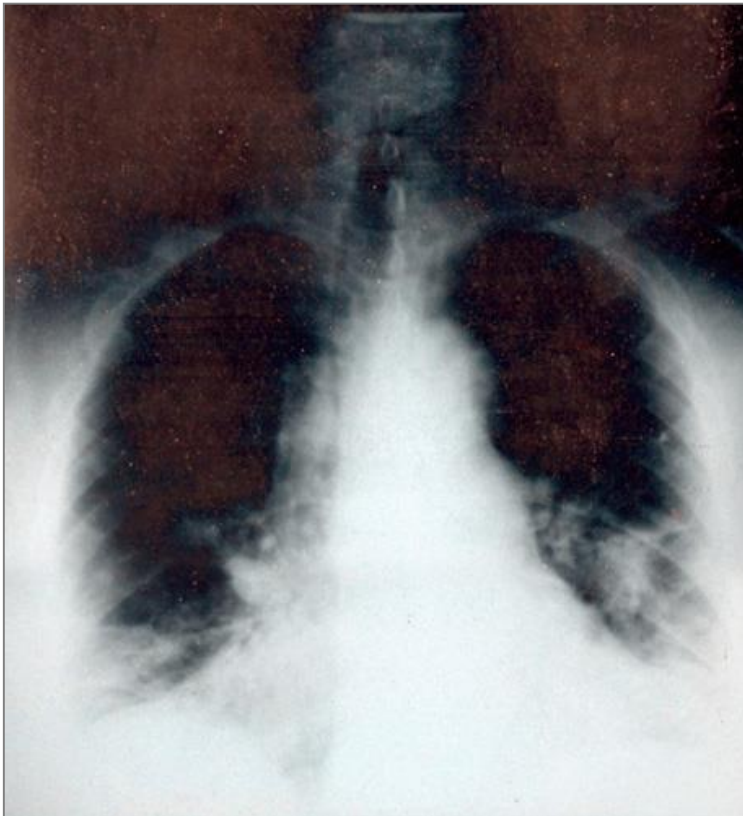
Prolonged influenza and medium-term delayed effect complicated with primary viral bilateral pneumonia.

A 74-year-old female patient who was given the influenza vaccine in June 2005, showing signs and symptoms of prolonged influenza with several relapses for 6 months.

In July 2006, not having been given the shot, she showed acute symptoms for 45 days, complicated with a diagnosis of viral bilateral pneumonia.

The patient decided not to have the vaccine again in 2006, because she had been severely ill in 2005.

She had never had pneumonia before.



Viral Bilateral Pneumonia

See interstitial and alveolar infiltrates involving both lower lung fields, predominantly the left lung (July 2006).

Clinical signs and symptoms of “Prolonged influenza”

- The symptoms start after the vaccine is taken.
- The incubation period is 7 days long in average, but it can be shorter, even 1 day long. In some cases, a period of incubation of just a few hours is seen. Symptoms start after an incubation period of at least 5 hours, or 10 or 15 days.

- Symptoms may start abruptly after a few hours or days. But they can also start slowly or progressively, and after a few days, the patient develops all the symptoms (on the seventh day or even the 15th. Day).

1- Signs and Symptoms:

The disease usually begins with the following symptoms:

General malaise

Intense asthenia

Arthromyalgia

Fever. Temperature is in most cases at 38° C (100.4°F) or under it, and in some few cases over it.

Headache. It is most common in the frontal region, less common in the occipital region and seldom in the combined fronto-occipital region, with variable intensity - mild, moderate or severe intensity; this last one occurs more often.

Rhinitis: at the beginning it is muco-serous. It can go on like this indefinitely or it can become muco-purulent. The intensity of the secretion can be slight or moderate, but generally, it is copious. Afterwards there is a third kind of secretion, with novel unknown characteristics. It is white, thick and sticky and it lasts many days. It has never been suffered by the patient nor seen by the physician, and has never been described.

Sneezing, a different kind of sneezing, intense and with rapid fits, impossible to stop; in a few seconds a patient can sneeze ten times, one after the other. Sneezes are persistent and repetitive, they appear from 3 to 6 times a day and they last about 4 or 5 days. The patient has never experienced them.

Photophobia

Cough, generally irritative, bothering and persistent, can last up to the end. Generally, it is very intense.

Sputum production is generally mucous and serous up to the end. Some patients develop mucous -purulent sputum.

After having any of these two kinds of sputum described above, there may be different sputum, which is white, thick and sticky, that lasts many days and that has never been seen neither by the patient nor by the physician. This is a novel characteristic which has never been described before.

Dysphonia, which is intense and lasting, does not recede quickly and lasts for days, weeks and maybe months, improving and relapsing.

A sore throat and trachea. The pain can be slight, moderate or severe. It is very annoying and has never been suffered by the patient. It can last for a long time, days, weeks or months, improving and worsening again.

Dry hot throat. This characteristic is unique too and has never been suffered before. Patients report it to be very disagreeable.

Epiphora

Anorexia

Sweating, in the evening, or at night

Shaking

Back ache

Bronchospasms, in different degrees of intensity, mild, moderate and severe. Severe bronchospasm is the most common one. If the patient is asthmatic or has a chronic pulmonary condition, bronchospasms become more severe

and last longer. Another important characteristic is that they are suffered by healthy people and by patients who have controlled non-pulmonary diseases, such as, diabetes, hypertension, cardiac conditions, kidney disease, etc.

Dyspnea. Grade 2, grade 3, grade 4 dyspnea showing severe conditions of respiratory distress.

Other less frequent symptoms and signs are:

Dizziness

Retro orbital pain

Vision loss – visual impairment

Leg pain

Maxillary sinus pain

Otalgia

Olfactory loss

In a few cases, diarrhea

Leg paresthesia

Loss of taste

Insomnia

Trouble walking

Vertigo

Insomnia

Hearing loss

Balance disorder

Epistaxis

Hemoptysis

Dermatitis

Worry

Uncertainty

Sadness

Anguish

All the signs and symptoms are given in the following frequency table:

Frequency of all signs and symptoms in 106 cases

Symptoms and signs	Out of 106 cases
Asthenia	101
Cough	98
Rhinitis	94
Arthromyalgia	85
Expectoration	80
Headache	77
Fever	75
Dysphonia	66
Sore throat and tracheal pain	46
Sneezing	46
Bronchospasm	42
Photophobia	37
Dyspnea	32

Back ache	29
Anorexia	23
Epiphora	18
Dry hot throat	17
Sinusitis	11 (16)
Body shakes	11
Sweating	10
Dizziness	9
Nausea	8
Conjunctivitis	7
Weight Loss	6
Retro orbital Pain	6
Vision loss	6
Leg pain	5
Maxillary sinus pain	5
Otalgia	5
Olfactory loss	5
Diarrhea	4
Arm pain	3
Epigastric pain	3
Palpitations	3
Leg paresthesia	2
Vomit	2
Taste loss	2
Purpuric dermatitis	2
Hypersomnia	2
Low blood pressure	2
Trouble walking	2
Hemoptysis	2
Insomnia	1
Vertigo	1
Halitosis	1
Head Dysesthesia	1
Ear loss	1
Memory loss	1
Erythroderma	1
Generalised itching	1
Itching	1
Loss of balance	1
Back head pain	1
Bradycardia	1
Aphthous ulcers in the mouth	1
Thirst	1
Leg edema	1
Paleness	1
Epistaxis	1
Worry	1
Uncertainty	1
Nightmares	1

Sadness	1
Anguish	1
Tears	1
Lack of interest	1
Sleep disorders	1

Sinusitis (11) plus maxillary sinus pain (5). Total number: 16

References: Most frequent signs and symptoms.

2 – Physical examination

The patient shows congestive rhinitis and a red pharyngitis, different levels of dyspnea, bronchospasm with different levels of severity, roncus and sibilance, sub-crepitant rales in medium and bottom lobes, (mainly the latter). There can also be some cyanosis showing severity of hypoxemia and lung failure.

Very few data can be obtained in the physical examination, with diffuse infiltrates in the chest x-ray, in one or both lungs (clinical-radiological dissociation).

Signs and symptoms of bronchilitis and a lot of dyspnea, also bronchospasm, crepitant and sub-crepitant rales, with great consequences of moderate or severe respiratory insufficiency. Paradoxically, only few important images can be seen in chest x-rays, only a congestion in the bronchovascular and hilar shafts.

Therefore, there is a contrast between the few radiological images and a lot of clinical signs (it would be the contrary to the clinical radiological dissociation).

Comments:

Bronchospasm also appears in healthy patients and in patients with non-pulmonary diseases that have never suffered it before.

Bronchospasm appears in asthmatic patients, who comment on the increased intensity of their bronchospasm and how long it has lasted, longer than ever before the vaccine was given.

They have also had bronchospasm at unusual times of the year.

Patients with Chronic-Obstructive-Pulmonary Disease (C.O.P.D.) note the same changes in the intensity of their dyspnea and longer periods of respiratory insufficiency never undergone before.

There may be also some respiratory complications, like pneumonia, bacterial infections and others.

There may be some non-respiratory complications, like hematological, or neurological complications.

Comparison Chart of Influenza (a well-known disease) and Prolonged influenza

Influenza (the well-known disease)	Prolonged influenza
Maximum duration: 7-9 days	Duration: 30, 60, 90, 120 days or longer

Acute duration: 4 days	Acute duration: 30 days
Intensity: common	Intensity: severe
Usual treatment: the condition improves	Usual treatment: the condition does not improve
It does not worry the patient	It worries the patient
The patient knows about the disease	The patient does not know about the disease
A condition that has been suffered before	A condition never suffered before (1 st . time)

Acute duration of the disease: it is variable and can last from 1 day up to 90 days. The most frequent one is from 15 to 30 days.

Bed rest: Most patients, about 50% had to rest in bed due to the greater intensity of the disease. This bed rest is variable and may last from 1 to 60 days; the most frequent one is from 3 to 10 days average.

Relapses: Relapses occur frequently in this disease, which may vary from 1 to 12, but the average is generally 3. The average duration of each relapse is 7 days and can vary from 1 to 60 days.

Total duration of the disease including relapses or recurrence: It is variable and can last from 1 day to 1 year or longer, but 30, 60, 90 and 120 days are commoner (average: 90 days)

Most patients are given a lot of medication, which shows the intensity of the disease.

* To see a better explanation of the difference between influenza and "Prolonged influenza" see the comparative chart.

7. COMPLICATIONS

Complications appear

- 1 - In the respiratory system or
- 2 - Out of the respiratory system.

1. Complications in the respiratory system

- 01) Chronic rhinitis
- 02) Acute and chronic sinusitis
- 03) Laryngitis – alteration of the voice (dysphonia)
- 04) Tracheitis
- 05) Repetitive and chronic (for several years) bronchitis
- 06) Bronchial spasm
- 07) Bronchiolitis

- 08) Bacterial bronchial secondary infection
- 09) Pneumonitis
- 10) Primary viral pneumonia (unilateral and bilateral).
- 11) Mixed viral bacterial pneumonia
- 12) Secondary bacterial pneumonia
- 13) Respiratory distress
- 14) Respiratory insufficiency in different degrees: mild, moderate, severe and lethal
- 15) Pleural effusion
- 16) Acute pleural inflammation
- 17) Possible bronchoalveolitis
- 18) Possible alveolitis
- 19) Others not described yet

2. Complications out of the respiratory system

- | | | |
|----------------|---|---|
| 1- Cardiologic | { | <ul style="list-style-type: none"> 1. Coronary disease <ul style="list-style-type: none"> a) Unstable angina or relapse. b) Acute myocardial infarction. 2. Alterations in the conduction: Sinus Node disease (bradycardia) with a definite pacemaker.
First Degree AV Block. Third Degree AV Block (complete). 3. valves: worsening of a previously existing valve disease (Aortic valve). 4. Myocardial alterations. Acute myocarditis. 5. Cardiac insufficiency 6. Pericarditis. 7. Sudden death. 8. Cardiac arrhythmias. Acute Atrial Fibrillation |
| 2- Hematologic | { | <ul style="list-style-type: none"> 1. Thrombocytopenia. 2. Thrombocytosis. 3. Leukopenia. 4. Leukocytosis. |
| 3- Nephrologic | { | <ul style="list-style-type: none"> 1. Acute and chronic kidney insufficiency. 2. Temporary kidney damage (vasculitis) (<u>A well known and reported disease</u>). |
| 4- Neurologic | { | <ul style="list-style-type: none"> 1. Stroke (usually ischemic). 2. Encephalitis. 3. Neuritis. 4. Guillain Barré. 5. Encephalomyelitis 6. Narcolepsy |

well-known reported diseases.

- 5- Ophthalmologic { Decrease in vision.
- 6- Auditory { Hearing loss.
- 7- Smell trouble { Smell loss.
- 8- Dermatologic {
 1. Atopic dermatitis.
 2. Pigmented purpuric dermatitis.
 3. Red Lichen Planus (Confirmed by biopsy).
- 9- Arterial {
 1. Possible arterial hypertension.
 2. Possible arteritis with endarteritis or vasculitis.
 3. Possible thrombosis – embolism.
- 10 - Psychiatric {
 1- Depression due to a medical condition.
 • Sadness.
 • Anguish.
 • Tears.
 • Lack of interest.
 • Sleep alterations.
 2- Anxiety: as a reaction to uncertainty from a disease that is unexplained and threatens life.
 • Worry.
 • Uncertainty.
 • Nightmares.
- 11 - Gynecologic { Possible inflammation of the endometrium with or without metrorrhagia.
- 12- Obstetric { Fetal death, abortion, hand agenesis and polyhydramnios.
- 13- Endocrinologic { Type II diabetes
- 14- Other conditions not described yet.

Medical Observations

Obstetrics complications - fetal death and abortion- can happen in the first, second and third month of pregnancy, 15 days or more after the vaccine has been given to the pregnant woman. Also, if the Prolonged Influenza is more severe in the second month of pregnancy (5th or 6th week approx.) and if a lower intensity flu goes on, hand agenesis, polyhydramnios and fetal death have happened to women who are 6 months pregnant.

8. MEDICAL CONSEQUENCES

There are consequences :

- 1.** In the respiratory system
- 2.** Out of the respiratory system

1 - In the respiratory system

1. Chronic rhinitis
2. Little chronic nasal discharge, which is white or grayish, thick and very sticky.
3. Dryness in the upper respiratory tract.
4. Chronic sinusitis.
5. Chronic laryngitis.
6. Changes in the voice, variations in tone and timbre.
7. Chronic cough.
8. Chronic expectoration, white or grey mucus secretion, thick and very sticky, which the patient has never suffered before. Every year, especially in autumn, winter and spring, for several years.
9. Repetitive bronchitis. Every year, especially in autumn, winter and spring. The patient has never suffered it before.
10. Repetitive pneumonia during the same year or in the following year or years, especially in autumn, winter and spring.
It may be primary viral, mixed viral and bacterial or secondary pneumonia. The patient has never suffered it before.
11. Pachipleuritis
12. Viral respiratory conditions never suffered before, that appear a year after the patient is given the vaccine, several times during the following years, especially in autumn, winter and spring.
13. Other consequences not described yet.

2 - Out of the respiratory system:

- 1) Cardiologic
 1. Consequences of the myocardial infarction.
 2. Conduction system. Bradycardia. (with a definitive pacemaker). First Degree AV Block. Third Degree AV Block (complete).
 3. Consequences in the heart valves. Aortic valve disease.
 4. Myocardial alterations.
 5. Cardiac insufficiency.
- 2) Nephrologic consequences. Chronic kidney insufficiency.
- 3) Neurologic consequences: consequences of a cerebrovascular accident.
- 4) Ophthalmologic consequences: Diminished eyesight.
- 5) Auditory consequences: Diminished hearing.
- 6) Olfactory consequences: Diminished smell.
- 7) Arterial consequences: Possible arterial hypertension.
- 8) Dermatologic consequences: Red Lichen Planus. Confirmed by biopsy.
- 9) Endocrinologic consequences: Type II diabetes
- 10) Other consequences not described yet.

9. DIAGNOSIS

The diagnosis is based on an infectious condition that is acute, viral, in the respiratory system, prolonged and with several relapses, after the anti influenza vaccine is received. This condition is clinically diagnosed as influenza.

There is often a seven-day incubation period, but it can vary from a few hours (five to twenty-four hours) up to seven days or up to fifteen days, and less frequently thirty, sixty, ninety days or more.

There is very little fever, 38 degrees or less, and less frequently more than 38 degrees.

The clinical manifestation of the first symptoms can vary and affect different systems.

- 1- The onset of the disease can be abrupt or slow and progressive as days go by. It will be fully developed seven or fifteen days after the symptoms appear. It can be diagnosed as a prolonged respiratory viral disease called prolonged influenza.
- 2- It can affect the lungs directly with a respiratory insufficiency which is acute and progressive. It can become severe 24 to 48 hours after the onset of the symptoms, and the patient can die.
- 3- There may be other conditions, such as sudden cardiac arrest, myocardial Acute Infarction or unstable angina. They can be the first symptoms or associated to a respiratory condition or with other already described diseases.

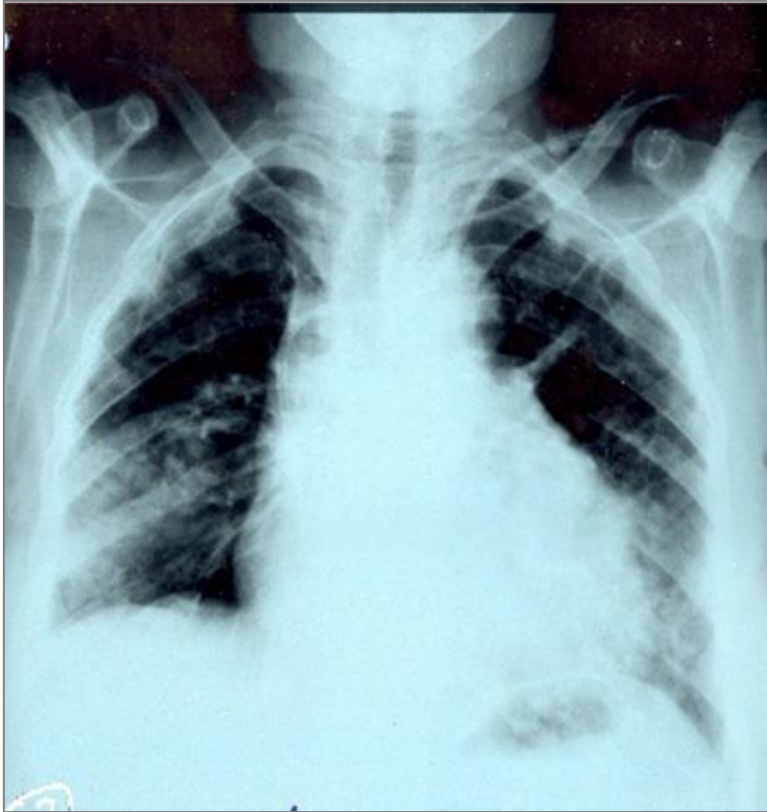Complementary methods:

1. Chest x-rays (front view):

- 1) Enlarged bronchial-vascular tree.
- 2) Enlargement of the perihilar bronchial vascular tree.
- 3) Diffuse interstitial-alveolar infiltrates – unilateral or bilateral – involving predominantly the lower lung fields and later, the middle fields.
- 4) Primary viral pneumonias, with diffuse interstitial infiltrates, without definite borders, a faint image, sometimes not very visible, unilateral and bilateral, involving predominantly the lower lung fields and later, the middle fields.(See chest x-rays in cases of primary viral bilateral pneumonias).

CASE OF PRIMARY VIRAL BILATERAL PNEUMONIA

Prolonged influenza complicated with primary viral bilateral pneumonia, with an acute myocardial infarction and acute and chronic kidney disease.



VIRAL BILATERAL PNEUMONIA: Note bilateral interstitial and alveolar infiltrates involving predominantly the lower lung fields and partly the mid-lower lung fields. Fibrotic sequelar marking in upper third left hemithorax. There is a catheter (double light) in the left subclavian vein (October 2006).

Prolonged influenza complicated with viral bilateral pneumonia and with an acute myocardial infarction.

A 70-year-old female patient, had prolonged influenza diagnosed in May 2006. She suffered it for 5 months, presenting with 4 successive relapses. In the last month, September, she developed pneumonia. She was treated with antibiotics for 7 days but she was not cured. She was treated again with antibiotics for 7 days but she was not cured again.

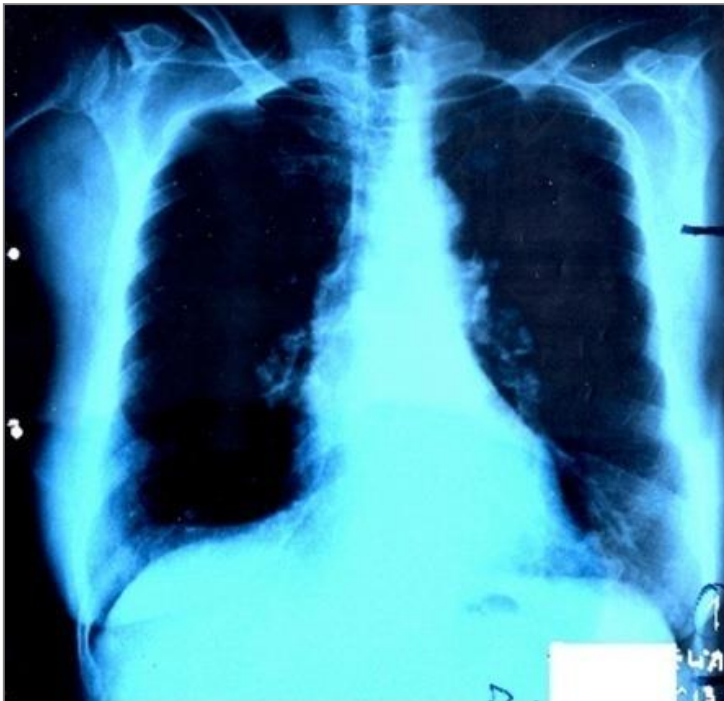
She was hospitalised in October 2006, being diagnosed with viral bilateral pneumonia. She was treated with antibiotics for six weeks, in three sessions of 15 days each and three different antibiotics, without a clear clinical and pulmonary improvement.

The patient needed 5 different antibiotic schemes in two months of pneumonia, but she was not cured, neither did her condition improve thoroughly.

She presented with an acute kidney failure when she was admitted at the hospital, which needed dialysis. Later she had an acute myocardial

infarction. She was not treated with Oseltamivir. Her relatives asked for a voluntary discharge and she was medicated with Oseltamivir, one capsule every 12 hours on the first day and later one capsule daily for 9 more days. There was an 80% improvement on the third day. The persistent pneumonia was cured without antibiotics and her kidney condition improved a little, having no other cardiac complications. She went on with a plan of 3 dialysis a week. She had no respiratory nor cardiac symptoms. After 2 months and a half in a stable condition, she presented with a staphylococcus aureus sepsis through the dialysis cannula and she died a few days later. (unused arteriovenous fistula)

CASE OF PRIMARY VIRAL BILATERAL PNEUMONIA

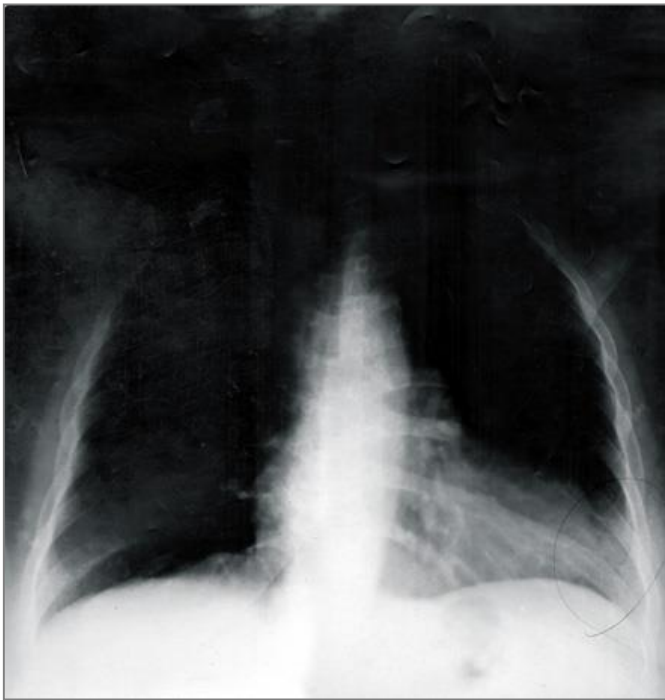


VIRAL BILATERAL PNEUMONIA: Note interstitial and alveolar infiltrates involving both lower lung fields, predominantly the left lung, and hilar congestion (July 2006)

Prolonged influenza complicated with an acute myocardial infarction and later a viral bilateral pneumonia

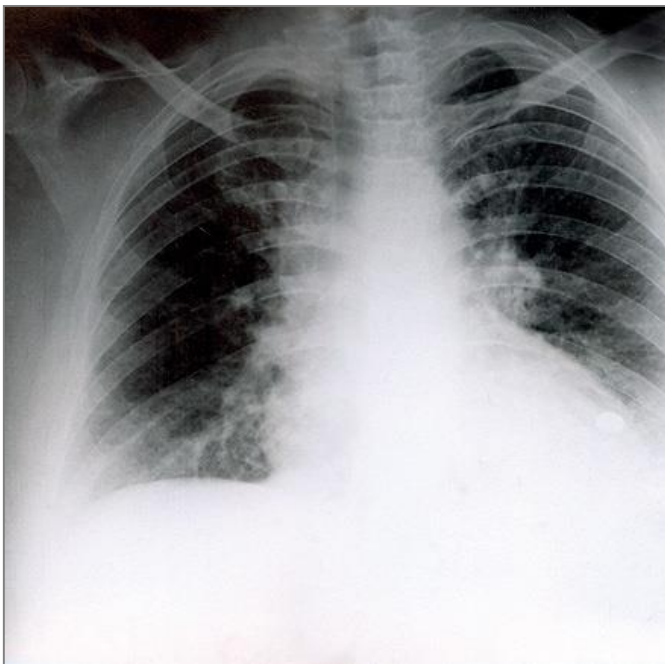
A 61-year-old female patient, had prolonged influenza diagnosed in April 2006, presenting with an acute myocardial infarction in the same month. In the following three months she had three successive relapses. In the last one, her condition complicated with a viral bilateral pneumonia (July 2006).

CASE OF PRIMARY VIRAL BILATERAL PNEUMONIA



VIRAL BILATERAL PNEUMONIA:

Note interstitial and alveolar infiltrates involving both lower lung fields, predominantly the left lung (Hospitalization date: 5 October 2006).



VIRAL BILATERAL PNEUMONIA:

Increased interstitial alveolar infiltrates in both bases. Increase of the bronchial vascular hilar tree . The condition was worsening. (7 October 2006)

1 -Prolonged influenza complicated with viral bilateral pneumonia and with an acute myocardial infarction.

A 65-year-old female patient had prolonged influenza diagnosed in May 2006, having three successive relapses. During the last relapse, the condition complicated with a viral bilateral pneumonia. She had an acute anteroseptal myocardial infarction three days before she was hospitalised (5 October 2006). The evolving anteroseptal myocardial infarction was confirmed by physical examination, a cardiac enzymes test and an ECG. The patient was worse, her condition did not improve with a 12-day antibiotic treatment and she had another infarction. She died on October 17, 2006.

She had not been administered Oseltamivir.

5) Mixed viral and bacterial pneumonias: They share characteristics with primary viral pneumonias, but they have a typical chest x-ray image that is condensed, homogeneous, with visible and well defined limits, predominantly on lower and mid regions.

6) Secondary bacterial pneumonias: a typical image which is homogeneous, condensed, bright, visible, with definite boundaries, predominant in lower and later, mid regions.

7) Nodular images with diffuse distribution, predominant in lower and later mid zones: (generally there is an aureus staphylococcus infection or another bacterial secondary infection).

8) Pneumonitis: diffuse bilateral interstitial filtering.

2- Paranasal sinus x-ray:

Clouding or a loss of clarity in all or some of the sinuses, in different densities. Sinusitis.

3 – Laboratory:

1) Blood:

- Thrombocytopenia – Thrombocytosis – Leukopaenia – Normal white cells – leukocytosis.
- Predominant neutrophilia.
- Positive P.C.R. test, in different degrees, from (+) to (++++), mostly from (+++) to (++++), showing very intense inflammation. (semi-quantitative method).
- Increased Pancreatic enzymes – amylase and amylasuria.
- Temporary and definite hyperglycemia Type II diabetes.
- Increased enzymes. CPK, CPK mb, Troponin T, TGO, LDH, TGP.

2) Complete Urinalysis

- Proteinuria
- Microscopic hematurie
- Increased leukocytes
- Amylasuria

3) Sputum:

- 1- Positive for intense inflammation
- 2- Negative mainly for bacteria.
- 3- Positive for Streptococcus pneumoniae, Haemophilus influenzae and Staphylococcus aureus, when they follow a bronchial infection or when there is a secondary infection such as in the secondary or mixed pneumonia. Other bacteria may be present either in the sputum or in a blood culture.

4) Blood cultures:

- 1 – Negative for bacteria in most cases
- 2 – Positive for bacteria such as Streptococcus pneumoniae, Haemophilus influenzae and Staphylococcus aureus, when they follow a bronchial infection or when there is a secondary infection.

5) Blood Gas Tests: Hypoxemia in different degrees is noted in cases of moderate or severe respiratory insufficiency.

4 – Electrocardiogram

Note:

- 1- Acute myocardial infarction (See EEG cases 1 and 2)
- 2- Anteroseptal sequel (see EEG cases 3 and 4)
- 3- Myocardial ischemia (extensive anterior ischemia)
- 4- Alteration in conduction (bradycardia) First Degree AV Block. Third Degree AV Block (complete).
- 5- Cardiac arrhythmias. Tachyarrhythmias. Acute atrial Fibrillation.

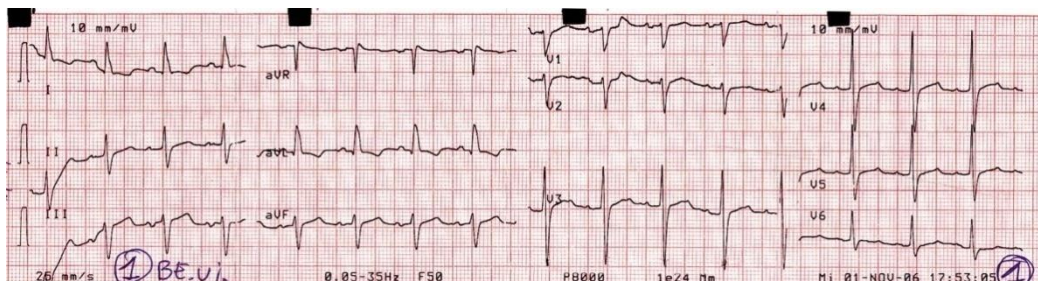
CASE N°1

A CASE OF ACUTE MYOCARDIAL INFARCTION

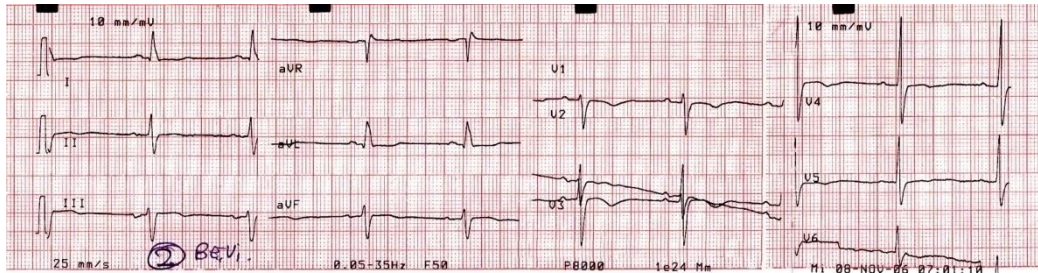
A case of prolonged influenza complicated with primary viral bilateral pneumonia and acute myocardial infarction.

A female patient was hospitalized for viral bilateral pneumonia and suffered an acute myocardial infarction and post-AMI angor.

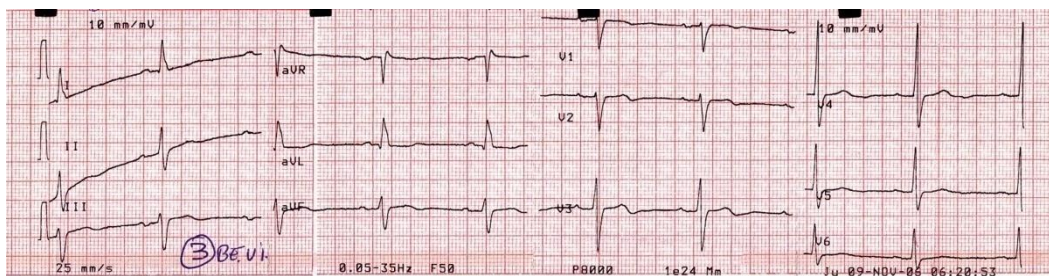
There are four successive ECGs to show the evolution.



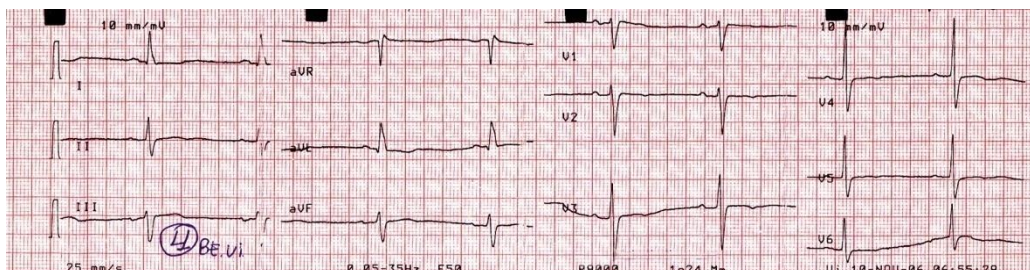
ELECTROCARDIOGRAM 1: Note an alteration in the repolarization in V₁ – V₂ – V₃ – V₄ – V₅ – V₆ leads and also in DI and AVL leads (not mapped patient) (Date 01 November 2006)



ELECTROCARDIOGRAM 2: See ischemic changes in negative T waves in V₁ – V₂ – V₃ – V₄ and rectified ST in DI and aVL. There is also an alteration in the repolarization in DII, DIII, aVF and V₅-V₆ with flat-to-negative T wave. There are AMI signs, a troponin and cardiac enzymes elevation, with a typical curve, confirming the diagnosis of AMI (mapped patient) (Date 8 November 2006)



ELECTROCARDIOGRAM 3: Note persistent ischemic changes in V₁-V₂-V₃-V₄ (mapped patient). (Date 9 November 2006)



ELECTROCARDIOGRAM 4: Note ischemic changes in V₁-V₂-V₃-V₄ and an elevation of the ST segment in V₁, showing symptoms of a persistent post-A.M.I. ischemia. (mapped patient). (Date 10 November 2006)

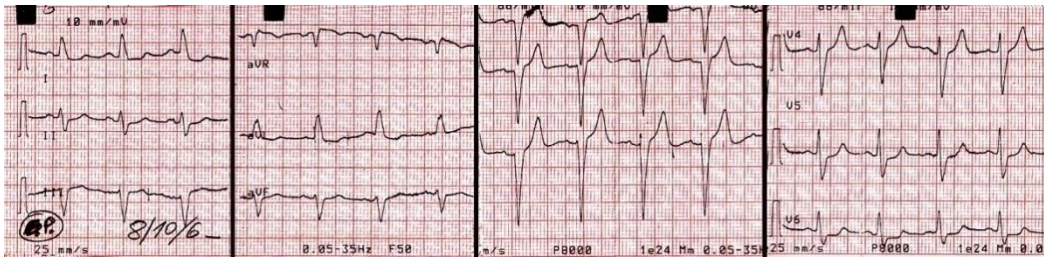
CASE N°2

A CASE OF ACUTE MYOCARDIAL INFARCTION

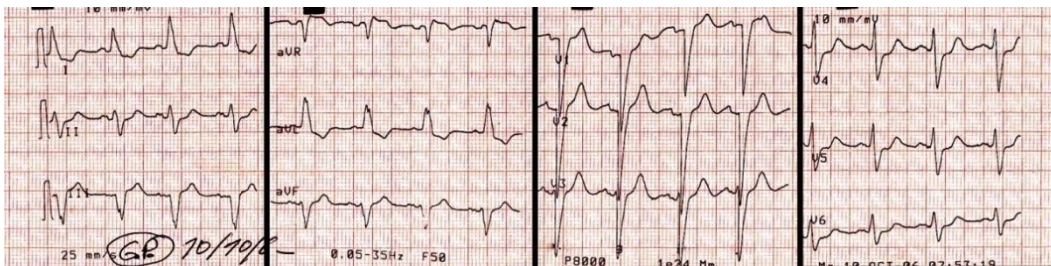
A case of prolonged influenza complicated with primary viral bilateral pneumonia and acute myocardial infarction.

A female patient with an evolving anteroseptal infarct. The electrocardiogram recorded on October 8, 2006, where the evolving A.M.I. is seen, with left ventricular overload (See electrocardiogram 1). Two days later the ST elevation was reduced and there was a possible ischemia in the anterior face (V₄) and bigger left ventricular overload (D₁ and AVL). (See electrocardiogram 2 – date 10 October 2006). Then there was another enzymatic elevation (M.I.).

The patient died 7 days after the last ECG with a new A.M.I. She had not been medicated with Oseltamivir.



ELECTROCARDIOGRAM 1: See QS with ST elevation in V₁-V₂-V₃ (the QS shows an incipient "r" in V₃) and an alteration of the repolarization in AVL. (Date 8 October 2006)



ELECTROCARDIOGRAM 2: Two days later, see a smaller ST elevation and a T-wave depression in V₁-V₂-V₃, a slight depression in V₄ and a bigger alteration of the repolarization in D₁ and AVL. (patient not mapped). (Date 10 October 2006)

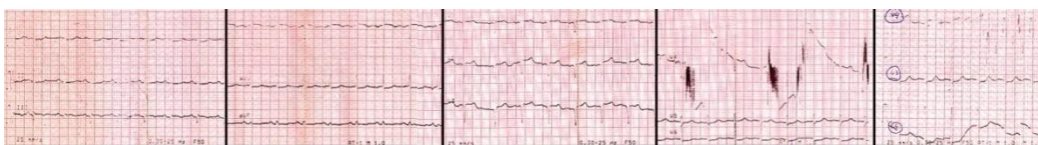CASE N°3

A CASE OF ANTEROSEPTAL SEQUEL

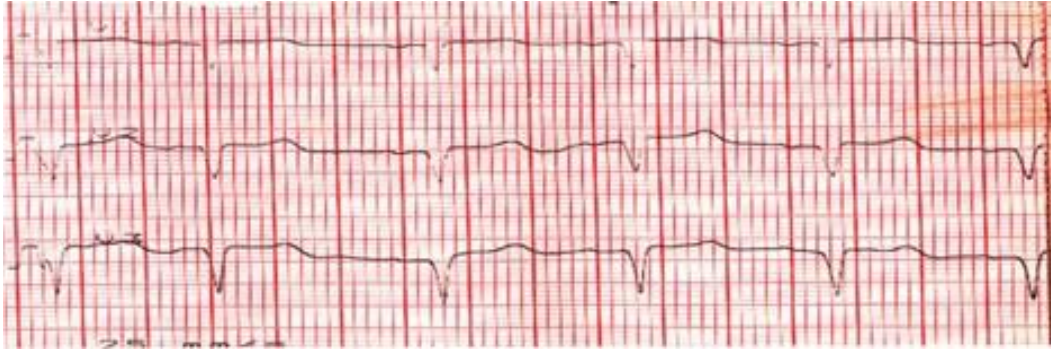A case of prolonged influenza complicated with primary viral bilateral pneumonia and acute myocardial infarction.

A female patient, 71 years old, diagnosed with prolonged influenza (April 2004). 20 days later it complicated with viral pneumonia and then M.I. during hospitalization.

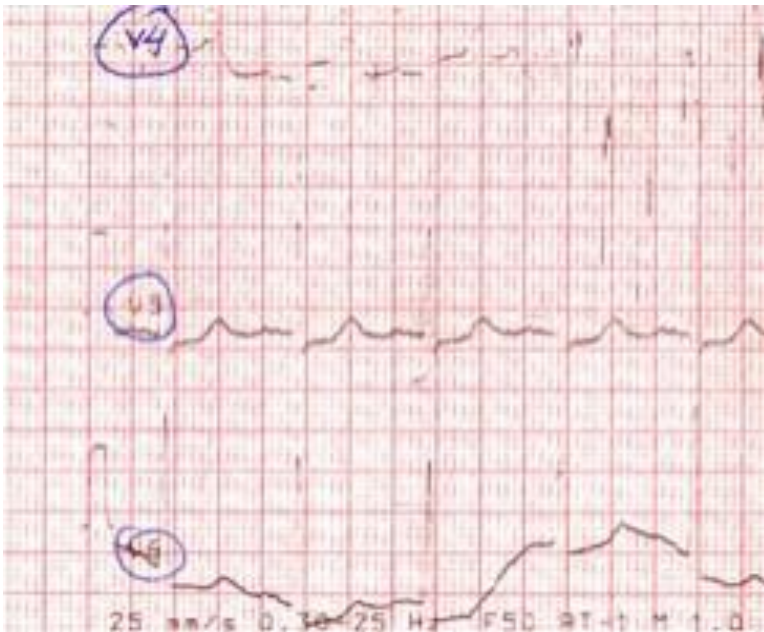In an E.C.G. performed in 2005 an anteroseptal M.I. sequel V₅-V₆ was detected. (See E.C.G. 1, 1.1 and 1.2).



E.C.G. 1: See QS with elevation in V₁-V₂-V₃-V₄ and ST depression in V₅-V₆ (Year 2005)



E.C.G. 1.1: Enlarged image of QS and elevation in V₁-V₂-V₃.



E.C.G. 1.2: Enlarged image of QS and elevation in V₄ and ST depression in V₅-V₆

CASE N°4

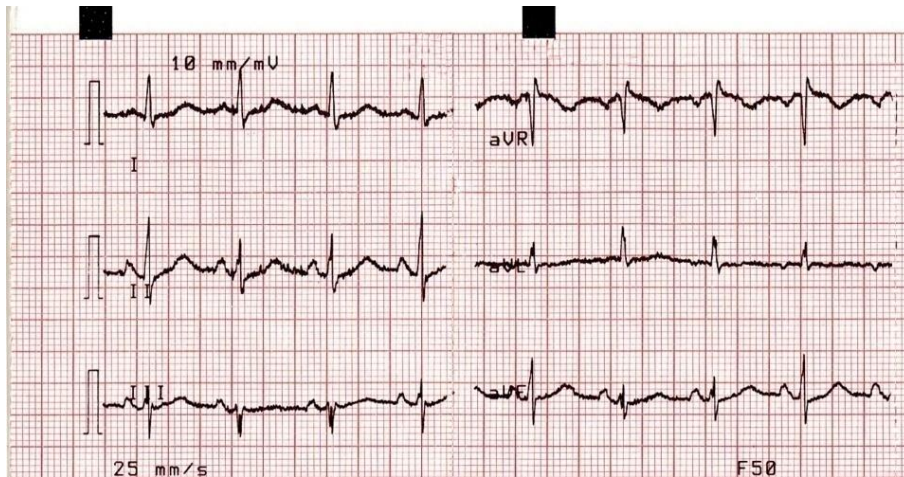
A CASE OF ANTEROSEPTAL SEQUEL

A case of prolonged influenza complicated with primary viral bilateral pneumonia and acute myocardial infarction.

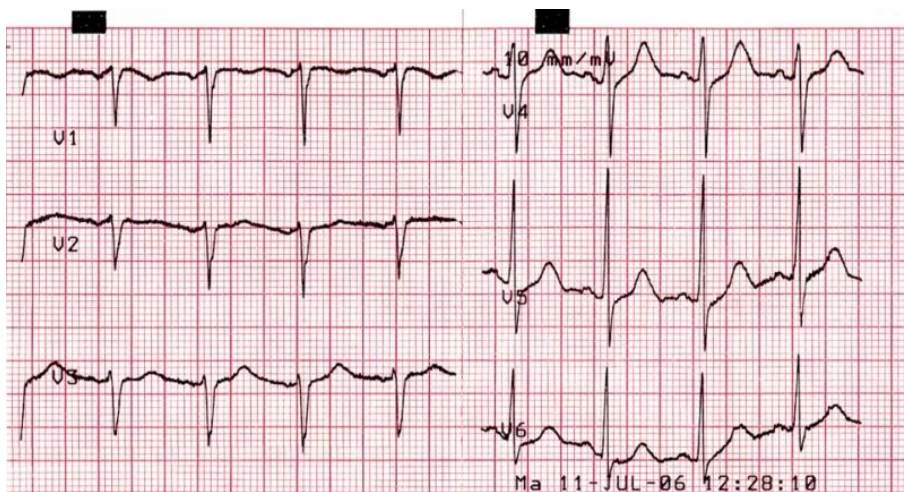
A female patient who suffered from Prolonged influenza in April 2006, had A.M.I. but did not have any E.C.G. at the moment.

This ECGs were taken when she was hospitalized due to a viral bilateral pneumonia in July 2006, where the anteroseptal sequel can be seen.

(See electrocardiogram 1).



E.C.G. 1: (July 2006)



E.C.G. 1: See the lack of progression of the R Wave in V₁-V₂-V₃.

10. DIFFERENTIAL DIAGNOSIS

It has to be differentiated from other pathologies of the respiratory system and of other systems.

The most important points are:

1. The patient was not inoculated with the influenza vaccine.
2. Retarded effect: the patient should not have been vaccinated in the past, because of its retarded effect, by which the patient can suffer it again, less seriously, with or without complications.
3. The patient should not have been close to a sick person, or lived with him/ her, who became ill after being vaccinated with the flu vaccine, for it can be transmitted to healthy people.

It has to be differentiated from other conditions:

1. Other respiratory viruses.
2. Mycoplasma and chlamydiae.
3. Other conditions that can produce a similar condition.

11. DEVELOPMENT OF THE DISEASE

The development of this disease is long, persistent and with several relapses, which last weeks, months (three in average), or more than a year. Frequently, they last three months.

It can go on for several months (four, six, nine or more), even more than a year, but less severely.

Once the condition is cured, it can reappear in the following years, mostly in autumn, winter and spring (even though the patient has not been vaccinated), and it would be a retarded effect.

The development of the disease may have the following variants:

It can be cured in seven or ten days – the shortest period.

- 1- It can be cured in a fortnight, a month or it can last more than a year.
- 2- The condition may vary from a mild respiratory one to a severe respiratory insufficiency when the patient may die in 48 hours, or some weeks (12 weeks average). There may be sudden death.

If the patient is not treated, the prognosis is very bad. There may be a lot of respiratory or non-respiratory complications which have been described, or which have not been described yet which may bring about the death of the patient.

The patient can also be cured without medical treatment or receiving a symptomatic treatment with anti-inflammatory drugs, analgesic, antipyretic, antihistamines, or others.

Only the use of Oseltamivir can improve this disease and shorten it.

The course of the disease - according to the time it takes to develop:

- 1- overacute - it begins in a few hours and lasts up to a month.
- 2- acute - it lasts up to 3 months.
- 3- Sub-acute - it lasts up to 6 months.
- 4- Chronic - it lasts more than 6 months.
- 5- Retarded effect - short, medium and long term.

12. PROGNOSIS

The prognosis is bad if the disease starts and follows its course.

25 or 27 people out of those who are vaccinated with the anti-influenza vaccine every year acquire this disease, but the percentage can reach 30 % or more.

This has happened every year since 1998 and it still happens now (2013). But from the 50s up to 1997 the rate could be the same.

The prognosis may be better only if it is well treated and the antiviral Oseltamivir is used.

The death mortality estimated by the author according to logical, clinical, epidemiological and personal reasoning, with some margin of error, is 300 deaths in one million vaccinated people.

13. TREATMENT

The effective treatment is Oseltamivir antiviral.
The treatment can be divided in four parts:

- 1) Specific: Oseltamivir antiviral**
- 2) Anti-inflammatory drugs**
- 3) Rest**
- 4) Other treatments and general measures**

Note: the treatment for grown-ups and the corresponding dose will be described below. The pediatric dose will be specified in detail.

1) Specific: treatment with Oseltamivir antiviral.

This treatment has been applied and it has proved very efficient. Each capsule of Oseltamivir has a dose of 75mg; in this way it has to be interpreted in the recommendations below.

The dose can vary from a 75 mg capsule every 12 hours at least for 5 days, to 10 or 15 days. As a starting dose, a 75 mg capsule every 8 hours for the first day is advised, continuing with a capsule every 12 hours for at least 5 days, up to 10 or 15 days.

In more serious cases, the first dose can be up to 4 capsules (one every six hours) during the first 24 hours. Then this treatment should be carried on with a capsule every eight hours during the next four days and finally with a capsule every 12 hours until a ten or fifteen-days treatment is complete. This antiviral treatment has immediate results, which are observed a few hours later after the intake of the medicine (4 to 8 hours).

This quick recovery is felt and described by the patient, and also observed and confirmed by the doctor according to the development of the disease (symptoms and signs).

In the first 24 hours after the antiviral has been administered, an optimistic and progressive development is observed. This development shows a 50% to 70% recovery which boosts in the following 48 and 72 hours when a 80% or 90% recovery is observed.

This treatment has proved to be very efficient, and its rapid and great recovery has never been seen or described before.

Depending on the complications or particular cases, the treatment can be extended to 15 days and the dose is 75mg every 12 hours as long as it shows improvement. If the patient under treatment does not get over within the first 72 hours or if the symptoms get worse or if other symptoms or signs appear, the physician must think of secondary infections or other different pathologies. Nevertheless, it is still convenient to carry on with the treatment with Oseltamivir during a reasonable period of time until the diagnosis is clear; only then the physician can decide whether or not to continue with the treatment.

In primary viral pneumonia this is the elected treatment. In primary viral pneumonia with bronchial secondary infection or in viral- bacterial mixed pneumonia, or in secondary bacterial pneumonia it is necessary to use Oseltamivir in the treatment together with antibiotics. The reason is that the viral illness produces inflammation and predisposes to bacterial secondary infections, then the *Streptococcus pneumoniae* and *Haemophilus influenzae*

predominate and the pathogenic effect of the *Staphylococcus aureus* is reinforced.

It is convenient to have blood tests and check-ups done regularly, platelet count, c-reactive protein, (C.R.P), a Prothrombin Test, CPK, TGO, LDH myocardial enzymes, amilasemia, amilasuria, a chest x-ray, and an electrocardiogram to control the progression of the disease, before and after the treatment, some days, weeks and a month later for a better control of the progression of the disease and the patient's safety.

Pediatric dose of Oseltamivir for the treatment: from 1 to 12 years old.

- Up to 15 kg: 30mg. Every 12 hours.
- From 15 kg to 23 kg: 45mg every 12 hours.
- From 23 kg to 40 kg: 60mg every 12 hours.
- More than 40 kg: 75mg every 12 hours.
- From 13 years old onwards: 75mg every 12 hours.

Other antiviral drugs, Amantadina, Rimantadina and Zanamivir, have not been used in this investigation, so no opinions as regards them will be emitted.

2) Anti-inflammatory treatment:

Anti-inflammatories: due to the important response of inflammation of the body to this disease, it is necessary to treat the problem with some kind of anti-inflammatory drugs because if the inflammation reaction is too severe, it could be counter productive for the patient.

It is advisable and it must be clear that any treatment with an anti-inflammatory drug must be carried out within the 24 or 48 hours after the treatment with Oseltamivir antivirus is started, so the latter would neutralize the virus first.

The anti-inflammatories could be:

- a) Non-steroidal
- b) Steroidal

a) Non-steroidal: it is advisable to use a 50mg-dose of Diclofenac every 12 hours or a single 75mg-dose (tablet) a day during 5 or 7 days. This would be according to the clinical manifestations and to each doctor's judgment. We understand that this treatment is aimed at light or moderate cases, though there are always exceptions.

Any other anti-inflammatory can be used if it is the doctor's decision, this could be either because of any kind of allergy, intolerance or disability in the means of administration that the patient may have or because of any underlying disease.

It is convenient to remember that this disease can produce thrombocytopenia and leukopenia and the use of any non-steroidal anti-inflammatory can adversely produce or reinforce the effects of the disease.

b) Steroidal or corticoidsteroidal: the use of Dexamethasone is advised due to its great anti-inflammatory effect (a 2ml-ampoule equals 8 mg.). It could be either parenteral, intravenous or intramuscular, in more serious cases or cases with complications, or in any pharmaceutical form.

The dose can vary, an 8ml- ampoule every four hours, every six hours, every eight hours or every twelve hours within a period of 24, 48 or 72 hours, depending on the clinical manifestations and the doctor's judgment in severe cases of respiratory failure, bronchopneumonia, bilateral or unilateral pneumonia, bronchospasm, bronchiolitis, tracheitis, laryngitis and others.

Also, if there are any other complications like cardiac ones (unstable angina, severe alteration of the cardiac conduction system, pericarditis), renal (acute renal insufficiency) neurologic (cerebral vascular accident), dermatologic (exfoliative dermatitis), and other auditive and smell alterations; also, in the case of any other pathology or complication that has not been described yet.

The dose can also be prescribed in less serious cases, for instance in cases of sinusitis, laryngitis, bronchitis and others that may require a major anti-inflammatory effect and in slight and moderate clinical cases.

It must be highlighted that older patients who suffer from other pathologies may also need corticoids due to the major seriousness of these existent complications, if the complications are related to lung, cardiac, hematologic or kidney pathologies and others.

It is important to evaluate the degree of the inflammation by doing a c-reactive protein test or a HS-CRP blood test, an E.S.R. and other biochemical methods. Thus it would be possible to get better information about the degree of inflammation and have other parameters to measure out the dose of corticoids or other anti-inflammatory drugs, and the length of the treatment.

Nowadays there are new biochemical methods that help to detect inflammation in arteries (the endothelium). This is important, because it informs about any arterial injuries, thus it marks a difference with the CRP test, which shows inflammation in general, but does not detect the specific place in the body.

It is important to detect inflammation in the endothelium since it indicates the seriousness of the case and possible immediate complications like thrombosis, embolism, ischemia, heart attacks and others. Then, an anti-inflammatory of greater strength should be used.

Intakes of one 0.5mg Dexamethasone tablet can be prescribed, or else intramuscular Dexamethasone which combines quick and prolonged action. The intakes will be the doctor's decision, according to his opinion.

Intramuscular Dexamethasone lasts from 1 to 3 weeks, its pharmacological presentation is the following: a 2ml ampoule of Dexamethasone phosphate (quick action), this equals a 4mg Dexamethasone and Dexamethasone acetate (prolonged action), which equals 16mg of Dexamethasone.

Other corticoids may be used if it is the doctor's decision, according to the patient to be treated.

In case of a complication with an acute myocardial infarction, doctors should be careful since a possible association between its usage and the left ventricular free wall rupture has been made public. Also, they must be careful in cases of acute viral myocarditis since corticoids and non-steroid anti-inflammatory drugs could make the viral myocarditis more serious. That is why it is important to clarify that in those cases, Oseltamivir antiviral has to be given first. After 48 hours, a clinical response can be

seen, and only then, the doctor can decide whether to prescribe corticoids or another anti-inflammatory drug.

It must be reminded that once the treatment with corticoids has started, it cannot be stopped abruptly. However, it could be stopped in a progressive way so as to avoid secondary corticosuprarenal insufficiency.

Also, it must be clarified that the usage of corticoids -or amount used- during the treatment is up to the doctor's judgment who will consider the convenience according to the clinical manifestations.

It is important to know that this disease can be treated without using anti-inflammatories. The results will also be good but of course, this will depend on the clinical manifestations that the patient presents.

3) Rest:

Absolute rest during 15 days. Relative rest from day 16 to day 30 or 60.

It is very important that both the antiviral treatment and rest is accomplished strictly since this disease is a viral prolonged one. Hence, it requires a longer period of healing and the rest must be longer.

This is a relevant feature of the treatment; if it is not taken into account a relapse can occur.

4) Other treatments and general measures:

1- Antihistamines: it is convenient to associate in some cases -not all cases- an antihistamine since it improves the clinical symptoms.

The good effects of this medicine are observed: Cetirizine, one tablet (10mg) a day for 5 or 7 days, no more than that.

It is possible to use another antihistamine if it is the doctor's decision and according to the patient to be treated.

2- Vitamin "C", Vitamin "A" and other vitamins and minerals:

vitamins can be used to improve epitheliums or endotheliums or just to lessen the reduction of them. Multivitamins and minerals can be used as well. This suggestion is concerned mainly to enhance nutrition, improve the affected areas and prevent other affections.

Although the use of multivitamins and minerals is arguable, it is suggested here as in the future, it could help to show scientifically its usefulness and benefits. However, facing these doubts, its indication is convenient in an associated or separate way.

With a 1 or 2gr-dose of *only* vitamin C a day, patients show subjective improvements; it is important to point out this clinical observation.

A dose of 1 and 2gr a day of vitamin C is recommended for 10 or 15 days and multivitamins and minerals, one a day for ten or 15 days as well.

Facing a prolonged disease, these should be considered food supplements. Other options are fresh orange juice or another citric juice that contains vitamin C.

3- Use and non-use of antipyretics: these are two possibilities and they can vary. It is up to the doctor to make use of them or not according to the age of the patient and the existence of other pathologies that may require this medication.

The suggestion of not using antipyretics (in a general way) is based on the fact that in the presence of a viral infection, the body defends itself by

raising its temperature (fever) and in this way it inhibits and fights the virus. Also, in this way, the body raises the number of white cells and increases defense or immunity.

As regards children, it is important to use antipyretics or physical measures like warm baths and a wet cloth in order to avoid convulsions. In the case of adults, warm baths would be enough to bring down temperature and lessen uncomfortability.

It is convenient to remember that this disease can produce thrombocytopenia and leucopenia and the use of a non-steroidal anti-inflammatory drug or an antiseptic can boost the effects of the disease as an opposite result. A suggested antipyretic is the paracetamol or another with fewer adverse effects on the blood.

If any blood alteration is detected, a new consultation with a specialist in hematology should be carried out so as to have a better diagnosis and treatment.

4- Heat overload: this treatment is based on the fact that heat would lessen viral multiplication and would neutralize the virus more quickly. In other words, heat would limit the disease.

Do as it is pointed out:

a) Lots of hot liquids, 2 or 3 litres a day. This is important for hydration. Those patients who have cardiac, kidney or other diseases, may be affected by water excess, and must be careful with this indication.

b) Hot showers or baths. The latter is best –twice or three times a day, from 5 to 10 minutes.

c) Vapour inhalation. Humidifiers with humid heat or vaporizer three or four times a day for 4 to 6 minutes. Another option is using a bowl and hot water 3 or 4 times a day.

d) Hot-water bottle: if put on the chest and trachea, this will relieve cough and chest pains that come from constant cough. This indication is a clinical observation. The information comes from research studies that show that heat has therapeutic and analgesic effects and avoids cough.

e) Overheating in bed.

e.1- Wear enough cotton clothes so as to absorb sweat.

e.2- Get covered with a couple of blankets.

e.3- Take a lot of hot liquids, $\frac{1}{2}$ to $\frac{3}{4}$ l.

e.4- Cover the whole body and head excepting the nose and mouth.

e.5- Wait for the body to sweat, which will happen about 30 minutes or an hour afterwards.

e.6- Although the heat overload can be carried on at any time of the day, it is convenient to do it during the afternoon or evening from 3 pm to 11 pm.

e.7- Once the body has perspired, it is time to take a hot shower, put on warm clothes again and go back to bed; this time with fewer covers so as not to sweat any longer but to be cozy and warm. After the sweating process has taken place, the clinical improvement is noticeable. This is an important process which has to be repeated precisely in the same way every day until it is accomplished.

There is a marked difference in the progress of those patients who get to sweat and those who do not. The first ones get over faster.

This can vary if Oseltamivir is used. The reason is because the Oseltamivir can inhibit the virus more quickly and so it would shorten the duration of the disease. That is why sweating could not occur. If there is a progressive clinical improvement, it is not necessary to induce or produce sweating.

All these indications of overheating or heat are up to the doctor's, who may prescribe it in a higher or lower degree. It may be not suitable due to other diseases or complications, that is why the doctor should be consulted.

Comments: the heat is a millennial physical therapeutic method which is not paid much attention. This indication of heat is sustained by the good results seen on patients.

It could be that heat applied on different parts of the body lessens the action of the virus, either neutralizing it or by another unknown anti-viral action.

This treatment is applied to the Common Flu and to the Prolonged Influenza by Mutation.

5- Feeding and nutrition: it is convenient to ensure good nutrition in order to restore damaged tissues and boost immunity. This is important since the period of disease is long and requires all along a good nutritional supply. It is a basic fundamental treatment necessary for the good progress and cure.

The patient's nutrition and his or her nutritional condition must be evaluated at the first interview or at the beginning of the treatment since there are several variations of nutritional conditions, not only among different patients, but also among the different diseases they may have. Hence, they require individual indications for their better progress and healing.

6- Antibiotics: if the physician decides that this disease is not more than a viral affection, it is not convenient to prescribe antibiotics because the Oseltamivir anti-virus is enough to cure the disease.

Antibiotics are prescribed when any of the following complications are diagnosed: bronchial infections, mixed viral-bacterial pneumonia, secondary pneumonia, pleural bacterial haemorrhage, bacterial pericarditis, meningoencephalitis, sinusitis, and other pathologies with secondary infections.

The predominant bacteria are:

Streptococcus pneumoniae, Haemophilus influenzae and Staphylococcus aureus.

Either the prolonged influenza or the common influenza virus boosts the pathogenic effect of the Staphylococcus aureus. In this way, the clinical manifestations are more serious, complications start to emerge and mortality increases.

The suggested specific antibiotics and the doses for these three bacteria, or others that may appear, are already known and recommended by the world's medical literature.

The treatment with antibiotics should be prescribed when necessary and when the doctor believes it is convenient, always being aware of the dose and time. Also, if any other disease exists, the practitioner may think of the need to prescribe antibiotics for prevention or prophylaxis.

7- Interconsultation: due to hematologic complications like thrombocytopenia and leucopenia, the consultation with a specialist in hematology is convenient so as to have a better diagnosis and treatment. Also, the doctor may require the consultation with a general practitioner, the Virology Laboratory, a pneumonologist, a cardiologist, an infectologist, a neurologist and others.

8- Recommendation: the use and prescription of well known drugs is suggested for a better treatment, progress and cure of the patient. Once the diagnosis is recognized, it is important to decide and carry out the treatment quickly and without delay. Otherwise, the case may get even worse and put the patient's life at risk.

We advise reading the treatment that is developed in "Prolonged Influenza by Mutation" the comments about **other medical decisions to "indicate" or "begin" the treatment.**

Comentary:

Other medical decisions to prescribe or start the treatment

Bear in mind that after receiving the first doses of Oseltamivir patients report very good clinical effects and improvement. These effects have sometimes been noticed 2 hours after taking the medicine. For this reason, it is a clinical and medical decision to treat the patient or test the treatment. In this way, and since a new disease is being observed, the physician will be able to see how the patient improves with this treatment, or else, he will be able to distinguish it from other pathologies. It can also be considered as a diagnostic and therapeutic test and carry on with the treatment. It is advisable to continue with the treatment after the first dose, even though no results are obtained in a span of 48 hours (or more). Only then, decide whether or not to continue the treatment since there could be other pathologies that hide the patient's clinical improvement, particularly if the patient is unconscious or in bed. (Asking the patient about improvements in his or her condition during the clinical progression is very important) If there is some improvement (at least a minimum), it is advisable to carry on with the antiviral treatment. A good therapeutic result could be noticed in a few days. Due to the great benefits and little risk of adverse effects, it is also suggested to finish the treatment thoroughly. Remember that if months, one, two, three, four or more years have gone by, the disease can persist and present mild relapses or a few symptoms like asthenia, cough or others. In these cases, a treatment with Oseltamivir should also be prescribed. Extraordinary improvements have been observed: 70% in 48 hours and 90% within 5 to 10 days and then the patients were completely cured.

All that has been explained in this commentary is also valid for the

"Prolonged Influenza" or other pathologies or diseases suspected to come from any kind of flu virus. For instance: viral pneumonia, viral pericarditis, angina pectoris, acute myocardial infarction*, cardiac conduction disruption, viral myocarditis**, viral encephalitis, viral meningitis, viral meningoencephalitis, viral polyneuritis and mononeuritis, and other diseases that have not been described yet, but can be clinically diagnosed and treated in the correct way.

* In the case of an acute myocardial infarction, Oseltamivir can be used but the use of corticoids should be under surveillance. It is said that the use of corticoids is associated with the free wall left ventricular rupture.

** In the case of viral myocarditis it is definitely advisable to use Oseltamivir. However, if any steroidal or non-steroidal anti inflammatories are added to the treatment, the myocarditis can worsen. In this case, it is convenient to start the treatment with Oseltamivir and check the clinical response within 48 or 72 hours. Only then apply an anti inflammatory, but all depends on the seriousness of the clinical case, its clinical presentation and other clinical variables that should be evaluated. Once this has been done, any medical decision can be made.

Commentary: In most cases, all of the above described about the "Prolonged Influenza" is also valid for the "Prolonged Influenza by mutation" since the latter is originated in the first oneo.

14. TRANSMISSION

This disease is contagious.

1 - A direct transmission is produced among people who live together or among those who spend too much time together.

2 - The contagion could occur through cough; when speaking, through flugge drops; sneezing, kissing or sharing cutlery. That is to say, sharing a drink from the same glass, or sharing any utensil mouth to mouth. There could be more unknown ways to transmit the disease.

3 - Once the contagion is produced, the disease evolves in the same way. It can also be developed with less intensity and duration, but it is still prolonged.

4 - Contagion to family members who live in the same house have occurred, and to relatives who live in different places, but who have close contact. (see *contagion diagrams* for 1999, 2000, 2010 and 2012)

All the diagrams of contagion and mutation correspond to real cases of people and families that got sick and transmitted the disease. They were all reported to national and international public health authorities and to other institutions.

Diagram of transmission. Year 1999

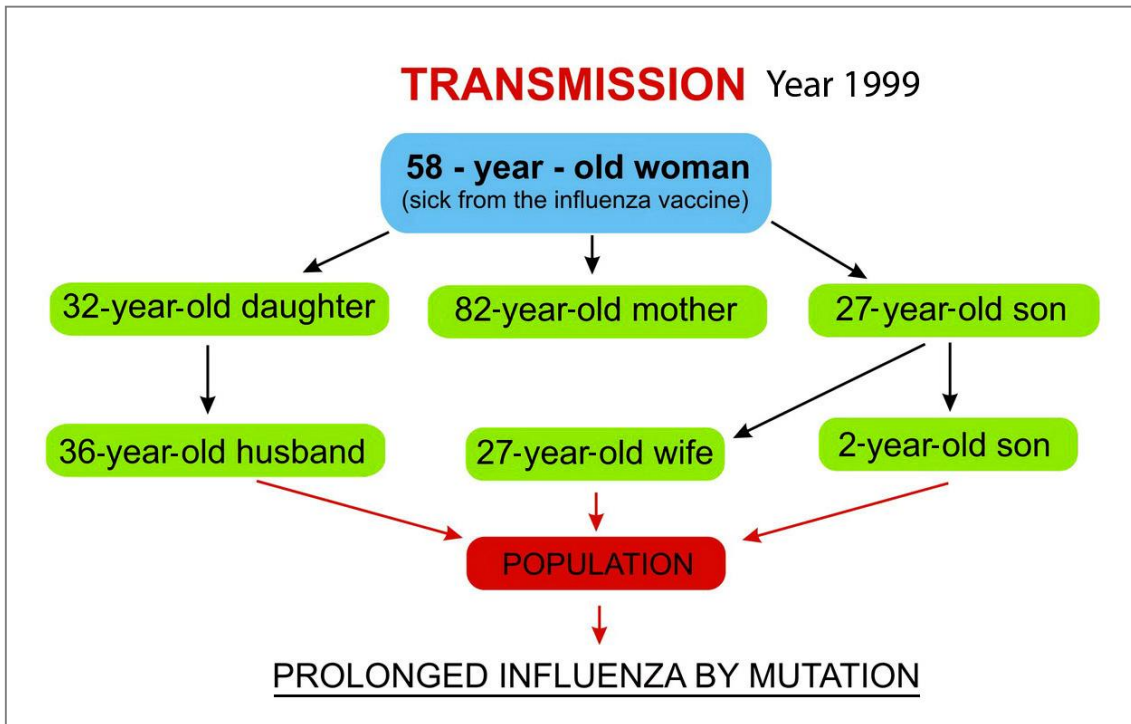


Diagram of transmission. Year 1999

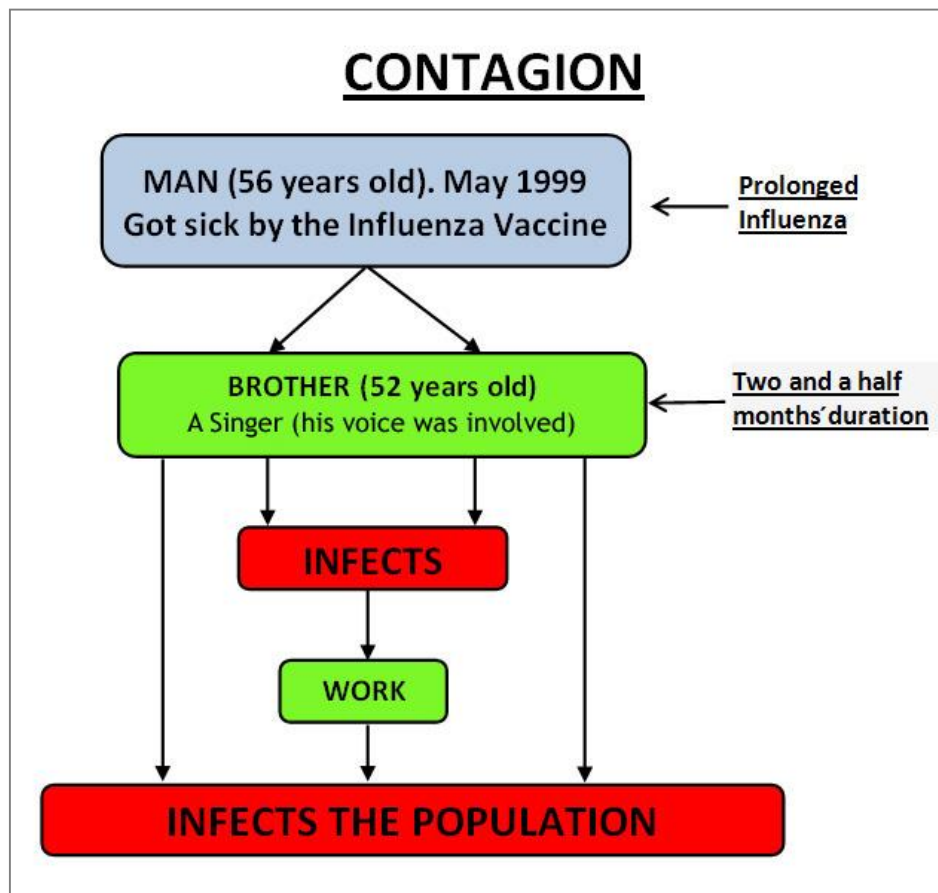


Diagram of transmission. Year 2000

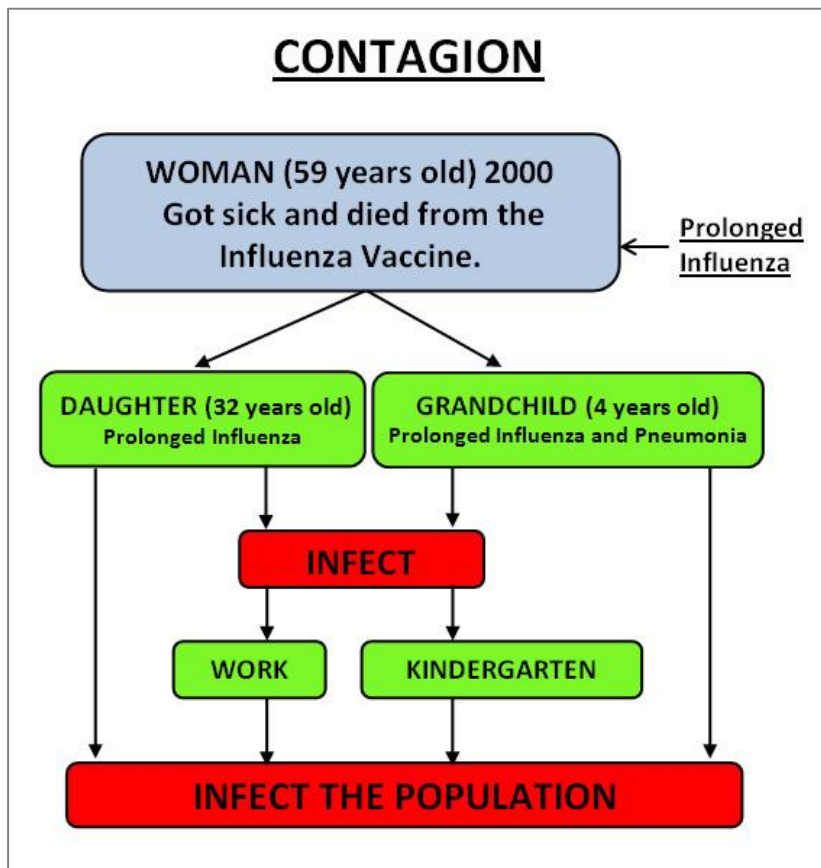


Diagram of transmission. Year 2010

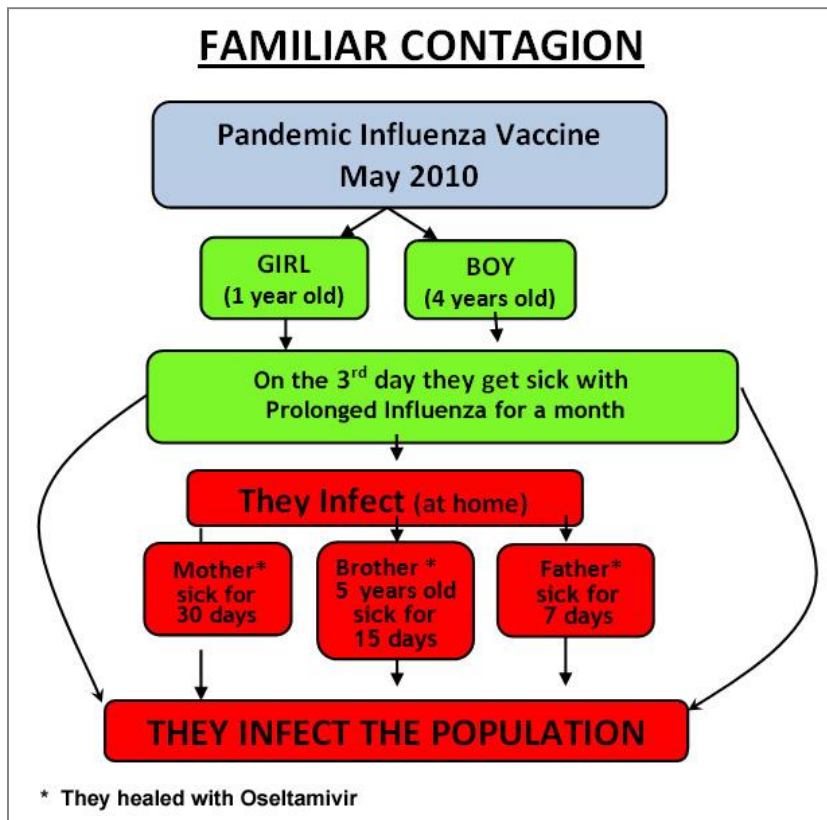


Diagram of transmission. Year 2012

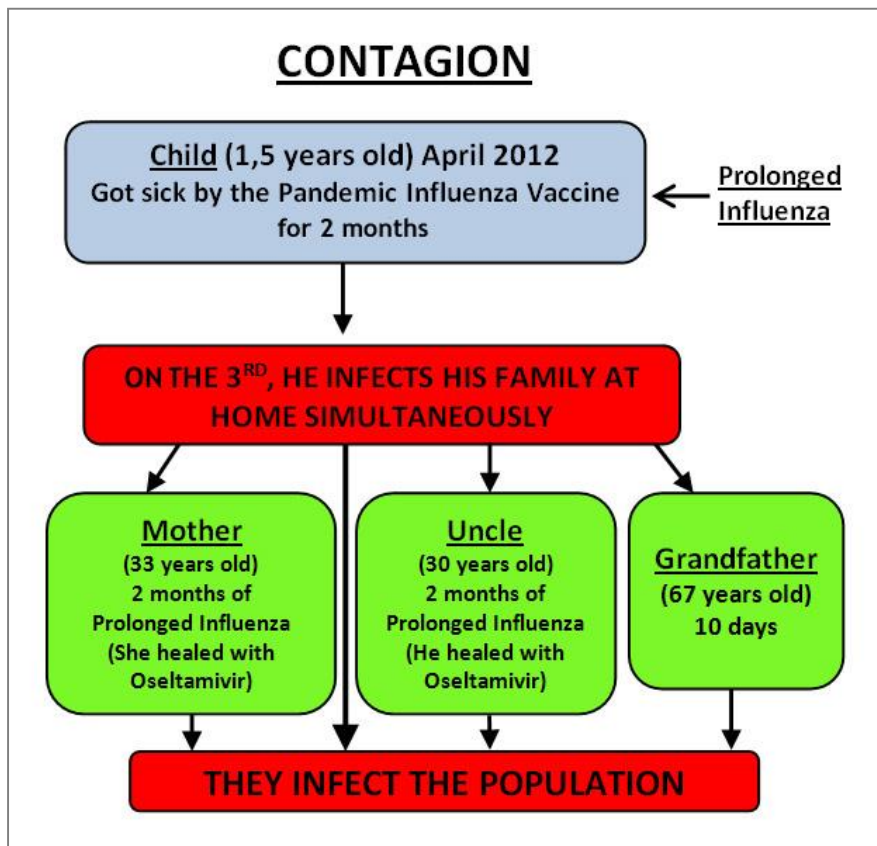
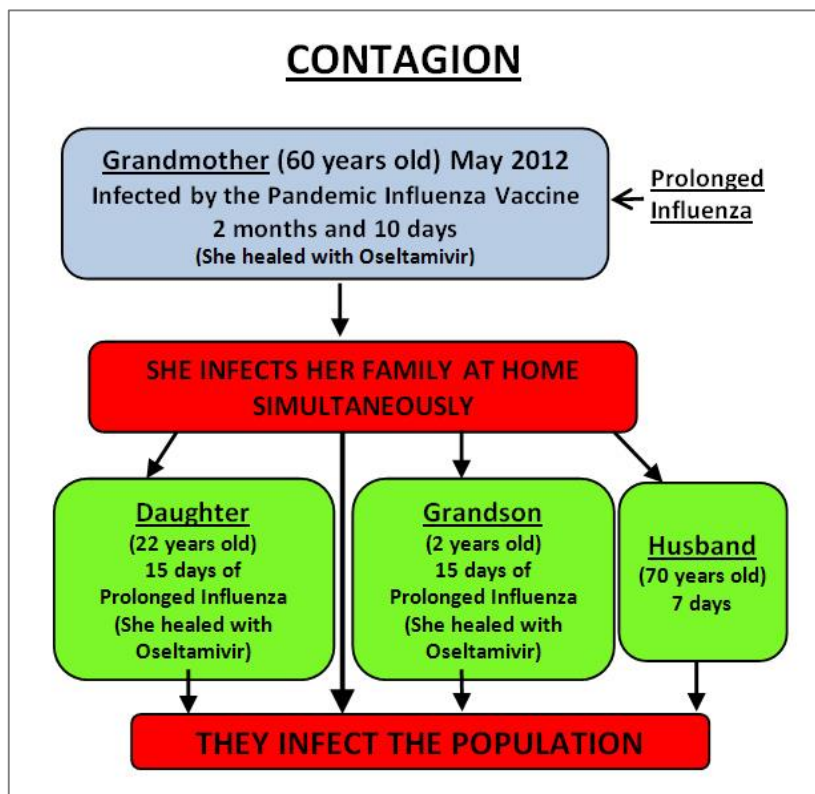


Diagram of transmission. Year 2012



There is already an influenza virus transmitted by the influenza vaccine, which is contagious. This transmission has been going on for several years. Since 2000, few cases of prolonged influenza have been observed not to have a relationship with the influenza vaccine. In 2004 and 2005, they increased 1000 % (one thousand per cent), and it continued in the period 2006-2013. This prolonged influenza has led to pulmonary and non-pulmonary complications: viral pneumonia, renal failure, acute myocardial infarction, angina pectoris, viral pericarditis, sudden death syndrome, and others.

This is causing an epidemic, since this virus of Prolonged Influenza, which is contagious, has combined and mutated with the common influenza virus, acquiring its more-contagious genetic features. This very serious fact has generated a new and more contagious virus of prolonged influenza, which is more contagious and has produced epidemics and pandemics, millions of affected people, and which is settling definitely among the population.

It is affirmed that the resulted mutation of the combined two virus is a variant, not only more contagious, but also more pathogenic.

That is to say, a mutated influenza virus, very contagious, with prolonged action, greater pathogenicity, generating another more serious variant of influenza virus, Prolonged Influenza through mutation. ([See part 1.2](#))

15. INCIDENCE AND MORTALITY

The incidence is from the 25% to 27% approximately, but it could get to 30% or more.

Of all the people that have been vaccinated, there could be 250000 or 300000 infected cases per million.

This incidence was observed from the year 1998 to 2013. It was then that the research started. However, making an inquiry among patients from years before 1998, this incidence could be observed as well. That is why it could be supposed that this has always happened after getting the influenza vaccine. From the 50's onwards people affected by the influenza vaccine have started showing up.

The mortality rate rises to 300 deaths out of one million vaccinated people. The author has calculated it in his research, basing it on clinical records, the epidemiology, and his logical and personal reasoning.

In 2013, this incidence and mortality rate have kept on rising due to the vaccination of children, pregnant and post partum women.

16. DESCRIPTION OF THE DISEASE

1- This disease, "Prolonged influenza", was described verbally in 1998 in relation with the influenza vaccine. In 1999, it was described to the authorities of Public Health Department of our nation. Finally, in 2000, it was presented to the World Health Organization. It has also been presented to the United Nations (UN), two universities of Medicine in Argentina: University of Buenos Aires (UBA) and National University of La Plata (UNLP), Argentinian Catholic Church (Archbishopric of Buenos Aires and Bishopric). The National Academy of Medicine, the Argentinian Association of

Microbiology (AAM), the Argentinian Society of Virology (SAV) and other national and international institutions from different countries.

17. SYNTHESIS OF CLINICAL CASES OF PROLONGED INFLUENZA

Five clinical cases of prolonged influenza with complications such as primary viral bilateral pneumonia together with acute myocardial infarction are presented below. One or the other complications just mentioned could appear in first or second instance.

CLINICAL CASE N°1

Prolonged influenza complicated with primary viral bilateral pneumonia and acute myocardial infarction with chronic acute renal insufficiency

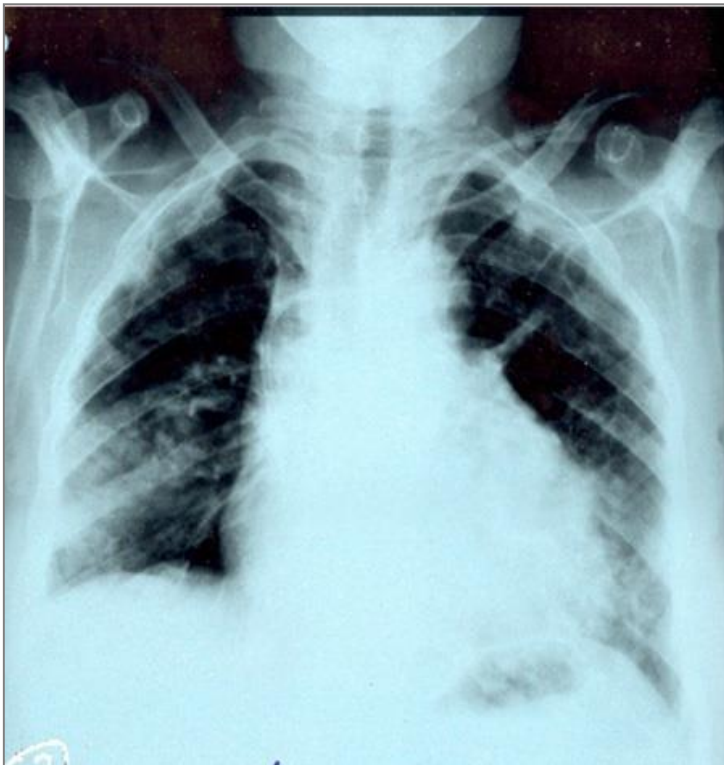

Fig 1. **Viral bilateral pneumonia:** Note bilateral interstitial and alveolar infiltrates in both lower lung fields and middle lobes. Secular fibrosis in upper third of left hemithorax. Cannula (double lumen) in left subclavian vein (October 2006).

A female patient, 70 years old, diagnosed with Prolonged Influenza in May 2006, 5 months so far, 4 successive relapses. Her influenza complicated with pneumonia on the fifth month (September). She followed a 7-day treatment with antibiotics without healing. Once more, she got a 7-day treatment with another antibiotic with no results again.

She was hospitalized in October 2006, with a diagnosis of viral bilateral pneumonia, she was treated with three different antibiotics, fifteen days

each, for one month and a half. No clinical or pulmonary improvements were seen.

In two months of persistent pneumonia, she needed five different treatments with antibiotics; nonetheless, she was not cured and she did not recover.

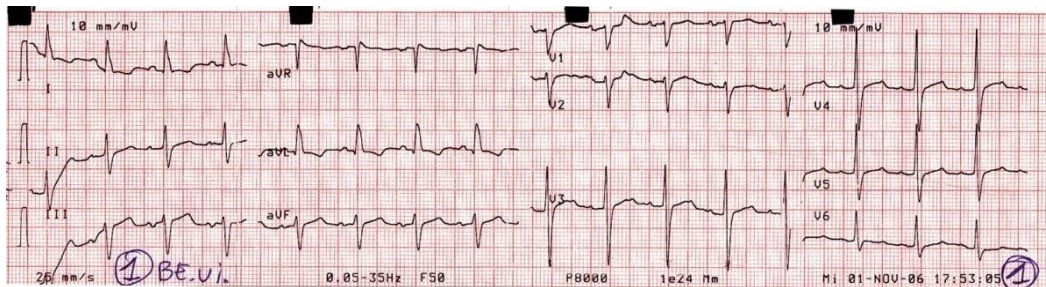
She presented with acute kidney insufficiency and for this reason she required dialysis. Afterwards, she suffered an acute myocardial infarction. The patient did not take Oseltamivir.

Her family asked for voluntary discharge and the patient started taking Oseltamivir every other 12 hours the first day and then 1 tablet daily for 9 more days. Her clinical recovery got to an 80% on the third day, her persistent pneumonia healed without antibiotics and her kidney failure got slightly better and there were no cardiac complications. She went on with dialysis three times a week without any respiratory or cardiac symptoms.

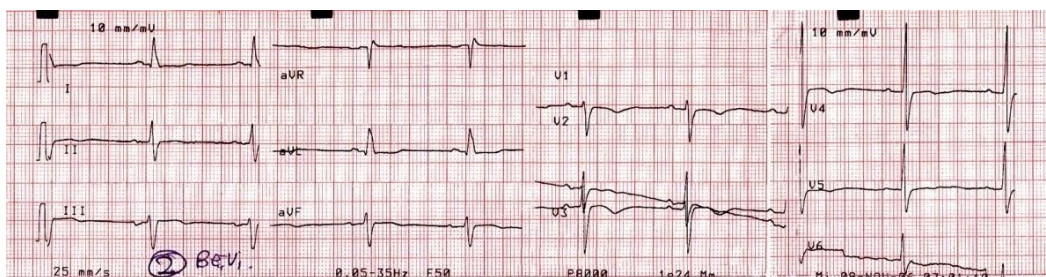
After two months and a half in a stable condition, she presented with a hemodialysis catheter-related streptococcal infection and died in a few days (unused arteriovenous fistula).

Prolonged influenza complicated with primary viral bilateral pneumonia and acute myocardial infarction

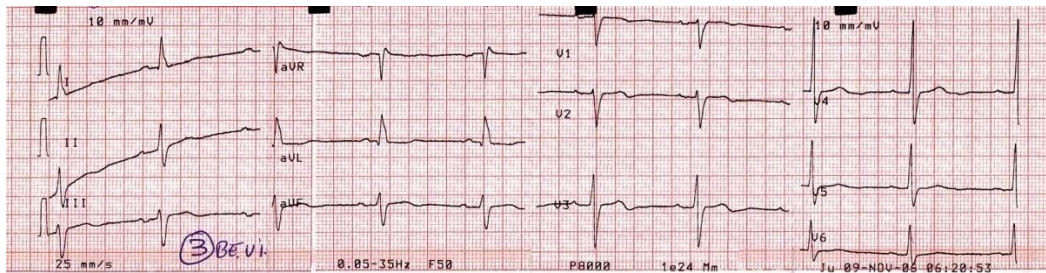
The same patient of clinical case n^o 1 and picture n^o 1, who hospitalized due to a pneumonia, suffered an acute myocardial infarction and chest pain post-A.M.I. Four successive electrocardiograms of the progression of her disease are below. (See electrocardiograms 1, 2, 3 and 4).



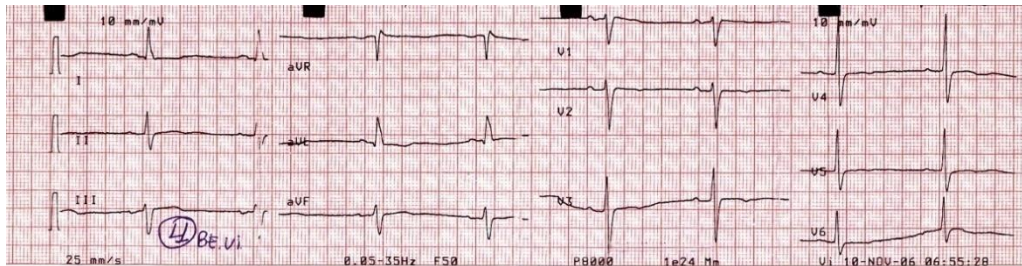
Electrocardiogram 1: alterations in the repolarization can be observed in derivations V₁ -V₂ -V₃ -V₄ -V₅ -V₆ as well as in DI and aVL. (not mapped patient) (Date 11/1st/2006)



Electrocardiogram 2: other ischemic changes can be observed in V₁ -V₂ -V₃ -V₄ negative T wave and rectified ST segment in DI and aVL. There are also alterations of the repolarization in DI, DII; in aVF and V₅ -V₆ flat to negative T waves. Here, there is a clinical acute myocardial infarction present, cardiac troponin and enzyme elevation with a typical curve. The diagnosis of A.M.I is confirmed. (Mapped patient) (Date 11/8th/ 2006)



Electrocardiogram 3: persistent ischemic changes in V₁ -V₂ -V₃ -V₄ (mapped patient) can be observed (Date 11/9th/2006)



Electrocardiogram 4: ischemic changes in V₁ -V₂ -V₃ -V₄ and a slight upsloping ST segment can be observed, clinical diagnosis of post- MI persistent ischemia (Mapped patient) (Date 11/10th/2006)

CLINICAL CASE N° 2

Prolonged influenza complicated with acute myocardial infarction and then with primary viral bilateral pneumonia.

A female patient, 61 years old. She was diagnosed with Prolonged Influenza in April 2006 with a clinical acute myocardial infarction in the same month. During the following three months, she presented with five successive relapses. In the last relapse, her state got complicated with viral bilateral pneumonia. (July 2006).

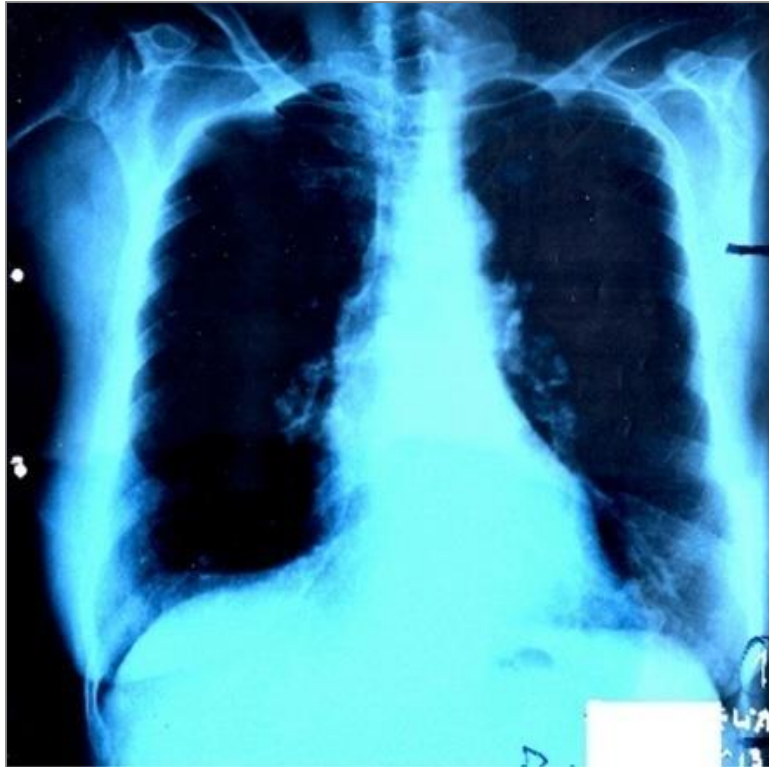
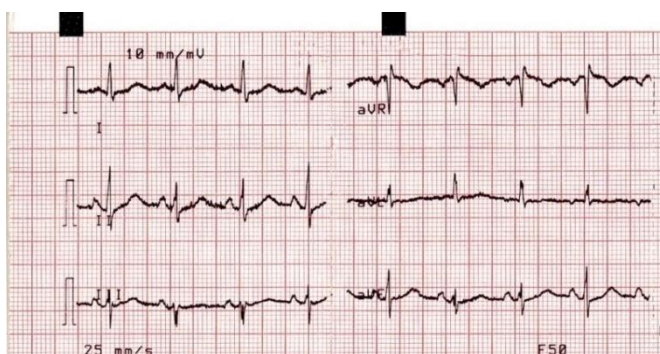


Fig n°2. VIRAL BILATERAL PNEUMONIA

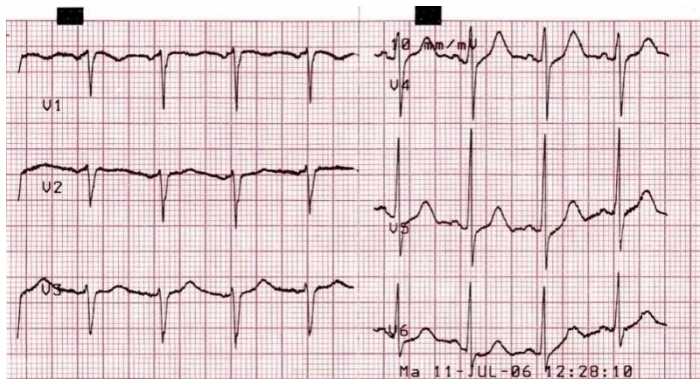
Note interstitial and alveolar infiltrates in both lower lobes affecting mainly the left side, and hilar congestion. (July 2006)

Prolonged influenza complicated with acute myocardial infarction and then with primary viral bilateral pneumonia

The same patient from the latter case, presented a clinical acute infarction during the prolonged influenza that affected her in April 2006. No electrocardiogram was kept. However, an electrocardiogram recorded in July 2006, during her hospitalization for bilateral viral pneumonia shows sequelae of anteroseptal A.M.I (See electrocardiogram 5)



Electrocardiogram 5. (July 2006)



Electrocardiogram 5. Note the lack of progression of R wave in $V_1 - V_2 - V_3$.

CLINICAL CASE 3

Prolonged influenza complicated with viral bilateral pneumonia and acute myocardial infarction

A female patient, 65 years old, with a prolonged influenza diagnosis in May 2006 and three successive relapses. During the last relapse, the influenza got complicated with viral bilateral pneumonia and an acute anteroseptal myocardial infarction three days before hospitalization (5th May 2006). The clinic, the cardiac enzymes and the electrocardiogram confirmed the AMI diagnosis (in progression). The patient did not progress well, the treatment with antibiotics for 12 days did not help her, another infarction occurred and she died on 17th October 2006.

She did not get any treatment with Oseltamivir. (See figures 3 and 4)

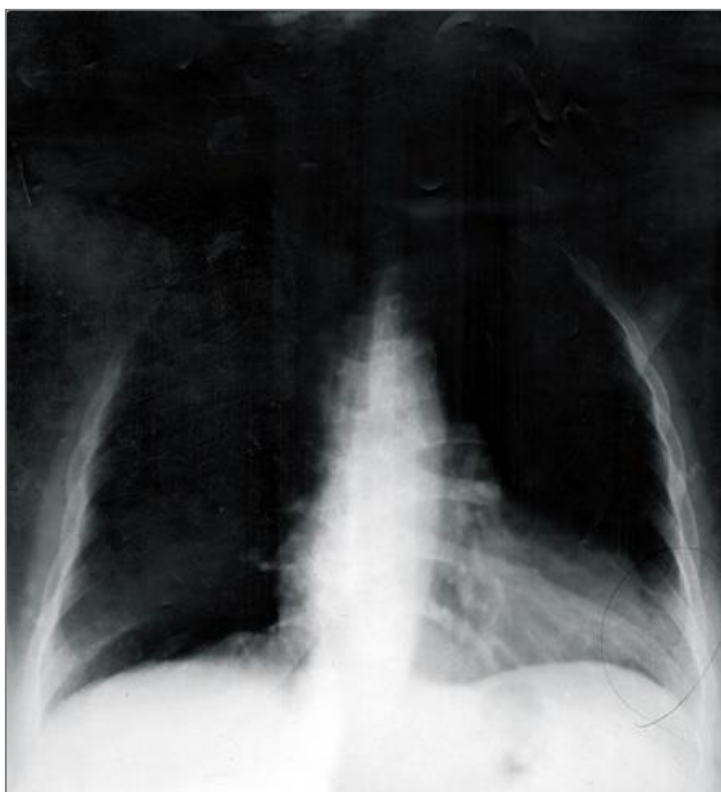


Fig. 3 VIRAL BILATERAL PNEUMONIA

Note interstitial and alveolar infiltrates in both lower lung fields, predominantly the left lung (Hospitalization date: 5th October 2006).

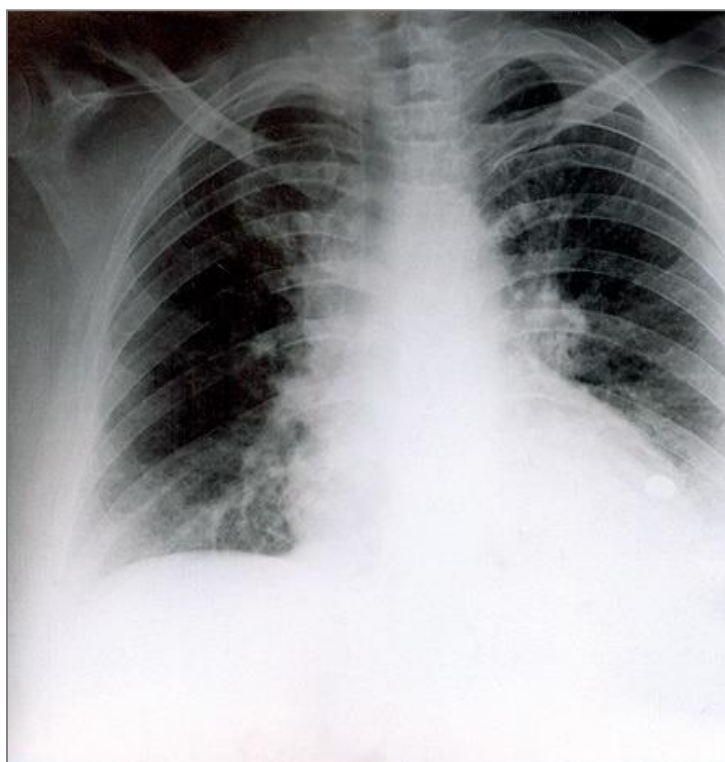
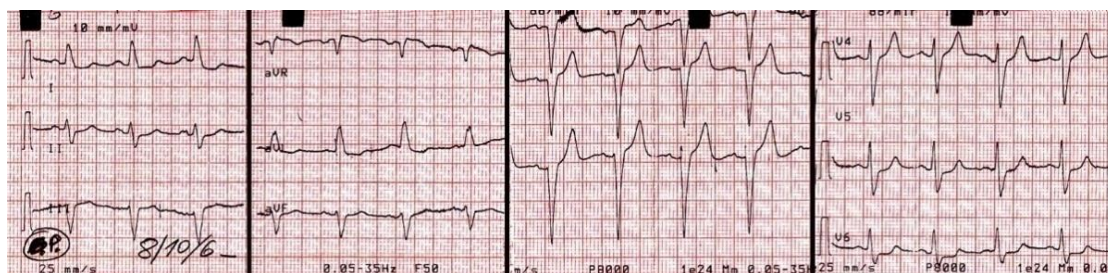


Fig. 4 VIRAL BILATERAL PNEUMONIA

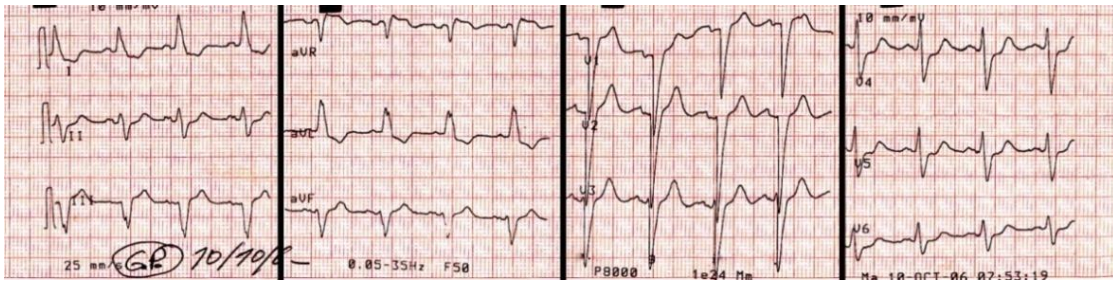
Larger interstitial and alveolar infiltrates in both lower lung fields. Brochovascular hilar increase. Clinical manifestation got worse. (Date 7th October 2006)

Prolonged influenza complicated with primary viral bilateral pneumonia and acute myocardial infarction

The same female patient from clinical case number 3 and figures 3 and 4 with an acute anteroseptal myocardial infarction. The following electrocardiogram was registered on 8th October 2006 where the A.M.I development with overload of left ventricle (see electrocardiogram 6) can be noticed. Two days later, the ST segment elevation decreased, a probable anterior ischemia appeared on V₄ and a higher left ventricular overloading (D_I and aVL). (See electrocardiogram 7 - Date: 10th October 2006). Then, another enzymatic elevation took place (A.M.I). The patient died 7 days after having the last electrocardiogram done, due to another acute myocardial infarction. She did not get any treatment with Oseltamivir.



Electrocardiogram 6: note QS with elevation of the ST in V₁ -V₂ -V₃ (the QS presents an incipient R in V₃) and alteration of the repolarization in aVL.
(Date 8th October 2006)

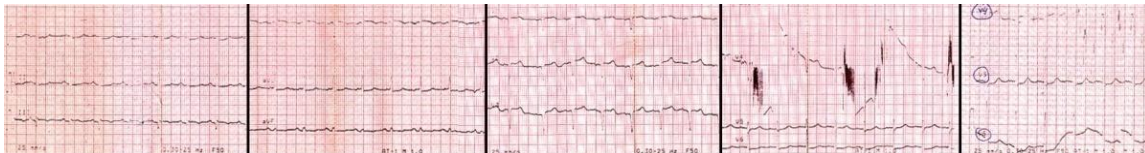

Electrocardiogram 7: note that two days later the lower ST segment elevation and the decrease of T wave in V₁ - V₂ - V₃, a slight depression in V₄ and a higher alteration in repolarization in D₁ and aVL. (not-mapped patient). (Date 10th October 2006)

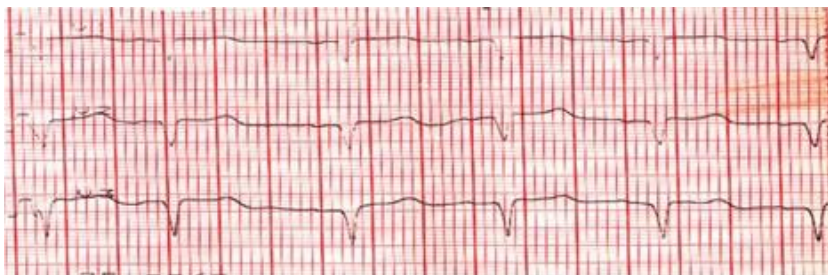CLINICAL CASE NUMBER 4

Prolonged influenza complicated with primary viral pneumonia and acute myocardial infarction

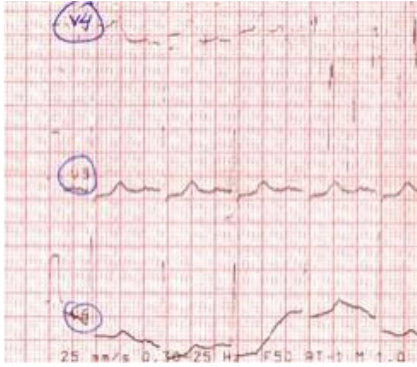71-year-old female patient with prolonged influenza diagnosis (April 2004). 20 days after her diagnosis her condition complicated with viral pneumonia and then an acute myocardial infarction during the hospitalization. In the electrocardiogram (year 2005) a sequel to an anteroseptal A.M.I in V₁ to V₄ and lateral ischemia V₅ - V₆ were detected . (See electrocardiogram 8, 8.1 and 8.2)



Electrocardiogram 8: Note QS with ST segment elevation in V₁ - V₂ - V₃ - V₄ and ST segment depression in V₅ - V₆. (year 2005)



Electrocardiogram 8.1: Enlarged picture of QS and ST elevation in V₁- V₂ -V₃.



Electrocardiogram 8.2: Enlarged picture of QS and ST segment elevation in V₄, and ST segment depression in V₅ – V₆.

CLINICAL CASE NUMBER 5

Prolonged influenza and delayed effects at medium term with primary viral bilateral pneumonia

A 74-year-old female patient vaccinated against influenza in June 2005. She presented with clinical manifestations of prolonged influenza with successive relapses. It all lasted 6 months.

In July 2006 (she had not been given the vaccine again) she presented a 45-day relapse which complicated with a viral bilateral pneumonia.

The patient decided not to have the influenza vaccine in the year 2006 due to the lung condition she had experienced the year before.

She had never had pneumonia before. (See fig. 5)

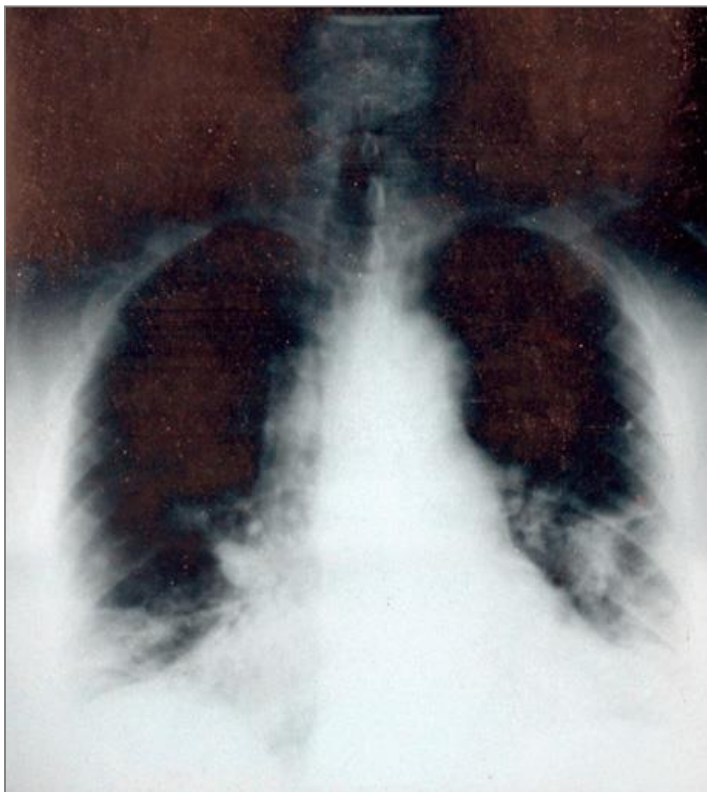


Figure 5. Viral bilateral pneumonia

Note interstitial and alveolar infiltrates in both lower lung fields, predominantly in the left lung (Date July 2006)

18. MUTATION AND FINAL SETTLEMENT OF A NEW INFLUENZA VIRUS

- **Mutation:** a new mutated virus transmitted from non-vaccinated sick people to those non-vaccinated healthy ones. "Prolonged Influenza by Mutation" takes place. This disease would last one, two or more months and if affected by the virus of the common flu, its intensity would be greater.
- **Current and final settlement of a new mutated influenza virus in Argentina and the world:** this disease had already settled in the year 2000 and developed until the year 2003. From the years 2004 and 2005 onwards a 1000% increase of "Prolonged Influenza by Mutation" was observed. It went on in the period 2006 -2013. To make matters worse it is replacing the common influenza virus.
- **Epidemic and pandemic risks through new mutations:** if a new mutation arises, more contagious or with a higher intensity of affection (greater pathogenicity), for instance the "Avian Flu", it is possible that epidemics or pandemics will occur and yield a result of millions of sick or dead people.

19. NATIONAL AND WORLDWIDE ALERT

1- Due to the seriousness of the situation as a consequence of the vaccination against flu: sick people, deaths, infections, and not to mention the mutation that may cause epidemics and pandemics, the national and world health authorities have been alerted. Also, the description of a new disease unknown until now has been released.

The aim of giving this information nationally and globally is that the relevant health authorities take action through immediate intervention and treatment of this epidemic disease. If epidemics or pandemics emerge there could be DEATHS by procrastination; lack of interest and investigation; disinformation; political, economical, strategical or other kinds of interests. In that way, irreversible damages, which in a period of time would not be possible to overcome, could be avoided.

2- The Argentine Public Health Department and A.N.M.A.T. were alerted in a direct interview and on a telephone conversation in 2008.

3- Again in 1999, the nation and the world were put on alert. In the year 2000, the World Health Organization was notified not only orally but also in black and white. It has also been presented to the United Nations (UN), two universities of Medicine in Argentina: University of Buenos Aires (UBA) and National University of La Plata (UNLP), Argentinian Catholic Church (Archbishopric of Buenos Aires and Bishopric). The National Academy of Medicine, the Argentinian Association of Microbiology (AAM), the Argentinian Society of Virology (SAV) and other national and international institutions from different countries.

4- Mutation: danger

It is serious and worrying that this virus, which is little infectious but with prolonged effect, was able to acquire the genetic features of greater transmissibility of the common flu virus. If this happened, a new mutated influenza virus with prolonged effect and very contagious would be generated. So then, epidemics and pandemics could be originated and bring about unpredictable consequences for humanity –millions of sick and deaths.

5- Observations as regards severity of the disease:

This prolonged manifestation of flu has been clinically observed from 2000 to 2013. It has continued with a greater epidemic, pandemic and endemic incidence since 2013 up to 2017. It is a prolonged viral condition that lasts 20, 30, 60 days or longer. There are subsequent relapses, less severe or the same as the already described "Prolonged Influenza". It lasts from 20 to 60 days with subsequent relapses and with same or less intensity than the one described as Prolonged Influenza.

These manifestations appear in those who have never got the influenza vaccine. So, this is an infection from the sick people who have got the influenza vaccine to the healthy ones who have not got it.

What is being described is the manifestation of the combination of the common flu virus and the prolonged influenza virus, or mutation of them. As a result, a new influenza virus together with a new clinical manifestation is obtained. Therefore, a new mutated influenza virus is generated. It is more prolonged than the common flu and its name is "Prolonged Influenza by Mutation"

A new mutated virus of the common flu has taken place and replaced the common flu virus. This medical and clinical observation was made in the year 2000, but during 2004 and 2005 there was a greater incidence, with a thousand fold increase (1,000 %) of this new clinical condition. It went on from 2006 to 2013 and continued with a greater epidemic, pandemic and endemic incidence since 2013 until now, 2017.

This is already considered as an epidemic and a pandemic - a very serious fact - which we are suffering and which have not been detected in other countries.

If another mutation took place with another virus of any kind –human flu virus, avian flu, swine flu or any other, a new virus could be created in short or medium term. What is more, this new virus could be more dangerous or even mortal, with greater pathogenicity and duration.

The worst influenza epidemics and pandemics that this flu may bring about could have as a result millions of sick and dead people.

PART I

2. "Prolonged Influenza by Mutation" - The New Influenza Epidemic -

It is a new form of influenza which lasts longer than the common one and affects the respiratory system, other organs and systems. It lasts more than 7 days, even 1, 2, 3 or more months, even several years. It presents with lots of relapses and pulmonary complications, viral pneumonias and others. It is a New Epidemic, a Pandemic which is progressively becoming Endemic. It settled in 2013, went on in 2014, 2015, 2016, 2017 and is still growing in Argentina, America and the world. It is produced by the mutation of the common influenza virus with the Prolonged Influenza virus. The result is a new clinical form of Prolonged Influenza.

New viral prolonged disease of the respiratory system, other organs and systems. It is produced by the combination of the common influenza virus with the Prolonged Influenza virus.

PROLONGED INFLUENZA BY MUTATION "Mutation of an influenza virus already settled in a community"

1. DEFINITION

It is an acute infectious disease of viral and contagious etiology. It affects the respiratory system, the respiratory pathways. **It lasts more than 7 days, even 1, 2, 3 or more months, even several years.** It is prolonged and brings along exacerbations or subsequent relapses. It generally lasts like a prolonged influenza, or less, and may give rise to complications such as sinusitis, pneumonia, acute myocardial infarction, unstable angina pectoris, pericarditis and others. It also affects other organs or systems. To make it clear, it is a prolonged influenza by mutation, generally more long-lasting than the common flu and similar in duration to the prolonged influenza.

(It is the disease that affects people who have not received the influenza vaccine and present with clinical manifestations of flu which last longer than the common influenza).

2. ETIOLOGY

It is confirmed that this disease is the product of a "mutated influenza virus". It is the result of the combination of the common influenza virus with the Prolonged Influenza virus. It presents a new clinical manifestation and it is known as "Prolonged Influenza by Mutation"

3. CLINICAL MANIFESTATIONS AND CLINICAL DIAGNOSIS

The signs and symptoms are similar to those of the prolonged influenza but with less intensity and equal or less duration; however, it is still prolonged. The whole diagnosis is the same as the already explained "prolonged influenza". Either unilateral or bilateral parotiditis has been observed as a complication also submaxillary salivary glands inflammation. They were cured very fast with the antiviral Oseltamivir.

We insist that this disease produces great inflammation in the whole respiratory system as well as in other organs and systems of the body with the same features already described;

also, the consequences produced by other mechanisms already described, and others unknown up to now.

There are other clinical manifestations and diagnosis that have not been described so far.

4. APPEARANCE OF THE DISEASE

The clinical observation was first described in the year 2000, but in the year 2004 and 2005, a report was submitted to the Public Health Ministry of Misiones and Federal Courthouse of Posadas (Misiones). Later, it was presented to the Federal Prosecutor of Posadas, Provincial Prosecutor of Posadas and Federal Prosecutor of Buenos Aires -Federal District.

In the year 2000 it was presented to the World Health Organization. It has also been presented to the United Nations (UN), two universities of Medicine in Argentina: University of Buenos Aires (UBA) and National University of La Plata (UNLP), Argentinian Catholic Church (Archbishopric of Buenos Aires and Bishopric). The National Academy of Medicine, the Argentinian Association of Microbiology (AAM), the Argentinian Society of Virology (SAV) and other national and international institutions from different countries.

This disease could have existed before the observations made in the year 2000 without being described.

5. INCREASE IN CASES

In the year 2000, there were very few cases, mainly in autumn, winter and spring. In 2004 and 2005, they increased progressively a thousand percent (1,000%), they went on from 2006 to 2013, and continued with a greater epidemic, pandemic and endemic incidence since 2013 until now, 2017. This is a very serious epidemiologic fact. Every year and in a more progressive way, there are more cases of Prolonged Influenza by Mutation. According to

clinical and epidemiological observations, the number of cases already exceeds the common flu.

This flu would be a mutation of the common influenza virus that no longer lasts 7 days, but extends from 30 to 60 days with relapses. The fact that the number of cases matches or exceeds the number of the common flu cases shows that this new disease is already settled. It also proves that there has been a mutation that is more transmissible, which explains the increasingly greater number of common flu cases.

As a consequence of the merging of the influenza vaccine virus (prolonged influenza) and the common flu virus, a mutated virus evolved. It is more infectious, more long-lasting and more intense than the common flu virus. This disease is called "Prolonged Influenza by Mutation" (see red line in Fig 1). Due to its mutation, it has acquired three main features: 1- it is more infectious. 2- it is more long-lasting with relapses. 3- it has more intensity.

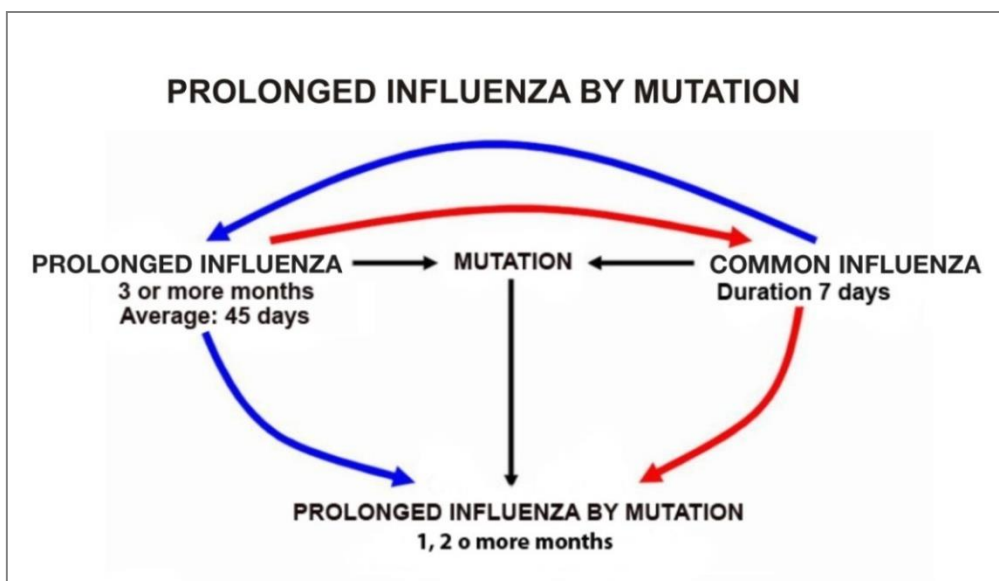


Figure 1

6. MUTATION AND NEW VIRUS

According to what has just been described, the appearance of a new mutated influenza virus can be confirmed. It is more contagious, more long-lasting and more intense, and it also has a greater impact and progression year after year.

If the situation kept growing, the common flu would be replaced by the "Prolonged Influenza by Mutation". So then, this clinical disease would change radically and would be epidemiologically settled. Sick patients who have got the influenza vaccine and have the prolonged influenza, produce the mutation. They infect healthy people who have not been vaccinated and the disease (prolonged influenza) gets reproduced with equal or less intensity. At the same time, this new sick person infects other non-vaccinated people and so on. When a person sick with this prolonged influenza infects another person sick with the common flu, the latter acts as a test tube and the mutation takes place leading to a new disease: Prolonged Influenza by mutation.

(See contagion and mutation diagram, and Fig 2 Mutation)

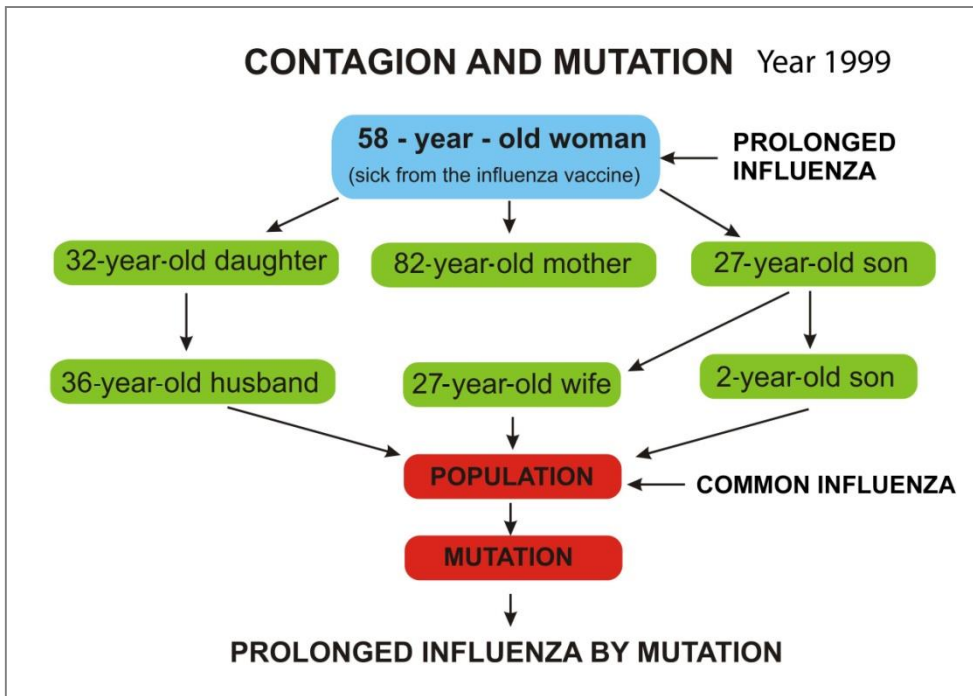


Diagram of contagion and mutation. Year 1999

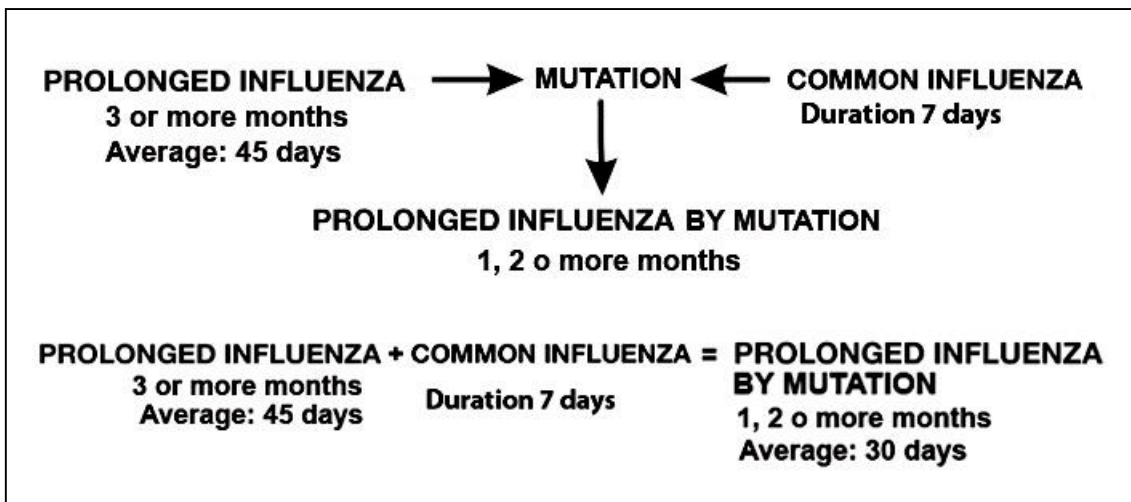


Figure 2 Mutation

All the diagrams of contagion and mutation correspond to real cases of people and families that got sick and transmitted the disease. They were all reported to national and international public health authorities and to other institutions.

In order to see the difference between the diseases that the flu virus brings on, it is advisable to see the following chart.

Comparative Chart			
	PROLONGED INFLUENZA	COMMON INFLUENZA	PROLONGED INFLUENZA BY MUTATION
CONTAGION	A little contagious ↓	Normally contagious →	Since 2004, very contagious ↑
DURATION	Prolonged duration (average: 3 months)	Normal duration (no more than 7 or 9 days)	Prolonged duration (Average: 2 months)
RELAPSES	With several relapses	With almost none	With several relapses
CLINICAL INTENSITY	Generally, very intense	Slight, moderate or intense	Moderate, intense or very intense

7. TREATMENT

Oseltamivir is the main antiviral drug in this treatment.

Quick recoveries were observed when Oseltamivir was used. After having taken this medicine, the conditions of 50% to 70% of patients improved in 24 hours; from 70% to 80%, in 48 hours; and from 80% to 90% in 72 hours. Many patients have been treated with Oseltamivir and excellent results have been obtained in a few days (7 days). (see the case—"Primary viral unilateral pneumonia")

Other treatments like the ones above (Prolonged Influenza) are valid. The level of inflammation and corticosteroids (Dexamethasone) or other anti-inflammatory treatment should be evaluated, taking into consideration the clinician's judgment to make any changes or modify the treatment if it were necessary.

Once the patient is given a diagnosis, it is important to start the treatment without delay since other complications could come up and put in risk the patient's life.

Commentary:

Other medical decisions to prescribe or start the treatment

Bear in mind that after receiving the first doses of Oseltamivir patients report very good clinical effects and improvement. These effects have sometimes been noticed 2 hours after taking the medicine. For this reason, it is a clinical and medical decision to treat the patient or test the treatment.

In this way, and since a new disease is being observed, the physician will be able to see how the patient improves with this treatment, or else, he will be able to distinguish it from other pathologies. It can also be considered as a diagnostic and therapeutic test and carry on with the treatment. It is advisable to continue with the treatment after the first dose, even though no results are obtained in a span of 48 hours (or more). Only then, decide whether or not to continue the treatment since there could be other pathologies that hide the patient's clinical improvement, particularly if the

patient is unconscious or in bed. (Asking the patient about improvements in his or her condition during the clinical progression is very important)

If there is some improvement (at least a minimum), it is advisable to carry on with the antiviral treatment. A good therapeutic result could be noticed in a few days. Due to the great benefits and little risk of adverse effects, it is also suggested to finish the treatment thoroughly.

Remember that if months, one, two, three, four or more years have gone by, the disease can persist and present mild relapses or a few symptoms like asthenia, cough or others. In these cases, a treatment with Oseltamivir should also be prescribed. Extraordinary improvements have been observed: 70% in 48 hours and 90% within 5 to 10 days and then the patients were completely cured.

All that has been explained in this commentary is also valid for the "Prolonged Influenza" or other pathologies or diseases suspected to come from any kind of flu virus. For instance: viral pneumonia, viral pericarditis, angina pectoris, acute myocardial infarction*, cardiac conduction disruption, viral myocarditis**, viral encephalitis, viral meningitis, viral meningoencephalitis, viral polyneuritis and mononeuritis, and other diseases that have not been described yet, but can be clinically diagnosed and treated in the correct way.

* In the case of an acute myocardial infarction, Oseltamivir can be used but the use of corticoids should be under surveillance. It is said that the use of corticoids is associated with the free wall left ventricular rupture.

** In the case of viral myocarditis it is definitely advisable to use Oseltamivir. However, if any steroidal or non-steroidal anti inflammatories are added to the treatment, the myocarditis can worsen.

In this case, it is convenient to start the treatment with Oseltamivir and check the clinical response within 48 or 72 hours. Only then apply an anti inflammatory, but all depends on the seriousness of the clinical case, its clinical presentation and other clinical variables that should be evaluated. Once this has been done, any medical decision can be made.

Commentary: In most cases, all of the above described about the "Prolonged Influenza" is also valid for the "Prolonged Influenza by mutation" since the latter is originated in the first one.

CASE OF PRIMARY VIRAL UNILATERAL PNEUMONIA

Prolonged Influenza by mutation complicated with primary viral pneumonia.

A male patient, 68 years old, diagnosed with Prolonged Influenza by mutation, one month evolution in September, 2006.

His condition complicated with viral pneumonia in his left lung. He was treated with Oseltamivir. Extraordinarily, he recovered clinically 70% in 24 hours and 90 % in 7 days, and completed his treatment in 15 days.

Fig 1, shows the first chest x-ray –front– at the beginning of the disease.

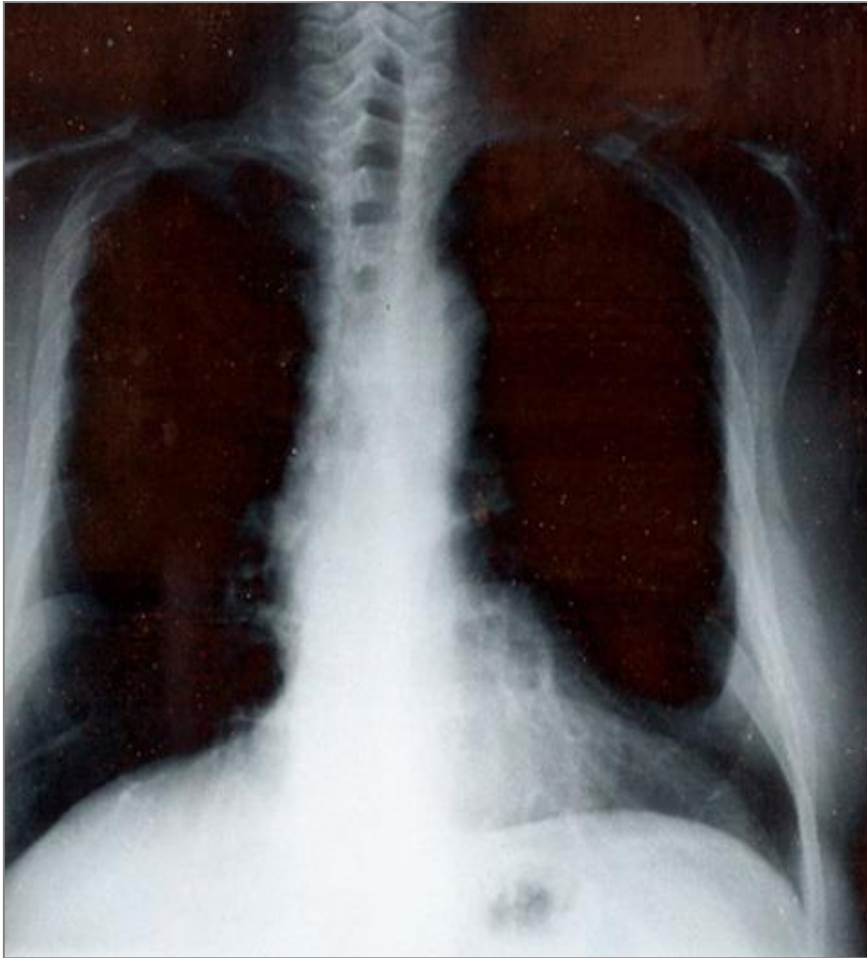


Fig 1 **VIRAL UNILATERAL PNEUMONIA**

Note interstitial and alveolar infiltrates in the left lower lung field and laminar atelectasis in the right lower lung field. (September 2006)

8. ANOTHER VARIANT OF MUTATION ACHIEVING THE SAME RESULT

The mutation that has just been explained above could happen in a different way.

The mutation was produced when the common flu virus and the prolonged influenza virus combined. A new variant of the virus was generated, as well as a new clinical manifestation. That is what is called: "Prolonged Influenza by mutation", that is, the same result was achieved. (See fig. 1, blue line)

It has settled in the population and displaced the common flu. It has caused an epidemic and it may also cause a pandemic eventually.

This variant of mutation will not be further developed.

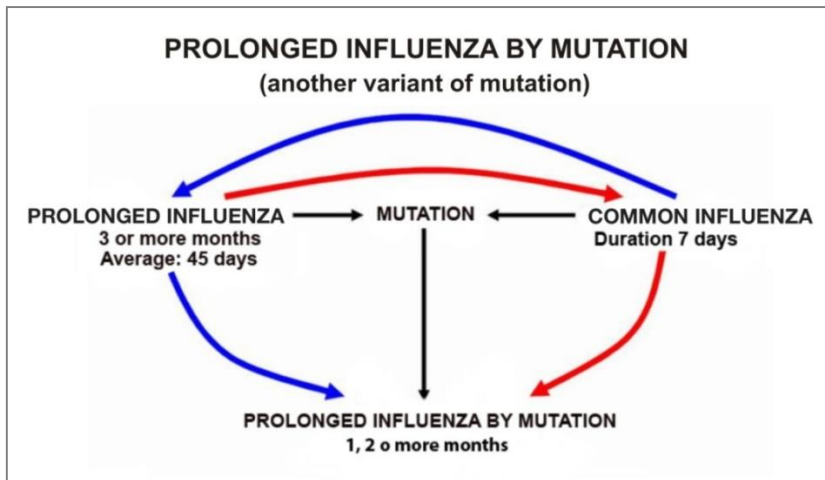


Figure 1 – PROLONGED INFLUENZA BY MUTATION (another variant of mutation)

9. POSSIBLE PROGRESSION

If successive mutations continue occurring with any other type of virus (avian or another of high pathogenicity), a flu virus, even more lethal, could be generated.

For example, the avian flu virus could mutate or merge with the prolonged influenza virus, or the prolonged influenza by mutation virus. This could lead to a new avian flu virus more long lasting and more prolonged in its clinical presentation. The disease could persist more time and it could be highly pathogenic. The fact is that then the mortality will increase seriously. It could easily be estimated that from 50% mortality rate it could rise to 80% or more.

A mutation could happen from the virus of the prolonged influenza by mutation to the avian flu one. It could have a greater infectious effect on the world population. So, it could affect a greater number of people and therefore the mortality rate would rise.

It is common knowledge that the virus of the avian flu is the one that carries more pathogenicity due to its "great clinical intensity". It has a 50% death rate.

If we add the following facts: 1) more long-lasting or prolonged, with exacerbations or relapses, and 2) more infectious, its pathogenicity would increase even more and therefore, mortality would increase as well, from 50% to 80% or more.

As a result we would have an avian influenza never seen before. This could permanently settle in the world, in a lower or greater extent.

10. EPIDEMICS AND PANDEMICS

This is a serious matter since epidemics and pandemics could have greater pathogenicity never seen before. They could bring about unpredictable consequences for the human race, and millions of sick and dead people.

PART II

Other diseases treated with Oseltamivir

Other diseases treated with Oseltamivir, with good results

Viral meningoencephalitis, with signs and symptoms of common influenza, caused by an influenza type B virus (detected in an epidemic).

Viral pericarditis, with signs and symptoms of common influenza, prolonged influenza, or prolonged influenza by mutation.

Viral pneumonia, with signs and symptoms of common influenza, prolonged influenza, or prolonged influenza by mutation.

Red Lichen Planus, with signs and symptoms of prolonged influenza.

Parotiditis, (mumps) with signs and symptoms of prolonged influenza by mutation.

Temporary kidney damage (vasculitis), with signs and symptoms of prolonged influenza.

Other diseases that can be treated with Oseltamivir

A.M.I., with signs and symptoms of common influenza, prolonged influenza, or prolonged influenza by mutation.

Angina pectoris, with signs and symptoms of common influenza, prolonged influenza, or prolonged influenza by mutation.

Heart and blood vessels disorders, with signs and symptoms of common influenza, prolonged influenza, or prolonged influenza by mutation.

Viral miocarditis, with signs and symptoms of common influenza, prolonged influenza, or prolonged influenza by mutation.

Viral encephalitis, with signs and symptoms of common influenza, prolonged influenza, or prolonged influenza by mutation.

Viral mononeuritis, with signs and symptoms of common influenza, prolonged influenza, or prolonged influenza by mutation.

Viral polyneuritis, with signs and symptoms of common influenza, prolonged influenza, or prolonged influenza by mutation.

Acute kidney failure, with signs and symptoms of prolonged influenza and prolonged influenza by mutation.

Possibly, at the onset of the chronic kidney failure, with signs and symptoms of prolonged influenza.

Other diseases not described yet.

PART III

Most frequent testimonials of patients affected by the flu vaccine, out of 1,700 interviewed patients

These are the most frequent testimonials of patients who suffered from "Prolonged Influenza" after taking the anti-flu vaccine, in the medical research with interviews over 1,700 cases in the last 17 years.

"I had never suffered from such a long-lasting respiratory disease. I was very worried about this disease that lasted 3 months. I am persuaded that the vaccine made me sick and I decided never to take the flu vaccine again".

"I never suffered from such a disease, I was very healthy when I took the vaccine. Most people who worked in the company and were vaccinated became ill. My fellow workers commented that those who did not receive the vaccine, had not become sick.

"I never had such a flu in my life, and I still have more yellow catarrh than before" (mucopurulent expectoration)

"I never had such a long-lasting cold. A friend of mine took the vaccine and she also became ill. This year (1999) my friend did not take the vaccine and did not become ill. I have made up my mind not to take it again."

"I was never ill for such a long time. I think it was the vaccine that made me sick, I would never receive it again."

" I do not want to take the vaccine again, because I relate it to the illness I suffered from. Some relatives of mine became sick in the same way when they received the anti-flu vaccine."

"It is the first time I receive the anti-flu shot and I never such long and severe flu symptoms. I suspected the vaccine. My relatives told me that the vaccine makes you sick and scolded me for taking it."

"What I suffered most, very much, was the dry hot sore throat".

"This is the first time I've had the shot, I was never sick for so long and I wouldn't take the anti-flu vaccine again"

"This is the first time I've taken the shot, I've never had such a long disease and I would never had the vaccine again. I've recommended my relatives not to have it; on some occasions I had the flu for two days at the utmost, but this flu lasted three months."

"It is the first time I've had the anti-flu vaccine, I never had asthma in April, always in September, only for 3 days. The asthma in April lasted one month, it was the longest I had in my whole life. I suspect I have to blame the vaccine for it, I would never have it again. I advise people not to have the anti-influenza vaccine."

"It is the first time I gave the vaccine to my 3-year-old son, who was healthy. We suspect the vaccine made him ill. We have decided not to give the vaccine again to our children."

"I suspected it was the vaccine that made me ill with flu. When I got the shot I was healthy. In 1997 I also had the flu after I got the shot, I had never had such a severe flu. My family also blamed the anti-flu vaccine for becoming ill."

"I almost never had flu (not longer than 3 days). It is the first time I took the vaccine. I never suffered such long flu. I am persuaded that it was the vaccine. I would never have the vaccine again. I also met some other people who became sick after having the vaccine."

"I blame the anti-flu vaccine for making me ill with such a long and severe flu. I would never take the vaccine again."

"It is the first time I've taken the shot. I never had such clinical manifestations that lasted so long and complications that I still have today. I would never have the anti-flu vaccine again."

"My husband took the vaccine in 1999 and then became ill soon. In the year 2000 he took the vaccine again and became ill with flu again, just as the previous year. Then his condition worsened and he died. I also had the vaccine with him in 1999 and 2000, and I also became ill with flu, but I was not as seriously ill as he was."

"It is the first time I had the vaccine. I've never had such a long-lasting disease. I never had flu in my life. I am sure it was the vaccine that made me ill. I decided not have the anti-flu vaccine again. I had the vaccine with all the members of my family on the same day and we all became sick. We decided not to have the anti-flu vaccine again."

" I suffered for 2 years (1999-2000) a very long and severe flu, after taking the anti-flu vaccine". I would never take the vaccine again."

"It was the fist time I had the vaccine. When I fell ill with flu I immediately thought that it was the vaccine that had made me sick. I decided not to take the vaccine again."

I almost never had flu. It was the first time I was sick for so long. I always was a healthy person. What made me ill was the vaccine. I decided not to take the vaccine again."

"I was never ill with such a long disease, I was always a healthy person. I almost never had flu. It is the second year I take the vaccine and I have the same respiratory system problems. My husband took the vaccine the same day and year (2000) I did. He had the same respiratory system problems and he died 20 days later suddenly. The doctor said it was sudden death".

"This disease was very long and I had never had it. I am persuaded that it was the vaccine what made me sick. I made up my mind not to take the vaccine again. My sister also had the vaccine and became sick."

"I had the anti-flu vaccine for 3 years and each time I was sick for quite a long time. I think it was the vaccine that made me ill. I decided not to have the anti-flu vaccine again. I had it without a doctor's prescription."

"It is the first time I had the vaccine. I was never sick for such a long time. I am suspicious about the vaccine making me sick. I've decided not to take the vaccine again."

"I always have flu after taking the anti-flu vaccine. I have never had such long bouts of flu before. My daughter and I think that this flu has something to do with the vaccine."

"It is the first time I and my family have taken the vaccine. I think it was the vaccine that made me ill. All the members of my family, who had the vaccine the same day at the same time, became ill with the same disease at the same time (5 people). The only person in the family who did not take the shot did not become ill. I have made up my mind not to have it again."

"I seldom had flu before. I have had the vaccine 5 times and always have a serious bout of flu, which I never had before."

"It is the second time I had the vaccine. The first time nothing happened to me, but this time I had severe flu after having the vaccine. It was worse than ever and I couldn't get better."

"I took it for two years and both times I had a very long-lasting severe bout of flu."

"I was vaccinated four years and each time I had a long severe bout of flu. I had never had something like that. I decided not to take the anti-flu vaccine. I know people who became ill and died after having taken the vaccine."

"It is the first time I had the vaccine. I never had such a long and severe bout of flu. I decided not to take it again because I got very sick and unhealthy. I had pneumonia. I had never had pneumonia in my life. Never in my life before taking the anti-flu vaccine have I been so sick".

"It is the first time I had the vaccine, I had a nasty bout of flu complicated with pneumonia and a stroke. Also the doctor told me that I had a pericarditis."

"I had the vaccine once a year for three times and I always had a slight touch of flu, but this year I went to hospital because it was nasty".

"I had the shot once a year for four times and every year I had a nasty touch of flu."

"It is the first time I took the shot. Never before had I had such a long bout of flu, never before had I kept sneezing so long and intensely. I had pneumonia as a complication. Never before had I had pneumonia. I decided not to have the shot again."

"It is the first time I have had the shot. Never before had I such a long and severe bout of flu. Flu lasted 3 days maximum. I was very healthy until I got the shot."

"It is the first time I got the shot. I am persuaded that the vaccine made me ill. I did not get it again and I did not get sick again."

"After having the anti-flu vaccine I had a long nasty bout of flu. My lungs were affected. Every year I have flu in autumn and winter and bronchitis, which are more severe than before. I have had this problem for 10 years since I had the shot. I decided not to take it again."

"It was the first time I had the anti-flu shot and I had severe flu. I decided not to take the vaccine again and to advise other people not to take it either."

"I don't have the anti-flu vaccine because my son told me not to take it because this vaccine makes you ill and kills you."

"I used to expect a slight touch of flu after I had the shot. I had been taking it for 10 years, every year I had the same symptoms. I haven't had it for 3 years and I have not had flu again."

"I got the shot for the first time in 2006. I had a severe bout of flu and it complicated with pneumonia. I was ill for 2 months and a half. This year, 2007, I had the vaccine again and I had a 2-month bout of flu complicated with pneumonia again. I had never in my life had the anti-flu vaccine before that time, I had never had pneumonia and such a long bout of flu."

"Comments from other patients and relatives: I think they put the flu in the vaccine, not to prevent from having it. Since I got the shot I have been ill."
"It was the first time I had the shot. I had never had flu nor a bad cold. After the shot I got flu and had to go to hospital because of it. Now I frequently have flu, I blame the vaccine for it, so I won't take it again."

PART IV

Medical Observations of Patients Affected by the Anti-Influenza Vaccine

These are the most prominent medical observations of patients affected by the anti-influenza vaccine suffering from "Prolonged Influenza".

None of the patients had suffered this disease before taking the anti-influenza vaccine.

- The patient suffered from unstable angina as a complication, which had recently begun.
- The patient belonged to a company where most workers had been given the vaccine, and more than 50% had become ill. This showed a very important epidemiologic relationship.
- The thick sticky white expectoration called for attention.
- Chronic rhinitis was a consequence.
- The patient showed different clinical manifestations of influenza, which was longer and more severe.
- The patient had sinusitis as a consequence.
- The patient had the vaccine in the state of Florida, USA. Later, she had sinusitis, which she had never suffered before.
- The patient died 30 days after taking the vaccine. He showed upper and lower respiratory tract viral infection, with progressive dyspnea. He had to be hospitalised in an intensive care unit. He had severe respiratory insufficiency and died 48 hours later.
- The patient died four months after taking the anti-flu vaccine. He had upper and lower respiratory tract viral infection that went on until he died. He had a melanoma.
- The patient died 15 days after taking the vaccine. He had viral upper and lower respiratory tract infection, with grade IV progressive dyspnea, with severe respiratory insufficiency which called for hospitalization in an intensive care unit, with mechanical respiratory assistance. He died 48 hours later. The patient had had chronic obstructive pulmonary disease (COPD), which had been under control until he took the vaccine.

- The patient had chronic bronchitis as a consequence of the vaccine.
- The patient was given the vaccine every year four times and suffered the disease each time he took it.
- It was the first time he had the anti-flu vaccine. He had a long bout of flu which lasted two months and a half for the first time. He transmitted it to his mother, his two sons, and their wives and children, transmitting the disease to healthy non-vaccinated people and these people to the general population, provoking an epidemic.
- After taking the vaccine, this patient had a viral upper and lower respiratory tract infection that lasted a year and a half, with frequent relapses and did not recover fully. Three months after she had had the vaccine, she became pregnant, but she lost the baby at six months of pregnancy. When the fetus was studied, a viral disease was recognised, which could have caused the fetal death with hand agenesis and polyhydramnios.
- The patient took the vaccine - too late- in September 1998 and the viral respiratory signs and symptoms lasted for 5 months. The patient suffered the disease even in spring and summer.
- The patient had not recovered a year after he took the anti-flu vaccine.
- This patient had previously suffered a stroke (CVA) but was stable. He had the vaccine and became ill with a viral upper and lower respiratory tract infection for three months. He died of the same infection complicated with secondary bacterial infections.
- The patient was given the vaccine without a medical prescription, prompted by her health care center and the media. She suffered from a long-lasting viral respiratory disease.
- The patient had the longest asthmatic crisis in her life, after taking the vaccine. She had a long viral respiratory disease.
- This patient took the vaccine for the second time, having a prolonged viral respiratory infection, complicated again with unstable angina, for the second time in two years (199-2000). In 2000 the unstable angina was complicated with another cardiac disease, the sinus node dysfunction, requiring a definitive pacemaker.
- The patient had moderate to severe aortic insufficiency. He took the vaccine for the first time and became sick with a prolonged respiratory viral infection. His condition worsened quickly, requiring aortic valve replacement surgery, 6 months after he had taken the vaccine.

- This patient was healthy when he took the anti-flu vaccine for the first time. 24 hours later he showed symptoms of respiratory viral infection, fever and extreme tiredness, quickly progressing from grade III to grade IV dyspnea. He was hospitalized in an intensive care unit with severe respiratory insufficiency complicated with pneumonia. He required mechanical respiratory assistance and he died 7 days later.
- A healthy 3-year-old child took the vaccine for the first time and then became ill with a lower and upper respiratory tract viral infection which lasted 3 months. His condition was complicated with bronchospasm for the first time in his life, and he was hospitalized. His parents related the vaccine to the disease and decided not to give it to him again.
- This patient was given the vaccine for the first time. She became ill with a mild long-lasting viral respiratory disease. A year later, she was given the vaccine for the second time and 12 hours later she had a prolonged upper and lower respiratory tract viral infection. 40 Days later the condition worsened with progressive grade III and grade IV dyspnea. She was hospitalised in an intensive care unit with a severe respiratory insufficiency diagnosis that required mechanical respiratory assistance. She died 48 hours later. Her husband and her son had also been given the vaccine and got sick with a prolonged respiratory viral infection.
- It was the first time the patient was given the anti-flu vaccine. He became sick with a prolonged upper and lower tract viral respiratory infection complicated with a generalized scaling disease that lasted about a month and a half.
- After being given the vaccine, the patient had a prolonged upper and lower respiratory viral infection, and showed white thick sticky nasal secretion for a long time. This characteristic is unique and they are new clinical symptoms that had never seen before. There is also less expectoration.
- The patient had a chronic cough as a consequence.
- The patient had a viral pneumonia and the expectoration was white, thick and sticky.
- The patient had a cough and dryness in her upper respiratory tract.
- A woman and her husband were given the shot on the same day. They had permanent arterial hypertension two months later. Both had had normal values in their arterial tension before taking the vaccine.
- The patient had a chronic rhinitis as a consequence, with white thick sticky secretion.
- A very healthy patient was given the anti-flu vaccine and 4 days later he became ill with a prolonged respiratory viral infection. There was a progressive dyspnea until it got to grade III. 20 days later he died suddenly at home.

- The patient took the vaccine in 1998. 36 Hours later she had a prolonged respiratory viral infection, with successive relapses during that year. The following year during the cold months she had other respiratory relapses, and she died.
- The patient had pneumonia as a complication that she had never had before.
- A 17-year-old teenager and his family got ill with the same prolonged respiratory viral infection after being given the vaccine on the same day and at the same time.
- The patient had unstable angina during the prolonged respiratory viral infection.
- The patient had pneumonia and purpuric skin lesions.
- The patient had a complication in the cardiac conduction system, the sinus node disease with extreme bradycardia.
- The patient was given the anti-flu vaccine every year for ten years and every year she had the same mild to moderate prolonged respiratory viral infection.. She was advised not to take the vaccine 4 years ago and she did not become sick with respiratory trouble any more.
- The patient had the vaccine in 2001 and then had a long-lasting respiratory viral infection. He was part of an epidemiologic and serologic research carried out by the Public Health Ministry, the P.A.M.I. , the University of Misiones and the Malbran Institute.
- The patient took the vaccine 2 years in a row. He had a long respiratory viral infection both years, and pneumonia on the first year.
- After the vaccine, the patient had a long respiratory viral infection. As a consequence, she had a chronic rhinitis with white thick sticky nasal secretion, which she had never had before. She did not take the vaccine for 4 years but she had a relapse with the same respiratory condition and viral pneumonia.
- The patient took the vaccine in 2003, and became ill with a long respiratory viral infection. In 2004 and 2005 she had viral pneumonia, which she had never suffered before and as a consequence, she had to be hospitalized.
- The patient had the vaccine in July 2005, then she became ill with a long respiratory viral infection, which was complicated with a viral pneumonia, a stroke and a viral pericarditis. Three complications together.
- The patient was given the vaccine twice on the same year. The first time she became ill with a long-lasting respiratory viral infection. The second time she had the same pulmonary condition, complicated with a severe bronchospasm that made her go to hospital with severe respiratory

insufficiency. She had been healthy before and had never had bronchospasms. She had the same illness twice after having been vaccinated twice on the same year.

- The patient had pneumonia as a complication.
- The patient took the anti-flu vaccine and had a long-lasting respiratory viral infection. 20 Days after the onset of the disease she started taking Oseltamivir - one pill every 12 hours for 5 days. She recovered 50 % 48 hours later and 90 % on the fourth day. It was extraordinary to see such a quick recovery with this medicine, not described in world medical literature yet.
- It was the first time the patient had taken the vaccine. She had a prolonged respiratory viral infection complicated with pneumonia and with consequences in the sense of smell and a 50 % hearing loss.
- The patient took the anti-flu vaccine. She had a prolonged respiratory viral infection that 4 months later was complicated with pneumonia.
- Two patients who had been given the vaccine for the first time at their workplace (a hospital) showed the same prolonged respiratory viral infection at the same time.
- The patient took the vaccine for the first time. Four days later he had mild symptoms of respiratory viral infection, his condition worsening quickly with progressive dyspnea in 24 hours. He was hospitalized in an intensive health care unit and died 48 hours later.
- The patient had systemic lupus erithematosus (S.L.E), a condition under control. After he was given the vaccine he showed a prolonged respiratory viral infection.
- The patient had the vaccine for two years, and both times she showed a prolonged respiratory viral infection with the same characteristics. On the following year she did not have the vaccine again, and in autumn she had a relapse of the same prolonged respiratory viral disease she had had the years before.
- The patient was given the vaccine in Paraguay in 2004. She became ill with a prolonged respiratory viral infection complicated by pneumonia, requiring hospitalization. She experienced an acute myocardial infarction (A.M.I). She was out of hospital but she had pneumonia twice in the following months and she had to be hospitalised again. In 2005 she was given the vaccine again and she experienced the same prolonged respiratory viral infection. There was a complication again by pneumonia and she was hospitalised. In the next months, she had bronchopneumonia and was hospitalised. She was prescribed Oseltamivir - one pill every 12 hours for 10 days. She recovered 70 % 48 hours later and 90 % on the tenth day. In the last 2 years she did not show the same condition again and she was not vaccinated either.

- After taking the vaccine, the patient had a prolonged respiratory viral infectious disease for four months. In the end, there was a complication by severe viral pneumonia.
- The patient had a complication with acute renal failure, and then, chronic renal failure.
- The patient had vision-reducing eye disease as a consequence.
- The patient showed depression because her illness was so long and physicians did not fully diagnose her disease.
- The patient showed anxiety disorders.
- The patient had laryngitis and dysphonia. He suffered from alterations in the tone and timbre of his voice, when speaking and singing.
- The patient was given the vaccine for the first time and became ill with a prolonged upper and lower respiratory tract viral infection. He transmitted his disease to his healthy brother who had not been vaccinated, who suffered from dysphonia and alterations in the tone and timbre of his voice, both to sing and to talk. This prevented him from working.
- He was given the vaccine for the first time in 2006 and it was complicated by pneumonia.
- The patient was given the vaccine for the first time in 2006 and had a long-lasting respiratory viral infection, which was complicated by viral bilateral pneumonia and an infarction. She died some days later.
- The patient was given the vaccine for the first time in 2006 and had a long-lasting respiratory viral infection, which was complicated by a two-month viral bilateral pneumonia, acute renal failure and acute myocardial infarction. As a consequence, she showed post-infarction ischemia. She had chronic renal insufficiency, then she was prescribed Oseltamivir and recovered visibly in the following days. She died two months later from a Staphylococcus aureus sepsis in hemodialysis.
- The patient was given the anti-flu vaccine in 2007. She had a long-lasting respiratory viral disease, complicated by bronchospasms, unilateral viral pneumonia, unstable angina and severe respiratory insufficiency.
- The patient was given the vaccine in 2007 and had a long respiratory viral disease, complicated by a viral bilateral pneumonia for 2 months, acute renal insufficiency, pleural effusion and pericarditis, and then he recovered. After he left hospital his chest x-ray still revealed pneumonia. He was prescribed Oseltamivir and recovered visibly.
- Some patients showed blood alterations, such as thrombocytopenia, or thrombocytosis, and leucopaenia or leucocytosis.

- A 47-year-old patient was given the vaccine in 2007 for the first time. 24 hours later she showed the first symptoms and developed a long viral respiratory condition for 15 days, with blood high pressure as a consequence (140/100). Before this episode, she was healthy and her blood pressure was 100/60 mmHg
- The patient was given the vaccine in 2007 for the first time. He had a long-lasting respiratory viral disease, complicated by viral bilateral pneumonia, pleural effusion and with acute renal insufficiency. He had pleural thickening and chronic renal insufficiency as a consequence.
- The patient was given the vaccine in Paraguay in 2008, presenting with Prolonged Influenza, and twenty days later, an acute cardiac complication. Acute myocarditis with third degree cardiac insufficiency and first degree AV cardiac blocking. His condition improved with Antiviral Oseltamivir.
- Year 2010. A 63-year-old woman was given the anti-influenza vaccine and she immediately presented with Prolonged Influenza with Red Lichen Planus - Confirmed by biopsy. (She was treated with Oseltamivir Antiviral and got better quickly 80% in seven days)
- Since 2000, after getting the anti-influenza vaccine many patients presented with prolonged influenza and a complication, such as diabetes type II, which they had never suffered before.

INDEX OF ALL CLINICAL CASES FROM THE BOOK

(Click on the title to see the case)

PARTE V

Clinical Cases of diseases treated with Oseltamivir antiviral, with good results

- **[CLINICAL CASE N° 1](#)**

[VIRAL MENINGOENCEPHALITIS WITH INFLUENZA SIGNS AND SYMPTOMS, IN A TYPE-B EPIDEMIC, CURED WITH ANTIVIRAL OSELTAMIVIR](#)

- **[CLINICAL CASE N° 2](#)**

[PRIMARY VIRAL PNEUMONIA WITH INFLUENZA SIGNS AND SYMPTOMS, SUCCESSFULLY TREATED WITH ANTIVIRAL OSELTAMIVIR. \(COMMUNITY-ACQUIRED PNEUMONIA\)](#)

PARTE VI

CLINICAL CASES OF "PROLONGED INFLUENZA"

- **[CLINICAL CASE N° 1](#)**

["PROLONGED INFLUENZA" - CURED WITH ANTIVIRAL DRUG OSELTAMIVIR, WITHOUT ANY COMPLICATIONS - \(THIS IS ONE OF THE MOST FREQUENT CASES OF PATIENTS WHO WERE AFFECTED BY THE ANTI-INFLUENZA VACCINE\)](#)

- **[CLINICAL CASE N° 2](#)**

["PROLONGED INFLUENZA" - COMPLICATED WITH PRIMARY VIRAL BILATERAL PNEUMONIA. \(PNEUMONIA CAUSED BY THE INFLUENZA VIRUS FROM THE ANTI-INFLUENZA VACCINE\).](#)

- **[CLINICAL CASE N° 3](#)**

["PROLONGED INFLUENZA", COMPLICATED WITH PRIMARY VIRAL BILATERAL PNEUMONIA WITH RENAL DISEASE AND ACUTE MYOCARDIAL INFARCTION. - THE PATIENT DIED AFTER ANOTHER ACUTE MYOCARDIAL INFARCTION \(PNEUMONIA CAUSED BY THE INFLUENZA VIRUS FROM THE ANTI-INFLUENZA VACCINE\).](#)

- **[CLINICAL CASE N° 4](#)**

[YEAR 2007. "PROLONGED INFLUENZA", COMPLICATED WITH PRIMARY VIRAL BILATERAL PNEUMONIA AND ACUTE ATRIAL FIBRILLATION - SHE HAD THE ANTI-INFLUENZA VACCINE IN 2006 AND 2007. LATER SHE HAD "PROLONGED INFLUENZA" COMPLICATED WITH PNEUMONIA BOTH TIMES \(PNEUMONIA CAUSED BY THE INFLUENZA VIRUS FROM THE ANTI-INFLUENZA VACCINE\).](#)

- **[CLINICAL CASE N° 5](#)**

["PROLONGED INFLUENZA" COMPLICATED WITH DEFINITIVE ARTERIAL HYPERTENSION - CASE HISTORY: YEAR 2007 \(OUT PATIENT\)](#)

- **[CLINICAL CASE N° 6](#)**

["PROLONGED INFLUENZA" COMPLICATED WITH VIRAL BILATERAL PNEUMONIA, ACUTE MYOCARDIAL INFARCTION, ACUTE AURICULAR FIBRILLATION, POST A.M.I ISCHEMIA, ACUTE-CHRONIC KIDNEY FAILURE. PATIENT DIED DUE TO STAPHYLOCOCCUS SEPSIS. \(PNEUMONIA CAUSED BY THE INFLUENZA VIRUS FROM THE ANTI-INFLUENZA VACCINE\)](#)

● **CLINICAL CASE N° 7**

"PROLONGED INFLUENZA" COMPLICATED WITH VIRAL BILATERAL PNEUMONIA AND ACUTE-CHRONIC RENAL FAILURE. (CONDITIONS IMPROVED WITH OSELTAMIVIR ANTIVIRAL)
(PNEUMONIA CAUSED BY THE INFLUENZA VIRUS FROM THE ANTI-INFLUENZA VACCINE)

● **CLINICAL CASE N° 8**

"PROLONGED INFLUENZA" - YEAR 2006 "PROLONGED INFLUENZA" AND MEDIUM TERM-DELAYED EFFECT COMPLICATED WITH PRIMARY VIRAL BILATERAL PNEUMONIA
(PNEUMONIA CAUSED BY THE INFLUENZA VIRUS FROM THE ANTI-INFLUENZA VACCINE)

● **CLINICAL CASE N° 9**

"PROLONGED INFLUENZA" - YEAR 2007 "PROLONGED INFLUENZA" AND MEDIUM TERM-DELAYED EFFECT COMPLICATED WITH PRIMARY VIRAL BILATERAL PNEUMONIA
(PNEUMONIA CAUSED BY THE INFLUENZA VIRUS FROM THE ANTI-INFLUENZA VACCINE)

● **CLINICAL CASE N° 10**

YEAR 2008. "PROLONGED INFLUENZA" COMPLICATED WITH ACUTE MYOCARDITIS, AND ACUTE HEART FAILURE. IT IMPROVED WITH THE TREATMENT OF ANTIVIRAL OSELTAMIVIR
(MYOCARDITIS CAUSED BY THE INFLUENZA VIRUS FROM THE ANTI-INFLUENZA VACCINE)

● **CLINICAL CASE N° 11 (SYNTHESIS)**

YEAR 2010. "PROLONGED INFLUENZA" COMPLICATED WITH RED LICHEN PLANUS. IT IMPROVED WITH THE TREATMENT OF ANTIVIRAL OSELTAMIVIR

● **CLINICAL CASE N° 12**

YEAR 2012 - "PROLONGED INFLUENZA" (9 MONTHS OLD GIRL).
"PROLONGED INFLUENZA" COMPLICATED WITH PRIMARY PNEUMONIA AND RESPIRATORY FAILURE - CURED WITH ANTIVIRAL OSELTAMIVIR IN 6 DAYS.
(PNEUMONIA CAUSED BY THE INFLUENZA VIRUS FROM THE ANTI-INFLUENZA VACCINE).

PARTE VII

Clinical Cases Of Prolonged Influenza by Mutation

● **CLINICAL CASE N° 1**

"PROLONGED INFLUENZA BY MUTATION" CURED WITH OSELTAMIVIR ANTIVIRAL

● **CLINICAL CASE N° 2**

"PROLONGED INFLUENZA BY MUTATION" CURED WITH OSELTAMIVIR ANTIVIRAL

● **CLINICAL CASE N° 3**

"PROLONGED INFLUENZA BY MUTATION" COMPLICATED WITH PRIMARY VIRAL BILATERAL PNEUMONIA AND DEATH. THE TREATMENT WITH THE ANTIVIRAL OSELTAMIVIR WAS NOT CARRIED OUT
(COMMUNITY-ACQUIRED PNEUMONIA)

● **CLINICAL CASE N° 4**

"PROLONGED INFLUENZA BY MUTATION" COMPLICATED WITH PRIMARY PNEUMONIA AND CURED WITH OSELTAMIVIR.(COMPLICATED WITH COMMUNITY-ACQUIRED PNEUMONIA)

● **CLINICAL CASE N° 5**

"PROLONGED INFLUENZA BY MUTATION" COMPLICATED WITH PRIMARY PNEUMONIA (INFECTED WITH COMMUNITY-ACQUIRED PNEUMONIA)

● **CLINICAL CASE N° 6**

YEAR 2012 - "PROLONGED INFLUENZA BY MUTATION" COMPLICATED WITH PRIMARY BILATERAL PNEUMONIA AND WITH RESPIRATORY FAILURE LEVEL IV; AND CURED WITH OSELTAMIVIR IN 7 DAYS.
(INFECTED WITH COMMUNITY-ACQUIRED PNEUMONIA)

PART V

Clinical Cases of diseases treated with Oseltamivir antiviral, with good results

CLINICAL CASE N° 1

VIRAL MENINGOENCEPHALITIS WITH INFLUENZA SIGNS AND SYMPTOMS, IN A TYPE-B EPIDEMIC, CURED WITH ANTIVIRAL OSELTAMIVIR

CLINICAL HISTORY: YEAR 2002

1) Personal information:

Gender/sex: male.

Age: 17 years old.

Address: Posadas.

Job: A student.

Nacionality: Argentinian.

2) Hospitalized patient:

Date of hospitalization:

September 10, 2002 in the emergency room (Day 1).

September 12th, 2002, in a ward (Day 2).

Date of release: September 26, 2002.

3) Reasons for coming to the hospital:

Headache, vomiting, dizziness, loss of strength in the legs, a feeling of being hot.

4) Antecedents of this disease:

A patient that had had the flu for ten days, with the following symptoms: asthenia, headache, arthromyalgias, fever, muco-serous rhinorrhea, a cough with little muco-serous expectoration. The patient had not rested in bed and had taken acetylsalicylic acid, a 500mg.tablet twice a day. Two days before coming to the surgery, the patient's headache increased, and he had photophobia, a headache in the back of head and trouble for urinating.

There had been an epidemic of influenza B in the whole province, and the patient had caught it from his father.

5) Important antecedents: a patient without previous pathological antecedents. He had always been healthy.

He entered the emergency room on 10 September 2002, the Glasgow Coma Scale was 15; he had urinary retention, so a urinary catheter was placed.

11 September 2002, the following day. The patient showed general deterioration, nuchal rigidity; he was lethargic. A urine test and a blood culture were requested. A CT scan was made, - normal results- and a lumbar puncture was performed, obtaining rock crystal liquid.

12 September 2002. He was hospitalized in the general ward. A patient's relative was interviewed, as he showed altered consciousness, lethargy and dyslalia.

6) Physical examination: Important information:

Blood tension: 120/60 mmHg

Heart rate: 100 bpm

Respiratory rate: 18 breaths per minute

Temperature: 36° C

General Physical Examination: The patient was in a bad general condition, in a fixed dorsal decubitus position; his face showed he was very ill; he was pale, sweaty, tachycardic, lethargic; his walking could not be evaluated.

Skin and nails: normal elasticity and turgescence, moist mucous membranes.

Head: diminished eye openings, isochoric, myotic pupils with decreased reflexes.

Genitourinary system: non-painful urethral points, fist and percussion. He had permanent vesical catheterization.

Peripheral and central nervous system:

Lethargic and dyslalic patient with photophobia, nuchal rigidity, diminished strength of eyes and lids, weakness in the central and right muscles of the face, left positive Babinski, normal muscular strength in arms but diminished in legs. Leg paresis.

7) Diagnosis:

1- Meningitis syndrome.

2- Viral meningoencephalitis

3- Influenza

Doctors requested the hospital's authorities to take him to an intensive care unit, but request was denied as there were no free beds.

8) Complementary methods:

Head CT with a contrast: normal

Front chest x-ray: normal

Gas in blood: normal

Hematocrits: 47%

Leucocytes: 9000 cells/ml

Neutrophils: 78 %

Lymphocytes: 19 %

Monocytes: 3%

Glucose: 143 mg/dl

Blood Urea Nitrogen: 28 mg/dl
Plasma and urine ionogram: normal
Cerebrospinal fluid:
Clear
Slightly cloudy
Cell count: 31, mainly mononuclear leukocytes
Glycorrachia: 0.69 g/l
Proteinorrachia: 0.67 g/l
Pandy test: negative
Bacteriologic culture: direct observations:
Neither polymorphonuclear WBC nor microorganisms.
Culture: negative 24 hs. later
Blood culture: negative
Urine culture: negative
V.D.R.L. test: negative
HIV test: negative

Advice from a neurologist was sought. He requested a MRI to evaluate the mesencephalon, suspecting viral meningoencephalitis.

September 13, 2002

4th. Day in Hospital (2nd. Day in a general Ward, 1st. day on Oseltamivir)

The patient was in a bad general condition, running a temperature, 38° C, lethargic, with a headache, nausea, nuchal rigidity. Diplopia and upper limb paresia - this was a cuadriparesia.
A nasopharyngeal swab was obtained. Blood was taken and fecal samples collected for viral tests.

Lab blood tests:

Leukocytes: 12800 cells/ml
Neutrophils: 94 %
Lymphocytes: 19 %
Eosinophils: 0%
Basophils: 0%
Bands: 0%
Erythrocyte sedimentation rate: 13 mm/1st hr.

The patient showed a greater conscience loss; he was lethargic, and had upper limb paresia. An increase in leukocytosis – from 9000 to 12800 cells/ml and the neutrophylia, showed a progressively worsening neurological prognosis.

Comments:

The viral meningitis encephalitis diagnosis -with a type-B influenza epidemic in the province - was confirmed by the Instituto Malbrán. The patient's father had suffered from influenza with a slight epistaxis and his son had caught it from him – it was possible to assert that the patient suffered from the same clinical manifestations of the influenza epidemic that had been seen in San Pedro (Misiones), confirming that there was a province and family epidemic.

Epidemiologic diagnosis: There was 85% certainty of the presence of an epidemic, based on clinical manifestations of influenza, and the type B influenza epidemics confirmed by health authorities.

Reasoning:

In view of these clinical manifestations, the severe neurological prognosis that was progressively worsening, the epidemic of type B influenza in the province and the family contagion, the decision of administering antiviral Oseltamivir was taken. There was a suspicion of type B influenza and no other treatment was possible, as there was no medical bibliography available for treating viral meningoencephalitis caused by a flu virus.

9) Treatment:

Treatment with Oseltamivir started with one 75mg capsule every 12 hs, and IV therapy 35 drops per minute.

September 14, 2002

5th. Day in Hospital (2nd. day on Oseltamivir)

The patient told doctors about his fast recovery after the first pill he swallowed and he said that he had started to wake up. When he was examined there was an evident recovery in the patient's signs and symptoms. The languour disappeared and he awoke, but he was still running a temperature - 38°C. Due to this recovery, the Oseltamivir dose was increased to one pill every 8 hours.

A head MRI was performed: there was a report of an injury in the encephalic trunk, right superior cerebellar peduncles and right temporal uncus, compatible with demyelinating changes.

September 15, 2002

6th. Day in Hospital (3rd. day on Oseltamivir)

The patient was fully awake, fever 38.5 °C, his arm paresia was improving, not so much his legs. He sat on his bed by himself, he still had the renal catheter and there was a visible clinical recovery. The Oseltamivir dose was increased to one capsule each 6 hours. B vitamins were added.

September 16, 2002

7th. Day in Hospital (4th. day on Oseltamivir)

The patient recovered progressively from his meningoencephalitis, he had no fever, he was wide awake, well placed in time and place. Nausea, vomits and headaches had disappeared. He showed a negative Babinski; improvement in his legs paresia and an almost complete recovery in his arms.

The patient was able to stand up alone, with nobody's help, he still had a bilateral paralysis of the VI cranial pair. He had few rales in both lower lobes of the lungs. He still had the renal catheter.

Lab blood tests:

Leukocytes: 12100 cells/ml

Neutrophils: 75 %

Lymphocytes: 18 %

Monocytes: 2 %

Eosinophils: 5 %

Basophils: 0%

Bands: 0%

Platelets: 258000 cells/ml

Erythrocyte sedimentation rate: 45 mm/1st hr.

As the clinical progress was excellent, the Oseltamivir dose was reduced to one capsule every 8 hours.

September 17, 2002**8th. Day in Hospital (5th. day on Oseltamivir)**

The patient went on recovering progressively. He had almost a complete recovery of arms and a slight paresia of legs, which allowed him to walk. He started to walk alone.

His body and his legs itched. Auscultation showed no noises in his respiratory system.

Lab results of immunofluorescence tests of nasal and pharyngeal secretions for detection of respiratory viruses, respiratory *syncytial* virus, adenovirus, A and influenza virus and parainfluenza 1, 2 and 3: All of them showed negative reactivity.

Treatment: Oseltamivir one 75 mg capsule every 8 hours.

September 18, 2002**9th. Day in Hospital (6th. day on Oseltamivir)**

The patient went on recovering clinically from leg paresia, he walked but still showed bilateral paralysis of the VI cranial pair.

Lab blood tests:

Leukocytes: 7700 cells/ml

Neutrophils: 60 %

Lymphocytes: 31 %

Monocytes: 0 %

Eosinophils: 9 %

Basophils: 0%

Bands: 0%

A clear decrease in leukocytes and neutrophils can be seen.

Treatment: Oseltamivir one 75 mg capsule every 8 hours.

September 19, 2002

10th. Day in Hospital (7th. day on Oseltamivir)

The patient went on recovering neurologically, recovering muscle strength in his legs progressively; he still showed bilateral paralysis of the VI cranial pair.

Treatment: Due to the good clinical development, it was decided to reduce Oseltamivir to one capsule every 12 hours and ibuprofen 600 mg was added every 12 hours by oral route.

September 20, 2002

11th. Day in Hospital (8th. day on Oseltamivir)

The patient went on recovering progressively, recovering muscle strength in his legs. He was walking better.

Lab Tests: Results were received from the Instituto Malbrán from Buenos Aires. The Neurovirus, Enterovirus and Parotiditis Service reported that all of them were negative (detection by viral genome method)

From the Respiratory Virus Service: (Immunofluorescence technique and IgM Antibody Test):

Respiratory Syncytial Virus: Negative

Adenovirus: Negative

Parainfluenza types 1, 2 and 3 virus: Negative

A-influenza Virus: Negative

B-influenza Virus: Negative

Immunofluorescence Test for detection of Mycoplasma pneumoniae: Positive

Treatment:

Oseltamivir: one 75 mg capsule every 12 hours. Due to the test results, a 500mg

Clarithromycin tablet every 12 hours was added to the treatment due to the positive Immunofluorescence Test for Mycoplasma pneumoniae , although it did not agree with the clinical and epidemiologic features and the excellent clinical progress after the 8-day antiviral treatment with Oseltamivir.

September 21, 2002

12th. Day in Hospital (9th. day on Oseltamivir)

The patient kept on getting better from the neurological point of view. Although the renal catheter was taken off, he still had urinary retention. A neurogenic bladder was suspected.

Treatment: Oseltamivir: one 75 mg capsule every 12 hours. The second day of a Clarithromycin 500mg-tablet every 12 hours.

September 22, 2002

13th. Day in Hospital (10th. day on Oseltamivir)

The patient kept on recovering and still had the renal catheter installed.

Treatment: Oseltamivir: one 75 mg capsule every 12 hours. The third day on antibiotics, he was taking Clarythromycin 500mg tablet every 12 hours. The Ibuprofen administration was stopped.

September 23, 2002

14th. Day in Hospital (11th. day on Oseltamivir)

The patient kept on recovering clinically and neurologically. His leg paresia and VI par bilateral paralysis went on recovering too.

Treatment: Oseltamivir: one 75 mg capsule every 12 hours. The fourth day of a treatment with Clarythromycin, 500mg tablet every 12 hours.

September 24, 2002

15th. Day in Hospital (12th. day on Oseltamivir)

The patient kept on recovering and still had the renal catheter installed.

Lab blood tests:

Leukocytes: 6000 cells/ml

Neutrophils: 66 %

Lymphocytes: 30 %

Monocytes: 2 %

Eosinophils: 2 %

Basophils: 0%

Bands: 0%

Erythrocyte sedimentation rate: 45 mm/1st hr.

Treatment: Oseltamivir: one 75 mg capsule every 12 hours. The fifth day of a Clarythromycin 500mg tablet every 12 hours.

September 25, 2002

16th. Day in Hospital (13th. day on Oseltamivir)

The patient kept on recovering. The renal catheter was taken away and an intermittent catheterization was provided.

Treatment: Oseltamivir: one 75 mg capsule every 12 hours. The sixth day of a Clarythromycin treatment, 500mg tablet every 12 hours.

September 26, 2002

17th. Day in Hospital

The patient was released from hospital. He was told to take Oseltamivir, 75 mg capsule every 12 hours during 7 days (until he completed 20 days) and Clarythromycin 500mg tablet every 12 hours during 9 days (until he completed 15 days).

He was not given corticosteroids during hospitalization.

Comments:

Seeing the onset of the disease and the clinical development of the patient, the meningoencephalitis is thought to have been viral, as it presented corresponding signs and symptoms, with a type-B influenza virus epidemic, -in the family and in the region- reported by the Health Authorities. Analyzing the neurological progress of the patient, with an extraordinary fast clinical recovery when the antiviral Oseltamivir treatment started, during the first 24-48 hours and the following days, it may be said that the diagnosis is reasserted, due to the excellent response to the assigned antiviral treatment (although Clarythromicine was added 8 days later, as a response to the possible mycoplasma pneumoniae infection). This last treatment did not show a clear clinical recovery or a clinical progress different from the progress of the Oseltamivir antiviral already being taken.

In conclusion:

In view of all the clinical history developed in this report, it is confirmed that the diagnosis was type B influenza viral meningoencephalitis, treated successfully with antiviral Oseltamivir

Long Term Development: Consequences: A year later, the patient spoke about alterations in the recent memory and difficulty to learn at high school which he finally quit. They were cognitive alterations.

- This question lingers: if he had been treated with corticoids, would his disease have improved faster and perhaps would the neurological consequences have been diminished or prevented?

- If he had been diagnosed earlier and treated with Oseltamivir, this kind of complications and consequences would have been prevented.

It is important that this treatment becomes known everywhere. Clinical and epidemiological studies should be made all around the world to treat this disease and save millions of lives.

CLINICAL CASE N° 2

PRIMARY VIRAL PNEUMONIA WITH INFLUENZA SIGNS AND SYMPTOMS, SUCCESSFULLY TREATED WITH ANTIVIRAL OSELTAMIVIR. (Community-acquired pneumonia)

CLINICAL HISTORY: YEAR 2005

1) Personal information:

Sex/Gender: female

Age: 72

Residing at: Posadas

Job: A housewife.

Nationality: Argentine

2) A hospitalized patient:

- Admittance date: 12 September 2005 (1st day)
- Date of Discharge: 24 September 2005

3) Reasons for coming to the hospital: Intense asthenia.

4) Antecedents of this disease:

A week before she came to the hospital, she had begun with severe asthenia, fever, generalized myalgia, a sore throat, rhinorrhea, a cough with scarce mucous expectoration. A pain in the right lower lobe hemithorax that increased with deep breathing was added. Later, she presented with dysphonia.

She reported an interesting piece of information: four months before she had noticed type II-III dyspnea, paroxysmal nocturnal dyspnea and muscular weakness.

5) Important antecedents: Arterial hypertension for more than 30 years, treated at the moment with atenolol 100 mg a day.

The hypothyroidism diagnosed more than 30 years before, was treated with levothyroxine 100 mg. a day.

Cholecystectomy 20 years before.

Appendicectomy 40 years before.

Genetic antecedents: arterial hypertension and hypothyroidism.

6) Physical examination: Important information:

Blood tension: 210/110 mmHg

Heart rate: 50 bpm

Respiratory rate: 24 breaths per minute

Temperature: 36.4° C

The patient was in a bad general condition, with Glasgow Coma Scale 15/15, well aware of time and space, altered facial expression, indifferent, in dorsal decubitus position, walking not evaluated. She entered the hospital in a wheelchair with peripheral IV.

Subcutaneous cellular tissue: Slight cutaneous paleness. She presented with bilateral leg edema (One cross out of four).

Neck: thyroids were not palpated.

Respiratory system: She presented with hypoventilation and crepitant rales in the lower lobe of the right hemithorax.

Central and peripheral nervous system: The patient lateralized to the right when she got up.

7) Diagnosis:

1 – Community-acquired pneumonia

2 – Influenza

3 – Alteration in balance

Other diagnosis:

1 – arterial hypertension

- 2 – hypothyroidism
- 3 – obesity

8) Complementary methods:

Lab tests taken before her hospitalization on September 5th 2005.

WBC: 11000 cells/ ml

Neutrophils: 74 %

Bands: 0%

Lymphocytes: 24 %

Eosinophils: 4 %

Basophils: 0%

Monocytes: 0 %

TSH test: 12.9 mUI/ml - increased value (normal values: 0.32 – 5)

Complementary methods prescribed during her hospitalization:

Chest X-rays before she was hospitalized on August 24, 2005.

Alveolar and interstitial infiltrates in both lower lobes and hilar congestion in the whole left hemithorax. (See fig. 1)

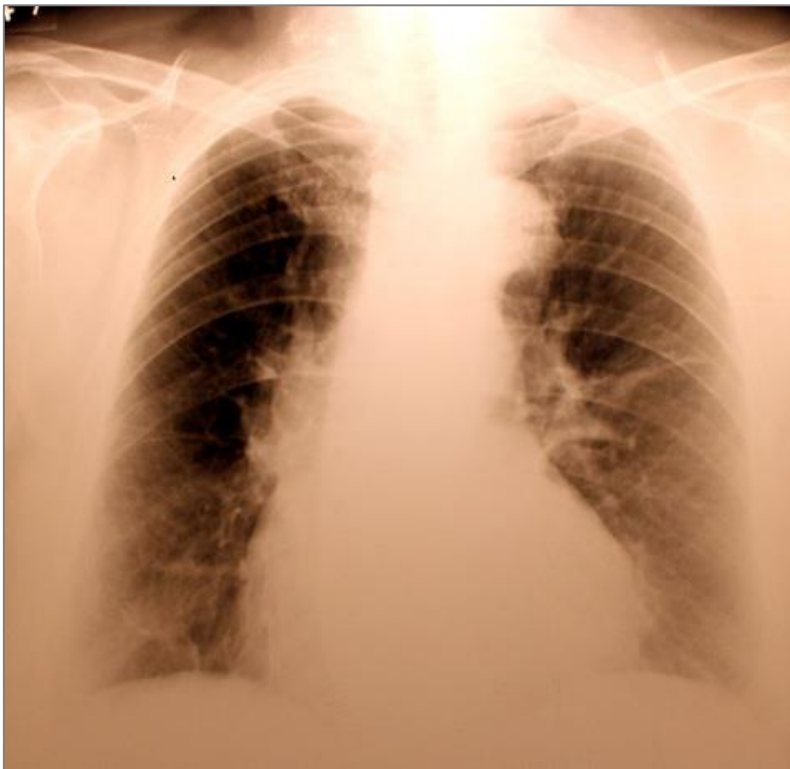


Fig.1: Date 24 August 05

Chest RX on hospitalization day: 12 September 05:

Hilar congestion, alveolar and instersitial infiltrates in the right hemithorax and in lesser degree, in the left hemithorax, cisuritis in the right hemithorax. Fibrous tracts in the left hemithorax. (See fig. 2)

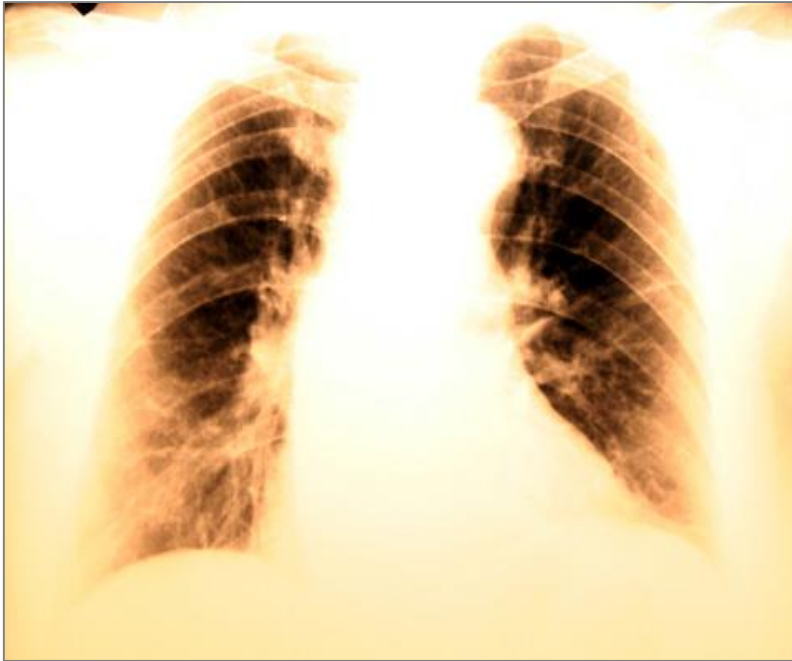

Fig. 2: Date 12/09/05

Electrocardiogram:

Sinus bradycardia. Enlarged left ventricle hypertrophy with overload.

Lab blood tests:

WBC: 9600 cells /ml
Neutrophils: 75 %
Bands: 0%
Lymphocytes: 15 %
Eosinophils: 5 %
Basophils: 0%
Monocytes: 1 %
Blood Glucose: 1.87
Blood urea nitrogen: 0.32
Platelets: 43 %

9) Diagnosis confirmed:

In view of the signs and symptoms, the chest x-ray and the lab tests, the following diagnosis was made:

- 1 - Primary viral pneumonia caused by influenza
- 2 - Type II Diabetes, diagnosed when she was hospitalized.

Presumptive diagnosis:

1 - Imbalance, neurological affection produced by the same viral influenza disease.

10) Treatment:

- 1- Bed rest
- 2- Low salt diet for diabetics.
- 3- Atenolol 50 mg. a day - the 100-dose was reduced because of bradycardia.

- 4- Enalapril 20 mg a day – it was added due to increased blood pressure.
- 5- Espironolactona 25 mg. a day.
- 6- Levotiroxina 100 mg a day.
- 7- Sodic heparine 5.000 units every 12 hs subdermic (in prevention of deep vein thrombosis)

2nd. Day at hospital: 13 September 2005

The patient did not have a temperature, had high blood pressure 170/80 mmHg, heart rate 52 bpm. She still had hypoventilation and crepitant rales in the right lower lobe.

3rd. Day at hospital: 14 September 2005 (1st. Day on Oseltamivir)

The patient did not have a temperature. She had high blood pressure. She still had hypoventilation and crepitant rales in the right lower lobe of the lung.

A nasopharyngeal swab was taken to make diagnostic viral tests. Neurological consultations showed dysbasia.

Lab blood tests:

WBC: 10300 cells/ml.

Neutrophils: 66 %

Bands: 0%

Lymphocytes: 32 %

Eosinophils: 2 %

Basophils: 0%

Monocytes: 1 %

E.S.R: 15/1st. Hr.

Blood Glucose: 1.25

Total Proteins: 8.13 g/dl

Albumin: 3.74 g/dl

Total Cholesterol: 205 mg/dl

Triglycerides: 124 mg/dl

Total urinalysis: normal

Abdominal Ultrasound: Normal.

In view of the clinical diagnosis of viral pneumonia and influenza, it was decided to start the treatment with a specific anti-influenza antiviral Oseltamivir, 75-mg-dose capsules every 8 hours, to wait for the therapeutic effect and not to treat with antibiotics.

4th. Day at hospital: 15 September 2005 (2nd. Day on Oseltamivir)

The patient did not have a fever. Blood pressure 140/70 mmHg, heart rate 60 bpm, the respiratory semiology presented a better air entrance in the right lower lobe and persistence of crepitant rales. The patient showed an extraordinary recovery in her clinical evolution after the treatment with Oseltamivir and no antibiotics.

The patient's report:

She was feeling better, she moved more easily in bed, the severe asthenia almost disappeared. She reported the immediate recovery from her condition, after the first dose of the antiviral treatment with Oseltamivir.

5th. Day at hospital: 16 September 2005 (3rd. Day on Oseltamivir)

She did not have a fever, she still had high blood pressure, she had high levels of glucose in blood - 1.37 g/L-; the respiratory semiology kept on recovering, there was a better air entrance in the right lower lobe and less crepitan rales on the same side. Her imbalance disappeared almost completely.

The patient spoke about a 70% recovery in her condition, after starting the treatment with Oseltamivir.

It was decided to go on with the Oseltamivir treatment because of the excellent fast clinical recovery.

Both her ears were examined and the results were normal.

6th. Day at hospital: 17 September 2005 (4th. Day on Oseltamivir)

The patient did not have a fever, her blood pressure was normal, her blood glucose 1.40 g/L, better respiratory ventilation and few crepitan rales in the right lower lobe.

Signs and symptoms had a good clinical evolution.

A head CT Scan was done which showed cortical and subcortical cerebral diffuse atrophy. There were not any haemorrhagic nor ischemic points and no alterations in the posterior fossa.

An MRI was not requested, although it should have been done to evaluate the brain stem.

7th. Day at hospital: 18 September 2005 (5th. Day on Oseltamivir)

The patient did not have a fever, her blood pressure was normal, her blood glucose 1.40 g/L.

She walked alone and an important clinical improvement could be seen.

8th. Day at hospital: 19 September 2005 (6th. Day on Oseltamivir)

The patient did not have a fever, her blood pressure was normal, her blood glucose 1.10 g/L, there was a good air entrance in her lungs. She did not have crepitan rales in the right lower lobe. She did not show lateralization when walking, her clinical, respiratory and neurological evolution was good.

Lab blood tests:

WBC: 10700 cells/ml

Neutrophils: 71 %

Bands: 0%

Lymphocytes: 24 %

Eosinophils: 2 %

Basophils: 0%

Monocytes: 3 %

Platelets Count: 290000 cells / mm³
Blood Glucose: 1.13 g/L

Treatment:

Due to the good evolution, the Oseltamivir dose was reduced to one capsule each 12 hours.

9th. Day at hospital: 20 September 2005 (7th. Day on Oseltamivir)

The patient showed good clinical progress, she did not have a temperature, her blood pressure was normal, she walked by herself.

A fundoscopy was performed

It showed her arteries had a very diminished calibre, but there were not other pathologies.

Chest X-ray (control):

A real reduction of the alveolar-interstitial infiltrates in the right and left lower lobes. (See fig. 3)

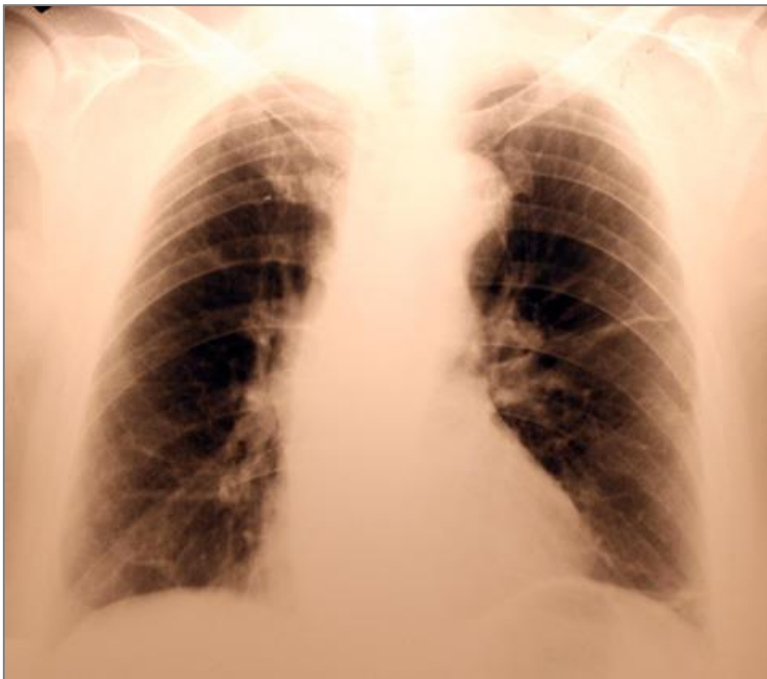

Fig. 3: Date: 20 September 2005

Lab Tests:

Positive (++++) C-reactive protein.

A mammogram and X- ray of the cervical spine was requested.

10th. Day at hospital: 21 September 2005 (8th. Day on Oseltamivir)

The patient showed good clinical progress, she did not have a temperature, her blood pressure was normal.

11th. Day at hospital: 22 September 2005 (9th. Day on Oseltamivir)

The patient showed a good clinical progress, she did not have a temperature, her blood pressure was normal.

Mammogram report: it was normal for the patient's age.

Lab Tests:

E.S.R: 75/1st. Hr.

12th. Day at hospital: 23 September 2005 (10th. Day on Oseltamivir)

Good clinical recovery.

Ear Examination: Normal.

Cervical Spine X-Ray: Normal

13th. Day at hospital: 24 September 2005 (11th. Day on Oseltamivir)

The patient was sent home, with a medical prescription. She was on Oseltamivir one capsule every 12 hs for 5 days. During hospitalization, anti-inflammatory drugs were not given.

Lab blood tests:

WBC Count: 5200 cells / ml.

Neutrophils: 69 %

Bands: 0%

Lymphocytes: 26 %

Eosinophils: 1 %

Monocytes: 1 %

Basophils: 0%

Blood Glucose: 1.24 g/L

Total Cholesterol: 194 mg/dl

Triglycerides: 122 mg/dl

The viral report of the nasopharyngeal swab was missing.

Final Comments:

A viral primary pneumonia caused by the influenza virus was diagnosed. It was based on the acute respiratory clinical diagnosis, the influenza with no muco-purulent expectoration and a diagnosis of pneumonia; a chest X-ray where alveolar interstitial infiltrates could be seen; laboratory tests with leukocytosis, neutrophils were predominant and an inflammatory condition shown by positive PCR and high ESR.

With this diagnosis, the patient was treated with Oseltamivir one 75-mg capsule every 8 hs. during the first 5 days and then every 12 hours, until a 15-day treatment was finished.

During the first days of treatment, the patient showed **an extraordinary 70 % recovery** of signs and symptoms in 48 hours. The patient also reported this 70% recovery in 48 hours in all her symptoms after the Oseltamivir capsules were administered.

The fast extraordinary clinical recovery with Oseltamivir reasserts the correct diagnosis of viral pneumonia by influenza virus, in view of the effects of the specific treatment with an anti-influenza antiviral drug (good effects of the treatment).

This can also be considered as a diagnostic trial, to see the effect of the first dose of antiviral drug Oseltamivir, in a few hours or in 24-48 hours of its therapeutic effect.

Leukocytosis and high positive (+++++) ESR persistence until the 6th and 7th day of the treatment with Oseltamivir could be related to a lack of treatment with anti-inflammatory drugs, as no corticosteroids were prescribed because of her diabetes and no anti-inflammatory non-steroid drugs were prescribed either, which could have improved her condition faster.

The onset of diabetes is generally caused by a genetic predisposition, but in this case it is probable that it was produced by a pancreatic lesion caused by the virus.

As a conclusion, it is stated that this case of primary viral pneumonia caused by the influenza virus, diagnosed by signs and symptoms and treated with specific anti-influenza antiviral Oseltamivir, had an excellent fast recovery. It is suggested to consider it and perform more clinical and epidemiological studies.

PARTE VI

Clinical Cases of "Prolonged Influenza"

CLINICAL CASE N° 1

PROLONGED INFLUENZA

Prolonged Influenza

Cured with antiviral drug Oseltamivir, without any complications

(This is one of the most frequent cases of patients who were affected by the anti-influenza vaccine)

CLINICAL HISTORY: AÑO 2007 (out patient)

1) Personal information:

Sex/Gender: Female.

Age: 44 years old.

Address: Garupá - Misiones.

Job: a nurse.

Nationality: Argentinian.

2) Visit to the clinician's office: 17 September 2007.

3) Reason for coming to the clinician's office: Severe asthenia, rhinitis and fever.

4) Antecedents of the present disease: The patient was given the vaccine for the first time on 27 July 2007. 7 Days later he started with muco-serous rhinitis, repetitive sneezing, temperature higher than 38° C for 48 hs. and then less than 38°C, severe asthenia, severe anorexia, intense arthromyalgia, severe frontal headache, photophobia, night sweating, palpitations, epistaxis, painful eyes, watering eyes, intense throat pain, her throat was dry and hot with a feeling that made swallowing difficult, irritative intense coughing, mucoserous bloodstained coughing up. She presented with bronchospasm (sibilances), pain in the back that increased with deep inspiration, adynamia. She was worried for her long-lasting disease. 20 Days later, mucoserous rhinitis and expectoration turned into muco-purulent.

The acute condition lasted 20 days, and her condition did not improve. She presented with 2 relapses with the same symptoms but less intense, and at that moment she had not been cured.

During this disease she lost 12Kg. because of the great anorexia she presented with. At the time of her visit to the clinician's office, she had been ill for one month and 20 days. She had permanent symptoms of asthenia, mucoserous rhinitis and fever in the evenings. Three times in two months she had been prescribed antipyretics, anti-inflammatory drugs and antibiotics but she had not been cured.

5) Other important antecedents: The patient was healthy and she did not have any previous disease.

6) Physical Examination: The patient was awake, did not have a fever, she was asthenic.

Blood pressure: 120/70 mmHg

Respiratory System: At auscultation, it was normal.

Heart: Regular pulse. No murmurs. Normal first and second noise.

7) Diagnosis: With these clinical signs and symptoms the following diagnosis was made:

- 1) Prolonged respiratory viral disease
- 2) Prolonged Influenza.

8) Treatment: Only the antiviral drug against the influenza virus was prescribed: Oseltamivir one 75mg. tablet every 12 hours for five days, and no other medication.

9) Development of the disease: The patient's health improved after the third tablet (36hs.) 48hs. later 40%, 4 days later 80% and 5 days later 100%.

This improvement was stated by the patient and confirmed by the good clinical development.

Thirty days later: She was healthy and she had not presented with any symptoms of the disease.

10) Progress of the disease and comments on the treatment: A very good clinical effect of the treatment was seen. The patient was fully cured in 5 days.

Only the antiviral Oseltamivir was prescribed . The patient was not treated with other medicines such as anti-inflammatory drugs or antibiotics.

This fast and effective therapeutic effect was fast and effective. It shows once again that this disease is produced by the influenza virus, as the disease was only treated with the antiviral anti-influenza drug Oseltamivir,

If the patient had not been treated with a specific antiviral drug such as Oseltamivir, she would not have been cured and she would have had relapses with pulmonary, cardiac, renal and other life-threatening diseases.

Important Comments: The patient had never taken the anti-influenza vaccine. She took it for the first time in 2007.

She took it in her workplace (at the hospital) and she fell ill just the same as other workmates with the same prolonged respiratory symptoms, repeating the same disease she had had after taking the vaccine.

She said that ten other workmates had received the vaccine at the same time, five of them had fallen ill with the same symptoms and the same disease.

It was the first time that she had presented with sibilances and bronchospasm, which she had never had before.

It was the first time that she had fallen ill with such an intense respiratory viral condition that did not improve.

Before, influenza had only lasted 3 days and she had got better alone. She had never had such a long disease in her life. She decided not to take the vaccine again.

- This is another case of hundreds of patients when the diagnosis was correctly made and treated with the antiviral drug and the patients were fully cured.
- But there are hundreds of thousands of sick people, who have not been diagnosed and treated specifically, who have this disease, with the risk of complications and death even in this year 2013.

CLINICAL CASE N° 2

PROLONGED INFLUENZA

Prolonged Influenza **Complicated with primary viral bilateral pneumonia**

(Pneumonia caused by the influenza virus from the anti-influenza vaccine)

CLINICAL HISTORY: YEAR 2006 (Hospitalized patient)

1) Personal information:

Sex/Gender: Female.

Age: 60

Address: Santo Pipó - Misiones.

Job: A housewife

Nationality: Argentine.

2) Hospitalized patient: She was admitted to the hospital through the emergency room on July 7th. 2006. She was discharged on July 21st. 2006.

3) Reason for coming to the hospital: Dyspnea at rest (transferred from a health center due to an asthmatic crisis).

4) Antecedents of the present condition:

The patient had fallen ill 8 days before hospitalization – on June 30th. 2006 - with the following symptoms: severe asthenia, headaches, sneezing, rhinitis, a sore throat and arthromyalgias. After three days, she presented dyspnea type II-III, a fever, cough, muco-serous and then muco-purulent expectoration, pleuritic chest pain in the left lung base, diarrhea for three days. Dyspnea increased to type IV, which led to consultation and hospitalization.

These symptoms correspond to a respiratory viral infection.

Interesting information: She was given the anti-flu vaccine on April 2006, and 7 days later she fell ill with prolonged influenza, which lasted 2 months, and was not completely cured. In May and June she had two relapses, in July another relapse, which brought about this disease as a consequence. She visited her doctor, who decided to hospitalize her.

This last relapse of the disease was "Prolonged Influenza".

5) Important antecedents: Bronchial asthma, diagnosed 19 years before. She was treated regularly with salbutamol and budesonide.

Arterial hypertension diagnosed 20 years before and treated at the moment with enalapril 10 mg a day.

6) Physical examination: The patient was awake, aware of time and space, with a 15/15 Glasgow, in active supine position.

Blood Pressure: 160/70 mmHg

Temperature: 36.7 ° C

Heart Rate: 110 bpm

Weight: 62 kg – 136.4 lbs.

Neck: jugular ingurgitation (2/3) with a respiratory collapse.

Respiratory System: She presented with type-IV dyspnea, hypoventilation in both lung bases and sibilance in both lungs, crepitant rales in both lung bases with left predominance.

Cardiovascular System: hypo-phonetic cardiac noise, no heart murmurs were heard.

7) Diagnosis:

1. Bilateral pneumonia.
2. A relapse of bronchial asthma.
3. A respiratory viral infection before the onset of the disease.
4. A 4-month development of prolonged influenza that was not cured, produced by the anti-influenza vaccine in April 2006.

Other diagnosis:

- 1- Long-lasting bronchial asthma
- 2- Arterial Hypertension.

8) Complementary methods:

Front chest x-ray, hilar congestion, interstitial alveolar filtering in both lung bases, second cardiac left arch rectification. Cardio thoracic index: 0.43

ECG: Cardiac Frequency: 110 bpm, sinus rhythm, negative T-wave in V1, lack of progression of R-wave from V1 to V3.

Laboratory Lab Tests:

WBC count: 12800 cells /ml
Hematocrits: 49 %
Urea: 0.32 g/L
Glucose: 2.94 g/L

9) Diagnose confirmed:

1 – Primary viral bilateral Pneumonia (by X-rays and clinical examination)
The patient presented with hyperglycemia, so diabetes was suspected.

10) Treatment:

- 1- Abundant oral hydration.
- 2- IV infusion, normal saline solution – 3 litres a day.
- 3- Parenteral aminophylline
- 4- Diphenhydramine one pill every 8 hs.
- 5- Hydrocortisone 500mg. a day.
- 6- Common insulin after glucose control.
- 7- Intermittent low flow humid oxygen.
- 8- Nebulisations with salbutamol every 6 hs., adding Ipratropium bromide.
- 9- Glucose control through blood glucose test strips.
- 10- Diabetes low-sodium diet.
- 11- Respiratory physiotherapy.
- 12- Semi supine position.

2nd Day in hospital – July 8th 2006

Blood Pressure: 100/60 mmHg
Heart rate: 100 bpm
Respiratory Frequency: 28 breaths per minute.
Temperature: 36.5°C

The patient was in a bad condition, type IV dyspnea, hypoventilation and sibilances in both lungs.

3rd day in hospital – 9th July 2006

Blood Pressure: 130/100 mmHg.
Heart Rate: 85 bpm
Respiratory Frequency: 21 breaths per minute
Temperature: 37°C

Generalised hypoventilation lingered, sibilance in both lungs, diarrheic stools with slight abdominal pain.

Loperamide was added to the treatment after each diarrheic stool every 6 hours and ranitidine, one pill every eight hours. Dyphenhydramine was suspended.

2 Blood cultures were requested, sputum culture and acid-alcohol resistant bacillus (BAAR) for tisiology.

4th day in hospital, 10th July 2006

Blood pressure: 170/100 mmHg
Heart rate: 120 bpm
Respiratory Frequency: 20 breaths per minute
Temperature: 36.5°C

The signs, symptoms and general state of the patient improved; bilateral hypoventilation with rhonchi and sibilance in both lungs, abundant mucus production, severe diarrhea; the patient was still treated with loperamide.

Parenteral aminophiline was suspended.

Lab Blood Tests:

WBC: 4900 cells/ml

Neutrophils: 84%

Lymphocytes: 16%

Eosinophils: 0%

Basophils: 0%

Monocytes: 0%

Urea: 0,62 g/L

Blood Glucose: 3,13 g/L

Platelet Count: 157.000 mm³

Hematocrits: 46%

Gas in Blood:

pH: 7,49

pCO₂: 40% mmHg

pO₂: 79% mmHg

Sat. O₂: 87%

5th. Day in hospital - 11th July 2006 (she was transferred to a ward)

Blood Pressure: 160/100 mmHg
Heart Rate: 90 bpm
Respiratory Frequency: 22 breaths per minute
Temperature: 36.5°C

She showed not a very good general condition, hypoventilation in both lungs, generalized sibilances were heard at chest auscultation. Crepitant rales in both lower lung lobes, predominantly on the left, a soft abdomen which did not hurt; there were few diarrheic depositions.

Parenteral hydration was reduced to 1L. a day.

Loperamide was suspended and enalapril was added due to high blood pressure readings 5mg. every 12hs. Besides, antibiotics were added to the treatment on an empirical basis: IV ampicillin plus sulbactam 1.5gr. every 6hs.

Lab tests findings:

WBC: 10900 cells/ml

Urea: 0.25 g/L

6th. Day at hospital – July 12th 2006

Blood Pressure: 150/90 mmHg
Temperature: 36°C

Respiratory System: Hypoventilation in both lungs, crepitant rales in both lung lower lobes, predominantly on the left, her abdomen did not hurt and she did not have any diarrheic depositions.

Lab Tests:

WBC Count: 11300 cells/ml

Neutrophils: 80%

Lymphocytes: 19%

Eosinophils: 0%

Monocytes: 1%

Basophils: 0%

Blood Glucose: 1,75 g/L

Urea: 0,24 g/L

Creatinine: 0,61 mg/dl

Total proteins: 7,56 g/dl

Albumin: 3,56 g/dl

Blood Cultures by two protocols(2) Negative 24 hs.

Sputum culture: Leukocytes more than 25 per field, epithelial cells less than 10 per field. Poly-morpho-nuclear leukocytes, gram-positive cocci in diplo and chains were seen. The streptococcus pneumoniae was identified.

Antibiogram sensitive to penicillins and derivates. BAAR: negative, not seen

7th. Day at hospital - 13th July 2006

Blood Pressure: 160/80 mmHg
Temperature: 36°C

The patient was a little better, she had less dyspnea, hypoventilation in both lungs, crepitant rales in the lower lobes, predominantly on the left.

8th Day at hospital – 14th July 2006

Blood Pressure: 160/80 mmHg
Temperature : 36,3°C

Respiratoy System: Generalized hypoventilation, crepitant rales in both lung lower lobes, predominantly on the left. Intravenous hydrocortisone and Prednisone Oral were prescribed – 40 mg a day; Enalapril was suspended and Amlopidine 10 mg. a day was prescribed.

9th. Day at hospital – July 15th. 2006

Blood pressure: 120/80 mmHg
Temperature: 36.5°C

Respiratory System: Generalized hypoventilation, crepitant rales in left lower lobe of the lung.

10th Day at hospital – July 16th. 2006

Blood pressure: 140/70 mmHg
Temperature: 36°C

The patient was not very well, there were no changes.

11th Day at hospital – July 17th. 2006

Blood pressure: 130/70 mmHg
Temperature: 36°C

Respiratory System: Crepitant rales were heard in lower lobes, predominantly on the left.

Lab blood tests:

WBC: 13000 cells/ml

Neutrophils: 53%

Limphocytes: 43%

Eosinophils: 4%

Monocytes: 2%

Basophils: 0%

Creatinine: 0,72 mg/dl
Glucose: 1,29 g/L
ESR: 35mm/1er H.
Hematocrits: 45%

Prednisone and a bronchodilator for nebulisation were suspended. Aerosol bronchodilators - salmeterol and fluticasone inhalers- were prescribed.

12th day at hospital – 18th July de 2006

Blood pressure: 130/80 mmHg
Temperature: 36.8°C

Crepitant rales in both lower lobes and fewer generalized sibilances were heard on auscultation.

Lab blood tests:

Urine sediment was received. The following was reported: abundant flat cells, leukocytes 4-6 per field and red blood cells 1 - 3 per field.

13th day at hospital – 19th. July 2006

Blood Pressure: 130/80 mmHg
Temperature: 36°C

Respiratory System: Crepitant rales were heard in both lower lobes and isolated sibilances.

14th Day at hospital 20th July 2006

Blood Pressure: 120/80 mmHg
Temperature: 36°C

Respiratory System: Few crepitant rales and isolated sibilances in both lower lobes were heard on auscultation.

Lab Blood Tests:

WBC: 6100 cells/ml
Neutrophils: 51%
Lymphocytes: 42%
Eosinophils: 5%
Basophils: 0%
Monocytes: 2%
Urea: 0,33 g/L
Blood Glucose: 1.58 g/L
Creatinine: 0.68 mg/dl

IV Antibiotics – ampicillin + sulbactam were suspended after 9 days of treatment. Oral antibiotics – amoxicillin + clavulanic, one tablet every 8 hours for 5 days and more, until 14 days of treatment were reached and

metformine 500 mg. at lunch and dinner. (It was not possible to get ampicillin + sulbactam in tablets)

The patient was discharged on July 21, 2006, after 14 days of hospitalization.

She presented with another definite diagnosis: Diabetes type II, which she had never suffered before getting the vaccine.

Comments:

This patient presented the diagnosis of "Prolonged Influenza" complicated with primary viral bilateral pneumonia, according to the signs and symptoms and antecedents of having received the anti-influenza vaccine in 2006 and bacterial bronchial secondary infection with pneumococcus, (*streptococcus pneumoniae*).

It is interesting to remark that the patient had never had pneumonia before and the asthmatic crisis was the longest and most intense in her life. She had these two complications after she received the anti-influenza vaccine for the first time.

The semiology of the viral pneumonia in both lower lung lobes, predominantly on the left, which in spite of the treatment with antibiotics for 10 days, did not improve quickly and lasted until the patient was discharged.

Besides, on July 17, 2006, after 7 days of treatment with antibiotics, she showed a leukocyte increase to 13000, without any other disease. This leads us to think of a viral component, as she did not improve her condition quickly. She was not given the antiviral Oseltamivir.

This is another case of prolonged Influenza complicated with primary viral bilateral pneumonia, one of the thousands of ill people affected by the anti-influenza vaccine, not diagnosed and not treated.

● Important: The fact that with this disease "Prolonged Influenza" and during hospitalization, she was diagnosed with Diabetes type II, that she had not suffered nor diagnosed before, calls for our attention. This is important because in several cases of prolonged influenza with complications, diabetes appears for the first time. With increased levels of amilasa and amilasuria.

It can be assumed that the onset of diabetes was due to one of these possibilities:
1- As a previous genetic consequence, the viral disease complicated with pneumonia would be the trigger that brought about diabetes, just as any other infectious disease or other pathologies.

2. The mutated influenza virus of prolonged Influenza would have a direct action on the pancreas, injuring it in such a way that diabetes has started, due to unknown mechanisms. In overall cases, there can be seen increased enzymatic levels of amilasa and amilasuria.

CLINICAL CASE N° 3

PROLONGED INFLUENZA

"Prolonged Influenza", complicated with primary viral bilateral pneumonia with renal disease and acute myocardial infarction.

The patient died after another acute myocardial infarction

(Pneumonia caused by the influenza virus from the anti-influenza vaccine)

CLINICAL HISTORY: YEAR 2006 (Hospitalized patient)

1) Personal information:

Gender/Sex: Female.

Age: 66 years old.

Address: Posadas.

Job: A housewife.

Nationality: Argentine.

2) Hospitalized patient:

Admission date: October 7, 2006 in the emergency room (Day 1).

October 8th. In the ward (Day 2).

Date of death during hospitalization: October 17, 2006.

3) Reason for coming to the surgery: Dyspnea and bad general condition.

4) Antecedents of this disease: A patient that had fallen ill 10 days before, with a fever, asthenia, adynamia, generalized arthromyalgias, shivering, sneezing and muco-serous rhinitis. Four days before hospitalization she had a cough with muco-serous expectoration, then muco-purulent expectoration, with back thorax pain (pleuritic type) worse on coughing and deep breathing. Besides, the patient reported type II-III dyspnea. The patient consulted a physician who prescribed antibiotics, amoxicillin tablets 875 mg. every 12 hours. In spite of the treatment, her condition did not improve, her dyspnea worsened to type IV, and this was the reason why she consulted her physician again. Besides, she presented oppressive retro-sternal pain with nausea and vomiting, 5 days before she was hospitalised.

5) Important antecedents: Diabetes type II for many years, with insulin therapy NPH 50 units a day.

Arterial hypertension diagnosed 10 years before, treated with enalapril 10mg. a day at the moment.

Amputation of right leg in 2004, due to an infected diabetic foot with altered blood flow.

She had been given the anti-influenza vaccine in May 2006, in a primary health care center. She fell ill 7 days after being given the vaccine and

presented the prolonged influenza condition. The acute period had lasted 30 days and she was not cured completely.

Afterwards she suffered relapses in July and August. In September she had the last relapse and that was the reason why she went to the hospital. She had never suffered from coronary heart disease or acute myocardial infarction. She had never presented bronchial asthma, bronchospasm, sibilance nor pneumonia.

She had never had chronic nor acute renal failure.

Genetic hereditary Antecedents: Her mother had died of diabetes, her brothers had arterial hypertension, there had not been any myocardial infarction pathologies in her family.

6) Physical examination: Patient in a bad general condition, type IV dyspnea, with orthopnea, Glasgow scale 15/15, with sibilance heard at a distance, using accessory muscles when breathing.

Arterial Tension: 130/90 mmHg

Heart rate: 90 bpm

Respiratory Frequency: 38 breaths per minute

Temperature: 36.8°C

Skin: Her left leg presented ochre dermatitis and her left foot fingers presented punctiform lesions, +/4 in her left leg and diminished superficial sensibility in her left foot.

Neck: Jugular ingurgitation of 2/3 with inspiratory collapse.

Respiratory system: Loss of expansion of bottom lobes and apex, important hypoventilation in both lungs, generalizad roncus and sibilance, crepitant rales in both lung bases, mainly the left one.

Cardiovascular System: Regular pulse, her femoral pulse was permeable and it was low in the back popliteal artery and in the left dorsalis pedis artery. A heart murmur was not auscultated. Cardiac noise was not heard properly due to added pulmonary noise.

Abdomen: Her abdomen was prominent, organomegalies were not detected.

Right leg: She presented a hypochromic leg stump with a 30 cm scar.

7) Diagnosis:

- 1- Viral bilateral pneumonia acquired from the influenza vaccine.
- 2- Severe acute respiratory insufficiency.
- 3- Respiratory viral disease relapse.
- 4- Complicated with a prolonged influenza relapse.
- 5- Diabetic foot.

Presumptive Diagnosis: Acute myocardial infarction.

Other Diagnosis:

- 1- Diabetes type II.
- 2- Arterial hypertension.

8) Complementary methods:

Chest x-rays: Congestive hilia, alveolar interstitial filtering in both bases

Electrocardiogram: Sinus rythm, heart frequency 90 bpm, left anterior hemiblock, complete right block in the right bundle branch, presence of QS waves in V1, V2 and V3 with ST elevation, with a high symmetric T wave in V2, V3 and V4, ST rectified in V6, ST of overcharge in DI and aVL, P wave in double hump (notched in leads DII, aVF, V2, V3, V5 y V6), dilated left auricle .

Definite diagnosis:

- 1- Primary viral bilateral pneumonia.
- 2- Acute myocardial infarction in evolution.

The diagnosis of viral bilateral pneumonia was based on the physical examination and a chest x-ray. The diagnosis of acute myocardial infarction was based on the physical examination and an electrocardiogram.

Lab Tests:

WBC Count: 14000 cells/ml

Glucose: 5.58 g/L

BUN: 1.25 g/L

Seric Ionogram: Na: 134.2 meq/L

K: 4.9 meq/L

CPK: 290 U/L

CPK mb: 17 U/L

GOT: 17 U/L

Platelet Count: 240000 cells/mm³

Blood Gas Test:

pH: 7.27

pCO₂: 44% mmHg.

pO₂: 59% mmHg.

Sat O₂: 86%

HCO₃: 19% mmol / l

Urine Sediment: Leukocytes 6-8 x field, gram-negative bacillus. A urinary infection (asymptomatic) was suspected.

Blood Gas Tests with low flow humid oxygen with mask:

pH: 7.41

pCO₂: 27% mmHg

pO₂: 152% mmHg

HCO₃: 17% mmol / l

Sat. O₂: 99%

Direct sputum for bacteriology was collected but it was an invalid sample (to be repeated).

A place in the Intensive Care Unit was requested, but it was denied as there were no available beds.

Blood tests, urine tests, sputum culture and an abdominal ultrasound tests were requested.

9) Treatment:

- 1- Hyposodic diabetic diet.
- 2- Semi recumbent position.
- 3- IV therapy one litre a day.
- 4- Low flow humid oxygen mask.
- 5- Ampicillin + sulbactam parenteral: 1.5gr. every 6 hours
- 6- Enalapril: oral administration 5 mg every 12 horas.
- 7- Hydrocortisone: parenteral 500mg. every 8 hours.
- 8- Sodium heparin 5000 units every 8 hours by subcutaneous injection.
- 9- Parenteral Aminophyllin.
- 10- Salbutamol administered by nebulization every 6 hours.
- 11- Glucose control and correction with insuline.
- 12- Respiratory physiotherapy.
- 13- Furosemide 40mg. every 12 hours, oral treatment.

3rd. Day in hospital 9th October 2006 (2nd day of antibiotic therapy -ATB)

Blood pressure: 150/90 mmHg

Temperature: 36.5°C

Glucose control by reagent strips 1,80 g/L.

Patient with a slight clinical improvement, with dyspnea, she showed sibilances and crepitant rales in both lower lobes of the lung.

Blood cultures. Not developed in 24 hs.

Abdominal ultrasound: kidneys with well-preserved size, well-preserved structure. Enlarged liver with well preserved structure; gall bladder, normal bile ducts, choledoc and pancreas had no special characteristics; the spleen had a preserved size and structure.

Lab Blood Tests:

WBC Count: 9900 cells/ml

Neutrophils: 98%

Lymphocytes: 2%

Monocytes: 0%

Eosinophils: 0%

Basophils: 0%

Hematocrits: 37%

Glucose in blood: 4.32 g/L

BUN: 1.30 g/L

Creatinin: 2.97 mg/dl

E.S.R: 105mm/1st H.

Platelet count: 266000 cells/mm³

CPK: 1499 U/L

LDH: 742 U/L

GOT: 28 U/L

Cholesterol: 282 mg/dl

HDL Cholesterol: 35 mg/dl

LDL Cholesterol LDL: 187 mg/dl

Triglycerides: 386 mg/dl

Serology: chagas not reactive

Ionogram: Na: 136 meq/L

K: 3,9 meq/L

Cl: 108 meq/L

The diagnosis of acute myocardial infarction was confirmed by the lab tests of high CPK y LDH enzymes.

Parenteral hydration was reduced to 500 cc a day, the aminophilin was suspended, oral teophilin 200 mg. every 12 hours.

Comments:

In view of the high levels of creatinine, **an acute renal failure** was diagnosed. It was a consequence of her diabetes, arterial high blood pressure or a renal vasculitis brought about by the anti-influenza vaccine, or by the contribution of all these factors.

4th. Day in hospital - 10 October 2006 (3rd day of atb.)

Arterial Blood Pressure: 140/90 mmHg

Temperature: 37°C

Glucose control with reagent strips 2.50 g/L.

Her respiratory condition was better. There were fewer rhonchi in both lower lobes, less sibilances especially in the right lung; there were still crepitant rales in both lower lobes.

Lab Blood Tests:

Uroculture:

Microorganism characterization: bacteria of the KES group.

Antibiogram: Sensitive to aminopenicillin + sulbactam, trimetroprime + sulfamethoxazole, resistant to ciprofloxacin and nitrofurantoin.

Ketonuria: negative

CPK: 996 U/L

LDH: 878 U/L

GOT: 16 U/L

Comments:

The treatment with ampicillin + sulbactam was started, due to the bacteria characterization of KES group in the urine culture.

In view of enzyme increase and the curve for acute myocardial infarction, plus the typical physical signs and symptoms seen on the days before

hospitalization , the diagnosis of anteroseptal myocardial infarction in evolution was confirmed.

Electrocardiogram: There were some changes from the day before (October 9, 2006):
Higher negative T in DI and aVL.
Higher overload of left ventricle, the voltage of T waves in V1-V2-V3, y V4 decreased. Slight ST segment depression in V4 -V5-V6: possible ischemia.

The ECG was not performed because the electrocardiograph was out of order.

Treatment: oral amiodarona 200mg. was added to reduce the heart rate.
Oral isosorbide mononitrate 10mg. every 12 hours, to improve the preload and due to suspicion of ischemia as a consequence of the ST segment depression in leads V4 -V5 -V6.
Oral clopidogrel 75mg. a day, as a platelet antiaggregation therapy.
Oral ranitidina 300mg. as a gastric protector.

5th Day in hospital - 11 October 2006 (4th Day of atb.)

Arterial blood pressure: 130/60 mmHg
Respiratory frequency: 23 breaths per minute
Temperature: 37°C
Glucose control with reagent strips 2,5 g/L

The patient was recovering from her respiratory insufficiency, there were fewer sibilances in her right lung, there were crepitant rales in both lower lobes.

Lab Blood Tests:

Increased (positive) Troponin T 0,499 (normal values 0.000 – 0.010)
T. Prothrombin ratio: 61%
Partial Thromboplastin Time: 44"
Platelet count: 231000 cells/mm³

Comments: The positive Troponin T certifies even better the diagnosis of anteroseptal myocardial acute infarction in progress. The treatment with an intravenous anticoagulation drug was decided, due to the type of myocardial acute infarction and suspicion of ischemia, clopidogrel and subcutaneous sodium heparin were stopped. Anticoagulation was started with Partial Thromboplastin Time controls every 6 hours.

6th Day in hospital - October 12, 2006 (5th day of atb.)

Arterial blood pressure: 150/90 mmHg
Heart rate: 57 bpm
Respiratory Frequency: 17 breaths
Temperature: 36.8°C
Glucose control with reagent strips: 3 g/L.

The patient's condition was not very good, she had a better respiratory pattern, she tolerated the supine position, sibilance was heard in both lungs, she still had crepitant rales in both lung bases.

Lab Test: Partial Thromboplastin Time: 110"

Treatment: Parental hydrocortisone was stopped, oral prednisone was added, 20mg a day, and amiodaron was stopped due to heart rate of 57 beats per minute.

7th Day of hospitalization - 13 October 2006 (6th day of atb.)

Arterial blood pressure: 140/90 mmHg
Heart rate: 58 bpm
Respiratory Frequency: 20 breaths per minute
Temperature: 36.8°C

She continued with the same respiratory pattern, isolated sibilances, persistence of crepitant rales in both lung bases.

Lab Tests:

Glucose: 4,26 g/L
Partial Thromboplastin Time: higher 180".

Treatment: Intravenous anticoagulation treatment was suspended.

8th Day in hospital - 14 October 2006 (7th day of atb.)

Blood pressure: 130/80 mmHg
Heart Rate: 70 beats per minute
Temperature: 37°C

Her general condition was better; she was improving, she moved well in bed, she was lucid, collaborative, there were neither sibilances nor rhonchi,

The crepitant rales in both bases of the lung persisted in spite of the treatment.

Lab Tests:

Partial Thromboplastin Time: 53"

Electrocardiogram: The heart rate was 80 beats per minute, there were isolated supraventricular extrasystoles. There was a lower voltage of the T wave in V₁- V₂- V₃ y V₄ and a greater depression of the ST segment in V₄.

The possibility of performing a cardiac catheterization with coronary angiogram due to ischemic post M I was evaluated, but it did not take place due to lack of funds.

Treatment: Oral dicumarinics and haematology control. Amiodarone 200mg. a day again.

9th Day in hospital -15th October 2006 (8th day ATB)

Arterial Pressure: 100/70 mmHg
Temperature: 36.5°C

The patient's general condition was the same, there were no characteristic changes. She was lucid and collaborative.

Lab Test:

Partial Thromboplastin Test: 56".

10th Day of Hospitalization - 16th October 2006 (9th day ATB)

Arterial blood pressure: 60/40 mmHg
Heart Rate: 90 beats per minute
Temperature: 36.3°C
Glucose control with reagent strips 3,31 g/L

Her condition was very bad, she continued with crepitant rales in both lower lobes of the lung, arterial hypotension 60/40 mmHg, heart rate 90 beats per minute, altered sensory conditions, unilateral mydriasis (a neurological focus) was found.

A stroke was suspected (hemorrhagic or ischemic).

A transfer to an intensive care unit was requested, but there were no beds available, so the patient continued in the common ward.

Oral anticoagulation treatment was suspended, K vitamin was injected, she still received this treatment: amiodarone, ampicillin + sulbactam, ranitidine, nebulizations with salbutamol, humid low flow O2 húmedo and IV hydration. A vesical and nasogastric catheterization was performed for a better control; hematuric urine was present; dopamine therapy began. A CT scan was requested

Electrocardiogram: Sinus rhythm, heart rate 100 bpm, there was a greater ST segment depression in V3- V4- V5 and V6, ischemic type, compatible with acute anterolateral subendocardic ischemia (where there is an R wave), frequent supraventricular extrasystoles, at some moments they were bigeminated.

Lab Blood Tests:

Hematocrits: 20%
Hemoglobin: 6,2 g/dl
Glucose: 3,31 g/L
Urea: 0,48 g/L
Prothrombin T: 31%
RIN: 2,33
Ionogram: Na: 133 meq/L
K: 2,93 meq/L

Cl: 105 meq/L
Platelet count: 178000 mm³

The patient showed a normal anti-coagulation control.

11th day in hospital 17th October 2006 (10th day ATB)

Arterial blood pressure: 70/50 mmHg
Temperature: 36.3°C

Her condition was still bad with sensory alteration, Glasgow 3/15, type IV dyspnea, with crepitant rales in both lower lobes and sibilances.

Abdomen: It was soft, depressible, no pain when pressed, positive diuresis with a vesical catheter, no hematuria, nasogastrical catheter, no bleeding, positive catharsis, no bleeding.
There were no signs of a hemorrhage when the patient was examined.

A head CT scan was requested again.

Lab Tests:

E.S.R.: 140mm 1st H.
Glucose in blood: 2.33 g/L
Urea: 1.53 g/L
Creatinine: 4.59 mg/dl
CPK: 3.919 U/L
LDH: 910 U/L
GOT: 25 U/L
P.C.R. test: Positive (++++)
Ionogram: Na: 133.9 meq/L
 K: 3,07 meq/L
 Cl: 105 meq/L

Electrocardiogram: ST depression in D1, with a greater ST depression in V4-V5 y V6, ST disappearance in V3, with frequent supraventricular extrasystoles, at some moments bigeminated, and isolated ventricular extrasystoles.

Comments: The patient was in a very bad condition. There was sensory deterioration. She presented with the same ECG alterations of ischemia as she had done the previous day -16 Oct 2006. She had an increase in the cardiac enzymes CPK and LDH. **Another AMI** was confirmed - non Q-wave, anterolateral, or subendocardial.

The patient was on humid oxygen, constant low flux. The transfer to the intensive care unit was requested again, and denied.

**At 5 p.m. the patient had a cardiac arrest. She was reanimated but did not recover and she died at 5.30 p.m.
The patient was not treated with the antiviral Oseltamivir.**

Comments on day 11 of hospitalization – 17 October 2006:

The patient suffered from a viral bilateral pneumonia which was not cured. She also suffered an AMI in evolution and a stroke – a neurological complication, diagnosed by the sensory alteration and unilateral midriasis, which could be related to a complication of the anticoagulant treatment.

But with the increase in the cardiac enzymes and important ischemic changes in the ECG of the day before (16 October 2006), another AMI on the anterior lateral face (with a positive (++++) P.C.R. test results) was considered. This could have generated intracavitary thrombi and embolized 80% of the brain and produced an ischemic stroke, which as a consequence of the anticoagulation treatment could have turned hemorrhagic.

The CT scan could not be performed.

Final Comment:

The patient, who having received the anti-influenza vaccine in May 2006 at a public primary health center, presented with prolonged influenza 7 days later. The acute stage lasted 30 days and it was not completely cured. She suffered 3 relapses in the following months. At the end of September she had the last extremely severe relapse which complicated with primary viral bilateral pneumonia (from the influenza virus of the vaccine) and severe respiratory insufficiency. She was hospitalized, she presented with bronchospasm, which she had never suffered before, and an AMI which had started to develop 5 days before she was hospitalized.

She also had an acute renal disease, which could have been vasculitis or vascularitis occasioned by the anti-influenza vaccine, or her diabetes or arterial high blood pressure.

Bacterial infections were not found in the blood cultures, nor in the sputum culture, so it is deduced that the pneumonia had a viral origin, and also after 11 days of treatment with antibiotics her respiratory semiology had not improved; crepitant rales and sibilance –bronchospasm- persisted. She presented with a second AMI (showed by the ECG and the cardiac enzymes) and stroke, which caused her death.

It could have also been a vasculitis in the brain, as an effect of the anti-influenza vaccine and its inflammatory action on the brain blood vessels, which could have produced the stroke.

These complications produced by the anti-influenza vaccine have to be noticed. They have been described in this book, and in the reports sent to the Health Ministry of the Argentine Republic.

This is one of the hundreds of thousand of people affected who have died, who have not been diagnosed and who have not been specifically treated, with fatal consequences.

CLINICAL CASE N° 4

PROLONGED INFLUENZA

Year 2007. "Prolonged Influenza", complicated with primary viral bilateral Pneumonia and acute atrial fibrillation

(Pneumonia caused by the influenza virus from the anti-influenza vaccine)

She had the anti-influenza vaccine in 2006 and 2007. Later she had "Prolonged Influenza" complicated with pneumonia both times

CLINICAL HISTORY: YEAR 2007 (Hospitalized patient)

1) Personal information:

Sex: Female

Age: 61

Address: Cuña Pirú- Misiones

Job: A housewife

Nationality: Argentine

2) Hospitalized patient:

Date of hospitalization: July 13th 2007.

Date of discharge: July 18th 2007.

3) Reason for coming to the hospital: Dyspnea and chest pain.

Transferred from the hemodialysis service.

4) Antecedents of the disease: It began seven days before with mucoserous rhinitis, asthenia, adynamia, arthromyalgia, irritative cough, then she had mucoserous expectoration, no changes in its color. After 5 days, she had an oppressive pain in both hemithoraxes, not irradiated, which increased when coughing. She also had type I-II dyspnea, she felt hot, she was feverish, had chills, profuse sweating and palpitations. She visited her physician, who prescribed amoxicillin. She did not remember which dose she had taken, but her condition did not improve. She consulted a doctor at the hemodialysis service, who decided to hospitalize her.

5) Important antecedents: Arterial hypertension for several years.

Chronic renal insufficiency diagnosed 12 years before, dialysis 3 times a week.

- She was given the anti-influenza vaccine in April 2007. A fortnight later she had a viral upper-and-lower-tract viral infection which lasted for 20 days. She rested in bed for 15 days but was not cured completely. She was ill for two months and a half, had three successive relapses which did not improve. The third relapse brought about this disease, which complicated with pneumonia and required hospitalization.

- It can be inferred then that the respiratory viral disease that brought about this disease is not an isolated event. It was a relapse of the prolonged

influenza suffered in April and successive relapses complicated with pneumonia.

- In 2006 she got the anti-influenza vaccine and some days later she had a viral respiratory disease that lasted two months and a half, which complicated with hemoptysis and pneumonia, which required hospitalization.

This was the second time she received the anti-influenza vaccine (2007). She fell ill with the same symptoms and complicated with pneumonia as it had happened in 2006.

Low digestive hemorrhage 3 years before, which was cured.

With a history of leucopaenia and plateletpenia, which had not had a clear etiology several years before.

She had had hepatitis 8 years before.

Hip fracture years before, repaired with surgery.

She had never had the anti-influenza vaccine.

She had never had pneumonia.

She had never had this prolonged viral respiratory disease with relapses.

6) Physical examination:

Blood Pressure: 80/60 mmHg

Heart Rate: 90 x' beats per minute

Respiratory Frequency: 18 breaths per minute

Temperature: 36.5°C

Lucid patient, Glasgow 15/15, normal gait.

Skin: Cutaneous-mucous paleness. Dermatitis in bottom left leg.

Subcutaneous cellular tissue: An edema was palpated in the same leg up to the middle third, which was hard and cold.

Respiratory system: Crepitant rales were heard in both lower bases of the lung. Generalised decrease of air intake with inspiration.

Cardiovascular system: Murmurs were not heard, variable heart sounds.
Pulse: irregular, uneven heart rate.

7) Diagnose:

1- Bilateral Pneumonia.

2- Acute auricular fibrillation.

3- Relapsed respiratory viral syndrome.

4- Relapsed and prolonged viral respiratory disease. "Prolonged Influenza".

5- Circulatory and trophic alterations in left leg.

Other diagnoses:

- 1- Chronic renal insufficiency, with hemodialysis.
- 2- Blood arterial hipertension.

8) Complementary methods:

Chest R-x: Alveolar interstitial filtering in both bases of the lung, predominantly in the right lung and in the middle third of the right hemithorax. Hilar congestion. (See fig. 1)

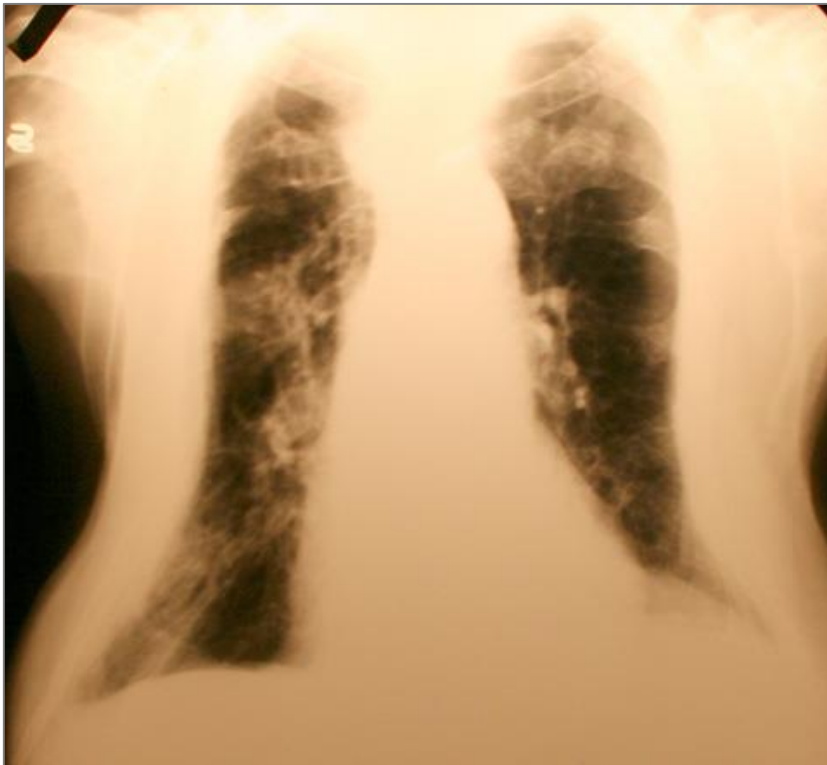

Fig.1: Date: 13 July 07

ECG: Irregular rhythm, heart frequency 90 x', isolated ventricular extrasystoles.

Lab Tests:

Hematocrits: 38%
Leukocytes: 3900 cells/ml
Hemoglobine: 12.3 g/dl
Platelet Count: 65000 cells/ml

9) Definite diagnosis:

- 1- Primary viral bilateral Pneumonia.
- 2- Acute atrial fibrillation.
- 3- Relapsed viral respiratory syndrome.
- 4- Relapsed Prolonged Influenza complicated with Pneumonia.

10) Treatment:

- 1- Low-in-sodium renal diet.
- 2- Low flow humid oxygen mask.
- 3- Calcium: 2 tablets at lunch and dinner.
- 4- Nebulizations with saline solution every 8 hours.

2nd Hospitalization 14 July 2007 (1st day on antibiotics)

Arterial blood pressure: 90/60 mmHg
Temperature: 36.5°C

The patient was in a not good general condition, lucid, well placed in time and space, she did not have a fever.

Respiratory system: Crepitant rales were heard in both bottom lobes as well as a generalised decrease in the air intake.

Aparato cardiovascular: Normo-phonetic first and second sounds were heard. Murmurs were not audible.
Heart beats: regular, the same.
The patient spontaneously reverted the atrial fibrillation to sinus rhythm.

Treatment: The treatment with antibiotics was started, intravenous ampicillin + sulbactan 1,5gr. every 6hs. oral clarithromycin 500mg. every 12hs. And intravenous dextrose solution 5%, 500cc. a day.

A blood culture was started in the lab.

Lab Tests:

Leukocytes: 3700 cells/ml
Protrombin Test: 85%
Platelet Count: 74000 cells/ml
Ionogram: Na: 133.6 meq/L
K: 3,84 meq/L
Cl: 94,1 meq/L

3rd Day of Hospitalization 15th. July 2007 (2nd day on antibiotics)

Blood Pressure: 90/60 mmHg
Temperature : 36.5°C

The patient was lucid, collaborative, she did not have a fever, there were no changes.

4th Day of Hospitalization 16th. July 2007 (3rd. day on antibiotics)

Blood Pressure: 110/60 mmHg
Temperature: 36.3°C

The patient was lucid, collaborative, she did not have a fever.

Respiratory system: Crepitant rales were heard in both lower lobes and there was a generalized air intake.

Cardiovascular system: Normo-phonetic first and second sounds were heard. Murmurs were not audible.
Heart beats: regular, the same.

Chest X-rays were taken as a control, alveolar interstitial infiltrates were decreasing in both lower lobes, and in the middle third of the right hemithorax. See Fig.2

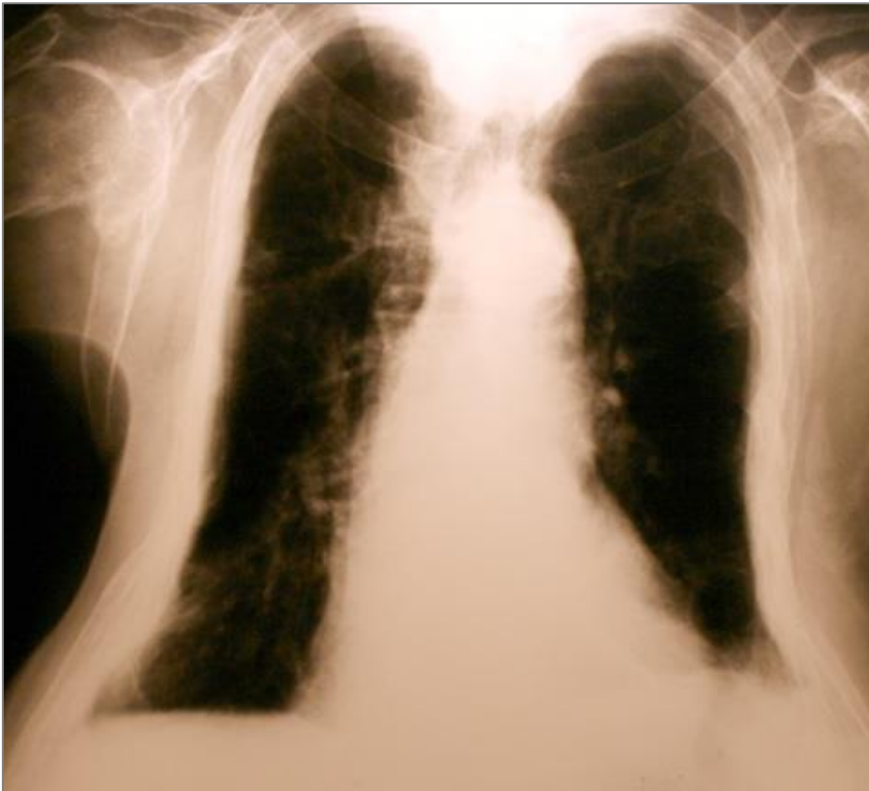

Fig.2: Date: 16/07/07

Lab Tests:

Hematocrits: 38%

Leukocytes: 3600 cells/ml

Platelet count: 95000 cells/ml

Blood Cultures did not show a bacterial development.

5th Day of Hospitalization 17th. July 2007 (4th. Day on antibiotics)

Blood pressure: 120/70 mmHg

Temperature: 36.2°C

The patient was lucid, collaborative, afebrile, she walked normally.

Respiratory System: Crepitant rales were heard in both bottom lobes and there was a generalized air intake.

Cardiovascular system: Normo-phonetic first and second sounds were heard. Murmurs were not audible.
Heart beats: regular, the same.

Chest X-rays were taken as a control. She still had a sinus rhythm with no changes.

Lab Tests:

Hematocrits: 34%
Leukocytes: 3600 cells/ml
Neutrophils: 54%
Lymphocytes: 42%
Eosinophils: 2%
Monocytes: 2%
Basophils: 0%
Platelet count: 86000 cells/ml
C-Reactive Protein Test: Positive (++)
Glucose in blood: 0.86 g/L
Urea: 1.26 g/L
Creatinine: 6,46 mg/dl
GOT: 12 U/L
GPT: 11 U/L
Alkaline Phosphatase: 355 U/L
Total cholesterol: 152 mg/dl
Protrombine Test: 72%
Total proteins: 7.72 g/dl
Albumin: 3.48 g/dl
Ionogram: Na: 132.9 meq/L
 K: 4.59 meq/L
 Cl: 98 meq/L
Phosphorus: 280 mg/dl

Bacteriology: Sputum: Direct examination, leukocytes more than 25 in each field.
Examination with color: mixed pleomorphic flora, no predominant organisms.

Comments: Even though leukocytes did not change during hospitalization, a decrease in platelets, which had been 65000 cells/ml, at the end 86000 cells/ml, showed a mild disease in platelets together with this prolonged viral respiratory disease, in spite of the fact that the patient had a leukopenia without an etiologic diagnosis.

6th Day of Hospitalization 18th July 2007 (5th day on antibiotics)

The patient was discharged because her condition was better. Antibiotic treatment continued until 10 days had passed.

The patient was not treated with the antiviral Oseltamivir.

Comments:

This patient who was on chronic renal insufficiency hemodialysis treatment, received the anti-influenza vaccine in 2006 and again, in April 2007. Some

days later she presented with upper and lower tract respiratory viral infection. The disease lasted 20 days, she stayed in bed for 15 days, but it was not cured. During the following two months and a half, she had two relapses with the same symptoms, but less intense; some days later she presented with the same relapse, the same symptoms, which brought about her present condition. It was complicated with

1- Primary viral bilateral pneumonia and 2- Supraventricular tachyarrhythmia, acute atrial fibrillation.

These diseases require hospitalization and are life-threatening.

It was the second time she received the anti-influenza vaccine and she presented with the same prolonged respiratory infectious disease, with complications.

● She received the anti-influenza vaccine in 2006 and presented with the same prolonged upper and lower tract respiratory viral infectious disease, with relapses, presenting with hemoptysis for two months. It complicated with life-threatening viral pneumonia that required hospitalization.

● **She received the vaccine in 2006-2007, and both times she presented with the same prolonged respiratory infectious disease, with relapses, complicated with primary viral pneumonia.**

She had never received the anti-influenza vaccine before.

She seldom fell ill with flu, and if she did, it was mild and short.

After receiving the vaccine in 2006, she presented with prolonged signs and symptoms which complicated with pneumonia.

She was ill for the second time in 2007, after receiving the vaccine and she presented with pneumonia.

She had never suffered from pneumonia before.

The patient was sure that it was the vaccine that made her ill. She said that she would never receive it again.

She knows whole families that were vaccinated and had a very long severe influenza, as she did.

● Two years after having received the vaccine, she presented with the same disease, and the same respiratory complications that she had never suffered before. Besides, she had hemotypsis and acute atrial fibrillation.

● This shows and reasserts once again the relationship between the anti-influenza vaccine and the onset of this "Prolonged Influenza" disease, with life-threatening complications.

● This case is a proof of the **clinical diagnosis and epidemiological diagnosis and the cause-effect relationship** that produces the anti-

influenza vaccine, generating a respiratory disease similar to influenza, but more severe and prolonged, that I call "Prolonged Influenza".

This is another case of the thousands of patients made ill by the anti-influenza disease, life-threatening and with severe complications, which are not treated specifically. Even in 2006, 2007 until 2013, the alerts reported 17 years before have not been taken into consideration, with the consequence of thousands of sick and dead people.

CLINICAL CASE N° 5

PROLONGED INFLUENZA

Prolonged influenza complicated with definitive arterial hyperpressure

CLINICAL HISTORY: YEAR 2007 (out patient)

1) Personal information:

Sex/gender: female

Age: 47

Address: Posadas

Job: A housewife

Nationality: Argentine

2) Visit to the doctor's office: July 30, 2007

3) Reasons for coming to the doctor's office: Cough, rhinitis, sneezing and nuchal pain.

4) Antecedents of the present disease: The patient presented with cough, rhinitis, sneezing and back headache. She had these symptoms for two months and a half until the visit to the doctor.

Symptoms started and continued persistently after she had received the anti-influenza vaccine on 8 May 2007 at 12 am. She sneezed convulsively several times in a row for two days. Fever was higher than 38° for a few days. Very intense asthenia. Generalized intense arthromyalgia. Abundant mucoserous rhinitis that turned to mucopurulent. Severe headache mainly in the frontal region and in all the head. Pain in the right ear. Photophobia. Intensely sore throat. Hot dry mouth. Severe persistent irritative cough. No expectoration. Difficulty in walking. Leg pain for seven days. Back ache. She also felt pain in the region where she had received the vaccine for 12 days. The patient stayed in bed for 6 days because she felt poorly. She was prescribed anti-inflammatory drugs, antitussives and anti-fever drugs, but she was not cured.

The acute condition lasted 15 days approximately. She experienced some consequences: coughing, rhinitis, frequent sneezing in cold weather and nuchal pain.

The frontal pain and the headache disappeared a fortnight later, but the nuchal pain persisted. One month later hypertension was diagnosed, which she had never suffered before. Her persistent nuchal pain was related to hypertension. From normal 100/80 mmHg arterial pressure that she had before taking the vaccine, she presented with 150/100 mmHg persistently. She had definitive arterial hypertension and nuchal pain.

It was the first time she was vaccinated and became ill in such a prolonged intense way, as never before. When she had the flu before, it had lasted two or three days and she had never had to lie down.

Her mother had been vaccinated for the first time in 2006 and three days later she had had a severe bout of flu with the same viral respiratory condition. She had been hospitalized and she decided never to have the vaccine again as she made the vaccine responsible for her prolonged disease.

5) Other important antecedents: The patient was healthy and she did not have any previous disease.

It was the first time she had been vaccinated against the influenza

6) Physical examination: The patient was lucid, she did not have fever, she was well placed in time and space.

Arterial blood pressure: 150/100 mmHg

Heart rate: 70 bpm

Respiratory System: There was a good bilateral entrance of air, no added lung sounds.

Cardiovascular System: No heart murmurs.

Comments: After two months and a fortnight and several consequences, the slightly decreased prolonged influenza symptoms persisted, with cough, rhinitis, sneezing, nuchal pain and persisten arterial hipertensión.

7) Diagnosis:

1) Prolonged Influenza complicated with definitive arterial hyperpressure.

8) Treatment:

1- The patient was prescribed antiviral Oseltamivir 75mg. every 12hs. For five days. 48 hs. later she was given corticoids, Fast and slow action dexametasone, one IM amp.

9) Progression of the disease:

La paciente mejora en 48hs. un 60% y en seis días el 100% de todos los síntomas respiratorios. Llamativamente el dolor de nuca y la hipertensión arterial desaparecieron totalmente durante el tratamiento, normalizándose

la presión arterial durante 10 días a 100/70 mm.Hg. Pero luego reapareció la hipertensión arterial en forma definitiva con mayores cifras tensionales de 180/100 - 150/100mm.Hg. y reaparece conjuntamente el dolor de nuca, necesitando ser tratada con antihipertensivo en forma definitiva.

10) Comments:

This fast answer to the antiviral treatment with Oseltamivir shows and reaffirms once again that this disease is produced by a live influenza virus, a new type of virus, which the antiviral Oseltamivir succeeds in healing, but there are consequences of arterial hyperpressure.

This shows how an effective applied treatment, with good fast answer to the antiviral treatment reaffirms once again the diagnosis of viral origin of the disease "Prolonged Influenza" that comes from the anti-influenza vaccine.

This is another case of a correct diagnosis and its antiviral specific treatment, where the patient was cured very quickly but there remained consequences of definitive arterial hyperpressure.

But there are still hundreds of thousands of patients that have not been diagnosed or treated, who have been affected by the anti-influenza vaccine, presenting with the life threatening disease "Prolonged Influenza" with complications.

It is a pity that in 2013 still there are still thousands of people who become ill and die, affected by this disease Prolonged Influenza and by the anti-influenza vaccine, although the health authorities were warned 17 years ago.

CLINICAL CASE N° 6

"PROLONGED INFLUENZA"

"Prolonged influenza" complicated with viral bilateral pneumonia, acute myocardial infarction, acute auricular fibrillation, post A.M.I ischemia, acute-chronic kidney failure.
Patient died due to staphylococcus sepsis.

(Pneumonia caused by the influenza virus from the anti-influenza vaccine)

The patient had been hospitalized three times:

CLINICAL HISTORY: FIRST ADMISSION TO HOSPITAL: 2006

1) Personal information:

Gender: Female

Age: 70 years old

Address: Encarnacion – Paraguay

Occupation: A housewife
Nationality: Paraguayan

2) Hospitalization:

Date: 19th October 2006
Discharge date: 31st October 2006

3) Reason for consultation:

Asthenia. Poor general condition.

4) Background of the present disease:

One month before the consultation, the patient had asthenia, adynamia, arthromyalgia, rhinitis with mucous secretion, cough with white expectoration, type II and III dyspnea, paroxysmal nocturnal dyspnea and edema in her lower limbs. For all these reasons, the patient was hospitalized in Encarnacion, Paraguay. She was diagnosed with pneumonia. She was treated with antibiotics (first treatment) for a week but her clinical manifestations did not improve. What is more, the following week, she had fever, chills and chest pain. She went back to the doctor who diagnosed her with pneumonia once again. For the second time she was treated with antibiotics. She improved a little but was not completely cured and the clinical manifestations persisted.

Three days before her hospitalization, the patient presented symptoms of dysuria and pollakiuria. Two days after her hospitalization she presented hemoptoic expectoration, fever and dyspnea progression (getting to class IV). Due to these reasons, she was hospitalized in Posadas, Misiones.

5) Important background:

The patient had been diagnosed with pulmonary tuberculosis 30 years before. However, she had been completely cured after the treatment. She was also diagnosed with high blood pressure 4 years ago.

- The patient got the influenza vaccine on 10th October 2006. Five days after that, she presented with viral, intense and prolonged manifestations in the respiratory system. The most severe stage lasted 20 days approximately. She did not heal completely and consequently during the next 5 months, she presented with 4 exacerbations (one each month). The last relapse was complicated with pneumonia one month before hospitalization. She was diagnosed pneumonia and twice she was prescribed antibiotics, but her condition did not improved. Her clinical manifestations persisted and the prolonged viral respiratory infection too. It did not heal, which caused the present disease, "Prolonged influenza with complications", and her hospitalization.

6) Physical examination:

The patient was in a poor condition, dyspnea at rest, semi-sitting position, Glasgow coma scale 15/15, at some moments she felt disoriented in time and space.

Arterial blood pressure: 120/50 mmHg
Cardiac frequency: 92 bpm

Respiratory frequency: 18 breaths per minute
Temperature: 36° C
Weight: 67,200 Kg
Height: 1,50 mtrs.

Infrapatellar edema in both legs (four crosses). 2/3 Jugular ingurgitation with respiratory collapse.

Cardiovascular system: normal pulse rate. Arterial tension 120/50 mmHg. No heart murmur or hypo-phonetic noises were auscultated.
In the respiratory system, there were subcrepitan rales in both lower lung fields, Predominantly in the right lung.

7) Diagnosis:

- 1- Bilateral pneumonia
- 2- Respiratory failure
- 3- Viral respiratory infection, prolonged and exacerbated
- 4- "Prolonged influenza"

Possible diagnosis:

- 1- Kidney failure
- 2- Urinary tract infection

Other diagnosis:

- 1- High blood pressure
- 2- Consequences of cured tuberculosis

8) Treatment

- 1- Hyposodic diet
- 2- Low-flow humid oxygen
- 3- Hydric restriction
- 4- IV infusion with 5% dextrose, 500cc a day
- 5- Enalapril 10 mg a day
- 6- Furosemide 40 mg every twelve hours.

9) Complementary methods :

Echocardiogram – 25th September 2006. Septal myocardial hypertrophy with a normal left ventricle septolic function. She had a mild diastolic dysfunction, aortic and mitral valve, mild pulmonary fibrosis, normal left auricle, ejection fraction 73%.

Laboratory tests -13th October 2006

Leukocytes: 13100 cells/ ml
Neutrophils: 90%
Lymphocytes: 20%
Eosinophils: 0%
Basophils: 0%
Monocytes: 0%
Hematocrits: 39%
Hemoglobin: 12.60 g/dl

Laboratory tests -19th October 2006

Leukocytes: 13300 cells/ml
Neutrophils: 92%
Lymphocytes: 8%
Eosinophils: 0%
Basophils: 0%
Monocytes: 0%
Glucose: 1.04 g/L
Urea: 1.66 g/L

Urine sediment: scarce flat epithelial cells. Leukocytes, 7-8 per field. Red blood cell count, 100 per field. Plenty of granular casts.

Studies made on 19th October 2006

Abdominal ultrasound: normal, excepting the left kidney pwerenchyma with a rise of echogenicity.

Chest X-ray: interstitial infiltrates in the right lung base. In the upper third of the left hemithorax, it presented a fibrotic lung image due to tuberculosis.

Electrocardiogram: sinus rythm, cardiac frequency 90 bpm, left anterior hemiblock, negative T-wave in aVL.

10) Final diagnosis:

1- Primary viral bilateral pneumonia with interstitial and alveolar infiltrates according to the physical examination and chest x-ray. Facing the diagnosis of primary viral bilateral pneumonia and "prolonged influenza", a treatment with the antiviral Oseltamivir was suggested but was not carried out. Hemocultures, urocultures and laboratoty were requested.

Important commentary: for the third time in a month, the patient was diagnosed with pneumonia. The third treatment with antibiotics was started since the exacerbation of the disease a month ago. She had never had any renal pathologies before.

2nd day of hospitalization. 20th October 2006 (1st day of antibiotics)

Arterial blood pressure: 140/80 mmHg.
Temperature: 36° C
Weight: 66.800 Kg.
Patient in poor conditions, unspecified precordial pain, sub-crepitant rales in both lung bases and third half of right hemithorax; fist percussion: painless lumbar and ureteral points.

Laboratory tests

Leukocytes: 16000 cells/ml
Hematocrit: 36%
Uroculture: negative for habitual germs at 24 h; PH: 6, presence of hemoglobin (+++).

Blood gases
pH: 7,29
pCO₂: 26% mmHg.
pO₂: 76% mmHg.
HCO₃: 12% mm.ol/l
Sat. O₂: 94%
Glucose: 0.94 g/L
E.S.R.: 135 mm. / 1st H
Prothrombin time: 76%
Urea: 2,10 g/L
Creatinine: 8, 24 mg/dl
Total cholesterol: 172 mg/dl
LDL: 107 U/L
HDL: 33 U/L
Triglycerids: 159 mg/dl

Commentary: with a diagnosis of renal insufficiency not yet well established, an acute renal failure was suspected.

Added to the treatment:

- 1- Diltiazem 300 mg. a day (for hypertrophic cardiomyopathy)
- 2- Ampicillin + sulbactam 1,5 g. every 12 hours. This antibiotic was added in prevention of a bacterial bronchial secondary infection. The 12 h-dose was justified on the renal insufficiency.
- 3- Nebulizations with salbutamol and ipratropium bromide.

3rd day of hospitalization. 21st October 2006 (2nd day of antibiotics)

Patient in poor conditions, very asthenic, type IV dyspnea, crepitant rales in the base of the right hemithorax and sub-crepitant rales in the left base of the hemithorax.

Interconsultation with a nephrology specialist was needed, hemodialysis was required.

•**Diagnosis of acute renal failure was confirmed.**

Electrocardiogram: the negative T wave disappeared in aVL.

Echocardiogram: moderate pericardial hemorrhage, septal hypertrophy of the left ventricle, normal systolic function.

4th day of hospitalization. 22nd October 2006 (3rd day of antibiotics)

Arterial blood pressure: 120/70 mmHg.
Temperature: 36^o C

Patient in a poor condition in all aspects. A cannula was introduced in the left jugular and she was taken to hemodialysis. Her condition improved after the first session.

•Negative hemocultures

5th day of hospitalization. 23rd October 2006 (4th day of antibiotics)

Arterial blood pressure: 110/70 mmHg.

Temperature: 36° C

The patient was in poor condition. She got up and walked around. Crepitant rales in the base of the right hemithorax, sub-crepitant rales in the left base of the hemithorax. She was on a three-month-hemodialysis schedule. Despite the hemodialysis, the crepitant and sub-crepitant rales persisted.

Laboratory tests:

Leukocytes: 13800 cells/ml

Band neutrophils: 1%

Segmented Neutrophils: 89%

Lymphocytes: 2%

Eosinophils: 2%

Hematocrit: 31%

Platelet count: 155000 cells/ml

E.S.R.: 60 mm/1st H

Glucose: 0.65 g/L

Urea: 2.55 g/L

Creatinine: 12 mg/dl

Albumin: 2,58 g/dl

P.C.R: positive (++++)

C.P.K: 66 U/L

L.D.H: 741 U/L

G.O.T: 19 U/L

Alkaline phosphatase: 335 U/L

Direct bilirubin: 0.34 mg/dl

Indirect bilirubin: 0.52 mg/dl

Ionogram: Na: 132 meq/L

K: 6.4 meq/L

Cl: 101 meq/L

Serologies:

Chagas: non reactive

H.I.V: non reactive

Anti hepatitis C: non reactive

Hepatitis B surface antigen: non reactive

Note: the hematocrits decreased from 39% and 12.60% g/dl of hemoglobin, to 31%. This happened in a period of 6 days without hemorrhage.

- After 4 days of antibiotics, the patient still had 13800 mm³ leukocytosis, 1% band neutrophils, and 89% segmented neutrophils.

6th day of hospitalization. 24th October 2006 (5th day of antibiotics)

Arterial blood pressure: 120/70 mmHg.

Temperature: 36.7° C

Patient in poor condition in all aspects. Crepitant rales in both bases, predominantly in the right lung.

7th day of hospitalization. 25th October 2006 (6th day of antibiotics)

Arterial blood pressure: 140/90 mmHg.

Temperature: 36.5° C

The patient presented sub-crepitant rales in both lung bases.

Treatment: the dose of diltiazem was increased to 60 mg. every 8 hours.

8th day of hospitalization. 26th October 2006 (7th day of antibiotics)

Arterial blood pressure: 130/70 mm. Hg.

Temperature: 36,6° C

The patient presented crepitant and sub-crepitant rales in the base of the right hemithorax.

She had a sore throat but she could not describe it. She was lost in time and occasionally disoriented in space.

She had her hemodialysis session done.

Laboratory tests:

Calcemia: 8.16 mg/dl

Phosphatemia: 8.88 mg/dl

Leukocytes: 33700 cells/ml

Neutrophils: 76 %

Lymphocytes: 21 %

Monocytes: 2 %

Eosinophils: 1%

Hematocrit: 34%

Hemoglobin: 9.6 g/dl

Platelet count: 480000 cells/ml

Prothrombin time: 68%

Urine sediment: hematuria, fields covered with red blood cells.

Comments: in spite of hemodialysis and a 7-day treatment with antibiotics, the patient did not improve her respiratory semiology and the leukocytosis rose to 33700 cells/ml.

A troponin T test, cardiac enzymes and echocardiogram were requested.

9th day of hospitalization. 27th October 2006 (8th day of antibiotics)

Arterial blood pressure: 110/70 mm. Hg.

Temperature: 36,5° C

Weight: 65 Kg.

The patient still suffered from a sore throat, she had new symptoms of nausea, vomiting, tachycardia and irregular pulse.

The patient still presented crepitant rales in the base of the right hemithorax and sub-crepitant rales in the base of the left hemithorax.

Electrocardiogram: *acute supraventricular* tachyarrhythmias. It was an acute auricular fibrillation with a cardiac frequency of 150 per minute and a high ventricular response.

Laboratory Tests:

Ionogram: Na: 133 meq/L
K: 6.28 meq/L
Cl: 107 meq/L
Creatinine clearance: 4.68 ml/min.
Positive troponin T: 0.017
CPK: 15 U/L
GOT: 19 U/L
LDH: 835 U/L
Urea: 1.91 g/L
Creatinine: 10.60 mg/dl

Echocardiogram: there was no pericardial effusion. Normal motility and systolic function. Septal hypertrophy. (The echocardiography equipment had limitations to evaluate the parietal motility)

Note: the pericardial effusion disappeared after the hemodialysis.

Comments: an acute myocardial infarction was diagnosed because of the sore throat, nausea, vomiting, acute auricular fibrillation, positive troponin T test, like a non-Q infarction with acute auricular fibrillation. (first A.M.I, unstable angina?)

The transfer to the intensive care unit was requested. There was no bed available.

Treatment: amiodarone 450 mg. perorally in one hour. Then, 750 mg. for maintenance during the following 24 hours. Aspirin 250 mg. a day and renitidine 150 mg. a day.

Due to the amiodarone load, the auricular fibrillation reverted to a sinus rhythm -90 bpm- in two hours.

Electrocardiogram: changes of the ST segment, rectified in D_I, and segment depression and negative T in aVL.

10th day of hospitalization. 28th October 2006 (9th day of antibiotic)

Arterial blood pressure: 100/60 mmHg.
Temperature: 36.8° C
Weight: 65.800 Kg.

The patient had hemodialysis sessions and lost weight (63.800 kg). She still presented with crepitant rales in the base of the right hemithorax and sub-crepitant rales in the base of the left hemithorax. She had a normal pulse.

Commentary: in spite of the hemodialysis, the loss of weight -from 67.200 kg. at the beginning to 63,800 kg. - and the decrease of liquids and negative balance, crepitant rales persisted in the base of the right

hemithorax and there were sub-crepitant rales in the base of the left hemithorax.

This meant that if the diagnosis of viral bilateral pneumonia was reaffirmed, it was not a consequence of fluid-filled lungs, renal insufficiency or cardiac problems. See fig.1

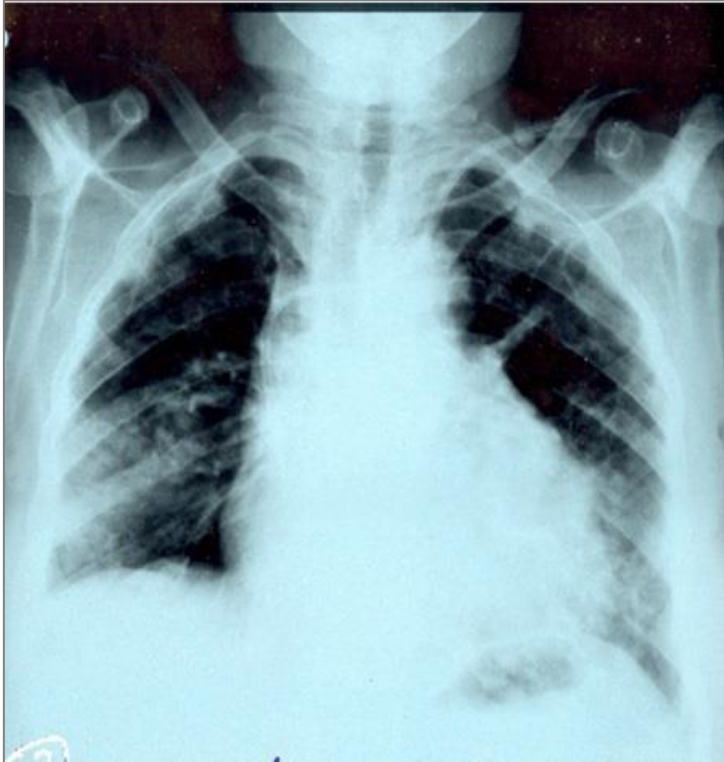

Fig 1. **Viral bilateral pneumonia:** Note bilateral interstitial and alveolar infiltrates in both lower lung fields and middle lobes. Secular fibrosis in upper third of left hemithorax. Cannula (double lumen) in left subclavian vein (October 28, 2006).

Electrocardiogram: a sinus rhythm with cardiac frequency 90 x'. No changes were observed comparing to the previous day.

Treatment: she kept taking amiodarone 200 mg a day. Oral route.

11th day of hospitalization. 29th October 2006 (10th day of antibiotic)

Arterial blood pressure: 120/60 mmHg.

Temperature: 36.2° C

The patient did not improve the pulmonary pathology in spite of the 10 days of antibiotic treatment. She was in fair condition.

12th day of hospitalization. 30th October 2006 (11th day of antibiotic)

Arterial blood pressure: 110/80 mmHg.

Temperature: 36.6° C

Weight: 64.500 Kg.

Patient in fair condition. Her respiratory semiology did not improve. She still had crepitant rales in the base of the right hemithorax.

Laboratory tests:

Ionogram: Na: 134,8 meq/L
K: 6,68 meq/L
Cl: 102 meq/L
Leukocytes: 22100 cells/ml
Neutrophils: 95 %
Lymphocytes: 5 %
E.S.R.: 140 mm/1st H
Hematocrit: 26%
Platelet count: 294000 cells/ml
Prothrombin time: 71%
Partial thromboplastin time: 31"
Glucose: 0.70 g/L
Urea: 1.37 g/L
Creatinine: 7.87 mg/dl
Creatinine clearance: 6.38 ml/min.
Calcemia: 8.16 mg/dl
Phosphatemia: 5.82 mg/dl
Albumin: 2.86 g/dl

*Despite the fact that there were no reasons that explained it, the hematocrits decreased from 39% at the beginning to 26% without haemorrhages.

Treatment: a tablet of calcium via oral route. Diltiazem was suspended.

Commentary: diltiazem was stopped because an acute myocardial infarction was interpreted. The calcium blockers may worsen the diagnosis and the cardiac frequency may fall. The amioradone may also help to lessen the cardiac frequency.

The leukocyte count was high (22.100 mm³) with an E.S.R. of 140 mm in the 1st H. Crepitant rales persisted in the base of the right hemithorax. Despite the 11 days of antibiotics, the pneumonia pursued upholding the existence of a viral pneumonia that could not be cured with antibiotics. The state of the patient got complicated with an acute myocardial infarction.

13th day of hospitalization. 31st October 2006 (12th day of antibiotic)

Arterial blood pressure: 120/70 mmHg.
Temperature: 36° C

Laboratory tests:

CPK: 21 U/L
GOT: 222 U/L
LDH: 609 U/L

The patient was discharged with ambulatory treatment.

SECOND ADMISSION -24 hours later

Date: November 1st 2006

After hemodialysis, the patient suffered a hemodynamic decompensation. She was in poor general condition and presented the following symptoms: low blood pressure, palpitations, precordial pain, profuse perspiration, sphincter relaxation and diarrhea.

For all these symptoms, which lasted for hours, the patient consulted the doctor and was hospitalized again.

Physical examination:

Arterial blood pressure: 80/50 mmHg.

Cardiac frequency: 100x'

Respiratory frequency: 24 x'

Temperature: 36° C

Weight: 64 Kg.

A patient in poor general condition and with sensory depression.

Skin and subcutaneous tissue: generalized cutaneous-mucous paleness, bilateral infrapatellar edema ++.

Respiratory apparatus: crepitant rales and scarce sibilances were auscultated on the base of the right lung.

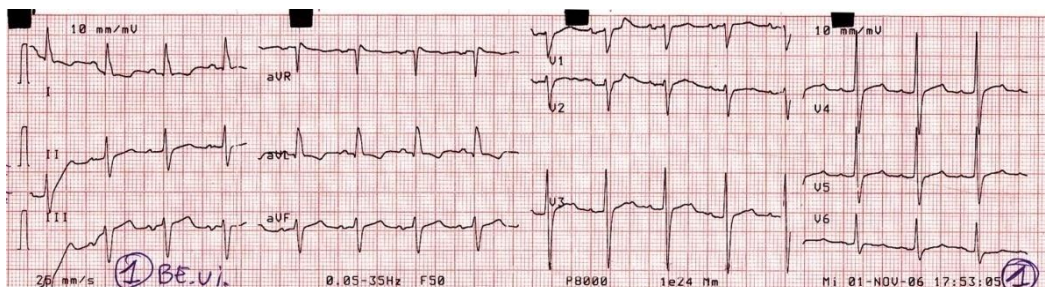
Cardiovascular apparatus: a fourth noise was auscultated.

Complementary methods:

Chest X-ray: positive result, opacity in right costophrenic angle.

Electrocardiogram: sinus rhythm with cardiac frequency 100 x'. Left anterior hemiblock, ST segment depression and negative T wave in D₁ and aVL. Voltage decrease of the T-wave in V₂, V₃, V₄, V₅, V₆. Bimodal T-wave in V₃.

See Electrocardiogram 1.



Electrocardiogram 1: alterations in the repolarization can be observed in derivations V₁-V₂-V₃-V₄-V₅-V₆ as well as in D₁ and aVL. (not mapped patient) (Date 11/1st/2006)

Laboratory tests:

Leukocytes: 20400 mm³

Urea: 1.37 g/L

CPK: 18 U/L

Ionogram: Na: 134 meq/L K: 4,28 meq/L Cl: 103 meq/L

Rehospitalization diagnosis:

1. Acute myocardial infarction.
2. Persistent viral pneumonia in right lower lobe.
3. Diarrhea syndrome
4. Renal insufficiency

The patient was in poor condition and had sensory depression.

Laboratory tests tests were requested, cardiac enzymes, Troponin-T, electrocardiogram, hemoculture, uroculture and retro culture.

Treatment:

1. Hyposodic and kidney protection diet.
2. Amioradone 200 mg per day.
3. A tablet of calcium every 12 hours –at lunch and dinner time.
4. Nebulization with Salbutamol, every 6 hours.
5. Venoclysis 500 cm³ per day.
6. Weight and diuresis control.

2nd day of rehospitalization. November 2nd, 2006. 1st day of antibiotics. (total days: 15)

Arterial blood pressure: 110/60 mmHg

Cardiac frequency: 90 bpm

Respiratory frequency: 24 breaths per minute.

Temperature: 36^o C

The patient was in poor general condition. Her face showed she was in pain. Hypotension. Generalized arthralgia and precordial pain. Crepitant rales were auscultated in the right base of the lung. A fourth cardiac noise was auscultated as well.

Echocardiogram: septal hypertrophy of the left ventricle. Normal motility and ventricular function.

(Motility might not have been appraisable since the equipment had limitations to give an acute determination)

Laboratory Tests

Leukocytes: 24600 cells/ml

Neutrophils: 99 %

Lymphocytes: 1 %

Monocytes: 0 %

Eosinophils: 0%

Basophils: 0%

E.S.R.: 140 mm/1st H

P.C.R: positive (++++)

Hematocrits: 24%

Hemoglobin: 6,6 g/dl

CPK: 893 U/L

GOT: 15 U/L
LDH: 500 U/L
Urea: 1,21 g/L
Creatinine: 7.24 mg/dl
Albumin: 2.58 g/dl
Total proteins: 5.44 g/dl
Platelet count: 200000
Prothrombin: 65%

Comments: the non-Q wave acute myocardial infarction diagnosis was confirmed by clinical manifestations and high CPK and LDH enzymes.

It is interpreted that the acute myocardial infarction, which had not showed changes in enzymes before, had finished. However, clinical manifestations and positive troponin T. levels sustained the diagnosis. Once again, leukocytes increased to 24600 cells/ml and hematocrits kept going down to 24 % without clinical evidence of hemorrhage.

Coproculture: direct examination. Less than five leukocytes per field, normal quantity of mucus. No parasites were observed. She presented germinated yeasts.

Uroculture: less than five leukocytes per field. Fields covered by hematids. Pyocytes were not observed. Scarce quantity of cells.

Hemoculture: usual germs without development within 24 hours. This was the second negative hemoculture. In the first hospitalization, the result had been negative as well.

Electrocardiogram: no changes compared to the previous day.

Treatment: new antibiotics were prescribed, vancomycin 1gr every 5 days after dialysis, and ciprofloxacin 200 mg every 12 hours.

Comments: this is the fourth treatment with different antibiotics not usually used for persistent pneumonia. This pneumonia had been 45 days under treatment without healing.

3rd day of rehospitalization. November 3rd, 2006. 2nd day of antibiotics. (total days: 16)

Arterial blood pressure: 100/60 mmHg.
Temperature: 36.5° C
Weight: 63 Kg.

The patient makes reference to painful deglutition and generalized arthralgia, no diarrhea.

Cardiovascular apparatus: a fourth noise was auscultated.

Respiratory apparatus: crepitant rales at the right base of hemithorax.

Due to the presence of hematuria, an interconsultation with a urologist was required.

Laboratory Tests:

Positive troponin T: 0.092
CPK: 20 U/L
LDH: 628 U/L
GOT: 11 U/L

Electrocardiogram: Bimodal T-wave in V₂. slight ST elevation in V₂, V₃, V₄, V₅, and V₆.

- **Diagnosis: the acute myocardial infarction diagnosis was confirmed** by clinical signs and symptoms, typical enzymatic curve and positive troponin T. The electrocardiogram did not show necrosis in a clear way, but an acute non Q-wave myocardial infarction was interpreted.
- This was the first acute myocardial infarction that took place in these two hospitalizations. It is understood that the acute myocardial infarction that happened previously was completed by now.

Treatment: *atenolol* 12,5 mg p/day, anxiolytic (*alprazolam* 0.5 mg. every 12 hours), and *sodium heparin* 5.000 units every 12 hours -subcutaneous- were added to the treatment.

4th day of rehospitalization. November 4th, 2006. 3rd day of antibiotics. (total days: 17)

Arterial blood pressure: 110/60 mmHg.
Temperature: 37^o C
A fourth cardiac noise was still auscultated, crepitant rales on right and left base of the lungs.

Laboratory tests:

CPK: 10 U/L
LDH: 304 U/L
Coproculture: without development of germs.

Hemoculture: without development.

This is the third hemoculture without development within the period of both hospitalizations (17 days).

Electrocardiogram: with a frequency of 64 bpm. ST depression disappeared as well as the T-wave in D_I, though it persists in aVL, there was a marked decrease of ST elevation in V₂, V₃, V₄, V₅ and V₆. Bimodal T-wave in V₂ disappeared.

A unit of packed red blood cells was transfused.

A cardiac catheterization was requested. A coronary angiography was requested as well but it was not done for economic reasons.

5th day of rehospitalization. November 5th, 2006. 4th day of antibiotics. (total days: 18)

Arterial blood pressure: 110/70 mmHg.
Temperature: 36.5^o C
Patient in poor general condition. No fever. No improvement.

Electrocardiogram: the same as the previous day.

Same treatment.

6th day of rehospitalization. November 6th, 2006. 5th day of antibiotics. (total days: 19)

Arterial blood pressure: 100/60 mmHg.
Cardiac frequency: 60 bpm
Respiratory frequency: 20 breaths per minute
Temperature: 36.2° C

The patient was in normal general conditions, very drowsy. The fourth cardiac noise was not auscultated any longer. Crepitant rales at the base of the right lung and subcrepitant rales at the left base.

Electrocardiogram: the same as the previous day with 60 bpm of frequency.

Laboratory tests:

Ionogram: Na: 129.5 meq/L
K: 4.19 meq/L
Cl: 97 meq/L
Leukocytes: 7.800 mm³
Neutrophils: 97 %
Lymphocytes: 3 %
Eritrosedimentation: 140 mm/1st H
CPK: 216 U/L
GOT: 18 U/L
LDH: 389 U/L
Glucose: 0.69 g/L
Urea: 1.09 g/L
Creatinine: 5.91 mg/dl
Calcaemia: 6.68 mg/dl
Phosphatemia: 6.33 mg/dl
Platelet count: 264000
Hematocrit: 25%
Hemoglobin: 6.7 g/dl
Creatinine clearance: 9.22 ml/min.

Comments: once more, there was a rise of CPK and LDH cardiac enzymes without precordial pain.

7th day of rehospitalization. November 7th, 2006. 6th day of antibiotics. (total days: 20)

Arterial blood pressure: 110/80 mmHg.
Temperature: 36.2° C

Patient in normal general conditions. She ate little and walked around little too. Increase of crepitant rales at the base and mid-third of the right lung.

Laboratory tests:

Coproculture: no development of germs within 24 hours.

A second transfusion of red blood cells was performed.

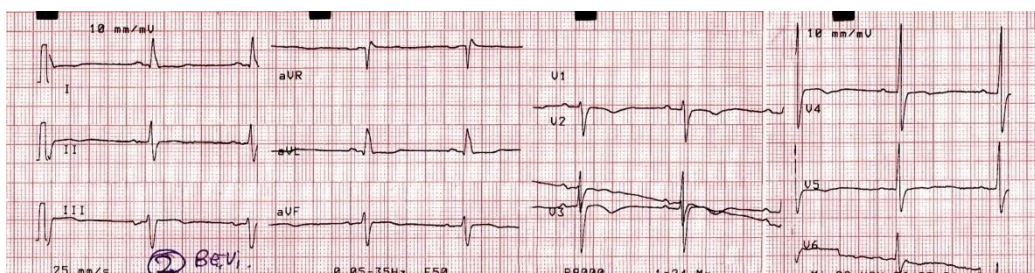
8th day of rehospitalization. November 8th, 2006. 7th day of antibiotics. (total days: 21)

Arterial blood pressure: 110/60 mmHg.

Temperature: 36° C

Patient in normal general conditions, asthenic, subcrepitant rales in both bases of lungs. Diuresis 400 cc per day.

Electrocardiogram: cardiac frequency 60 bpm. ST segment depression and negative T in DI and aVL disappeared. There were changes of negative T repolarization in V₁, V₂, V₃ and V₄ with voltage decrease in the other derivations. See Electrocardiogram 2



ELECTROCARDIOGRAM 2: See ischemic changes in negative T waves in V₁ – V₂ – V₃ – V₄ and rectified ST in DI and aVL. There is also an alteration in the repolarization in DII, DIII, aVF and V₅-V₆ with flat-to-negative T wave. There are AMI signs, a troponin and cardiac enzymes elevation, with a typical curve, confirming the diagnosis of AMI (mapped patient) (Date 8 November 2006)

Laboratory tests:

CPK: 15 U/L

LDH: 440 U/L

GOT: 19 U/L

Again, an acute myocardial infarction type T (not Q) was interpreted. This was due to the typical elevation of enzymes and electrocardiographic alterations. There was no precordial pain.

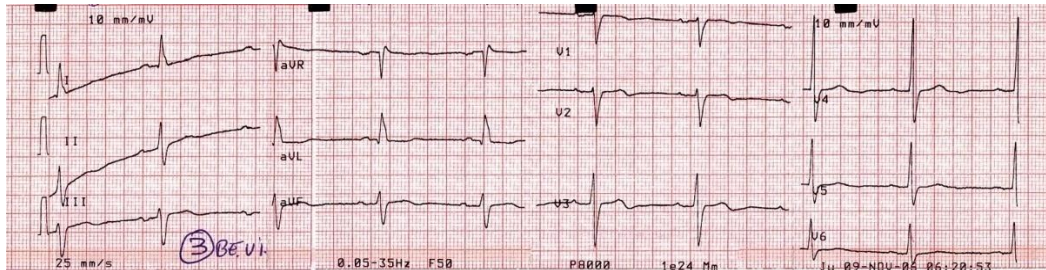
Because of hematuria, a cystoscopy was requested.

9th day of rehospitalization. November 9th, 2006. 8th day of antibiotics. (total days: 22)

Arterial blood pressure: 110/60 mmHg.
Temperature: 37.6° C

Patient in poor general condition. Crepitant rales were auscultated in both bases and mid thirds of the lungs.

Electrocardiogram: cardiac frequency 58 bpm. Negative T wave still present in V₁, V₂, V₃ and V₄. See Electrocardiogram 3.



Electrocardiogram 3: persistent ischemic changes in V₁ -V₂ -V₃ -V₄ (mapped patient) can be observed - (Date 11/9th/2006)

Comments: once again with the typical cardiac enzymes elevation and the curve of an acute myocardial infarction. This was the second time it had happened. There was an elevation of CPK to 216 and LDH to 440. There were changes in the electrocardiogram, septal wall ischemia and prior ischemia, type T (or non Q) acute myocardial infarction.

This was the second acute myocardial infarction

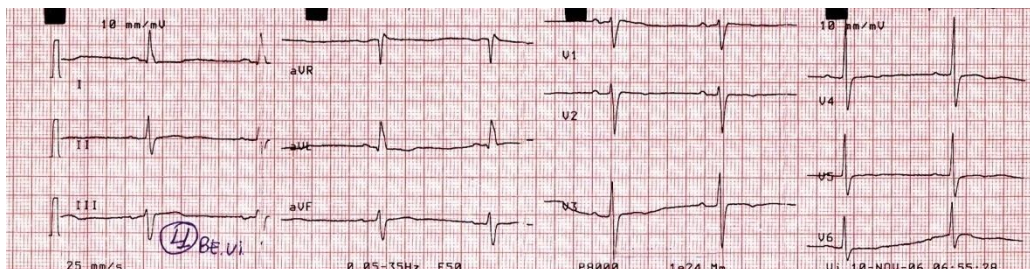
Another acute myocardial infarction was diagnosed (reinfarction), probable, with ischemia post-AMI. For this reason, an hemodynamic analysis was requested as well as a catheterism. Eventually an angioplasty and stent collocation would also be needed.

For an immediate intervention, the Ministry of Public Health was notified with the purpose of becoming aware of the case, to help the patient and study the adverse effects that the influenza vaccine produce.

10th day of rehospitalization. November 10th, 2006. 9th day of antibiotics. (total days: 23)

Arterial blood pressure: 140/60 mmHg.
Temperature: 37.6° C

Patient in poor general condition. The crepitant rales in both bases and mid thirds of the lungs were persistent.



ELECTROCARDIOGRAM 4: Note ischemic changes in V₁-V₂-V₃-V₄ and an elevation of the ST segment in V₁, showing symptoms of a persistent post-A.M.I. ischemia. (mapped patient). (Date 10 November 2006)

The hemodynamic analysis could not be done due to economic reasons.

Laboratory tests:

CPK: 15 U/L

LDH: 469 U/L

GOT: 13 U/L

P.C.R: positive (++++)

Ionogram: Na: 133.7 meq/L

K: 4.5 meq/L

Cl: 103 meq/L

Cystoscopy: the bladder had congested mucosa and a little hemorrhagic spot which did not alter the bladder wall.

11th day of rehospitalization. November 11th, 2006. 10th day of antibiotics. (total days: 24)

Arterial blood pressure: 110/80 mmHg.

Respiratory frequency: 20 bpm

Temperature: 36.5° C

Patient in normal general conditions, asthenic. She tolerated food. Crepitant rales were auscultated in the base and mid third of the right lung and in the base of the left lung.

Commentary: positive P.C.R (++++) indicated a persistent inflammation. Pulmonary semiology of crepitant rales in both lungs indicated a persistent pneumonia which did not heal after 10 days of antibiotics in the second hospitalization. Additional to the 12 days in the first hospitalization, 22 days of treatment with antibiotics had passed. However, her pneumonia did not heal.

12th day of rehospitalization. October 12th, 2006. 11th day of antibiotics. (total days: 25)

Arterial blood pressure: 130/80 mmHg.

Temperature: 37.4° C

Patient in same conditions.

13th day of rehospitalization. October 13th, 2006. 12th day of antibiotics. (total days: 26)

Arterial blood pressure: 120/70 mmHg.

Temperature: 37° C

Generalized pruritus at night time, crepitant rales at base of right base and mid-third and subcrepitant rales at the base of the left lung.

Electrocardiogram: negative T wave persisted in V₁, V₂, V₃ and V₄. Cardiac frequency: 60 bpm.

Laboratory tests:

Leukocytes: 9300 cells/ml
Neutrophils: 80 %
Lymphocytes: 20 %
E.S.R.: 140 mm/1st H
CPK: 201 U/L
GOT: 19 U/L
Alkaline phosphatase: 247 U/L
GPT: 14 U/L
P.C.R: positive (+)
Hematocrit: 27%
Hemoglobin: 7.7 g/dl
Platelet count: 312000
Prothrombin: 78%
Glucose: 0.75 g/L
Urea: 1.09 g/L
Creatinine: 5.80 mg/dl
Calcaemia: 6.57 mg/dl
Phosphatemia: 5.51 mg/dl
Total proteins: 5.43 g/dl
Albumin: 2.55 g/dl
Cholesterol: 143 mg/dl

Commentary: the E.S.R. was still high (140 mm/1st H). Respiratory semiology: crepitant and subcrepitant rales in the lower lobes that did not cease.

Cardiac enzymes increase for the third time, this indicated a new necrosis and a slight acute myocardial infarction.

14th day of rehospitalization. October 14th, 2006. 13th day of antibiotics. (total days: 27)

Arterial blood pressure: 100/60 mmHg.

Temperature: 36.5° C

There were still crepitant rales in the right lower lobe and subcrepitant rales on the left lobe.

Diuresis 350 cc

15th day of rehospitalization. October 15th, 2006. 14th day of antibiotics. (total days: 28)

Arterial blood pressure: 110/60 mmHg.

Temperature: 36.5° C

Weight: 64 Kg.

The patient was in normal general conditions. She is asthenic although she could still tolerate food. Crepitant rales in the right lower lobe and subcrepitant rales in the left lobe.

Electrocardiogram: synus rhythm, cardiac frequency 60 bpm. Alterations in repolarization with positive T wave in V₁, V₂, V₃, V₄ and V₅. Bimodal.

Laboratory tests:

Ionogram: Na: 139 meq/L
K: 3.46 meq/L

CPK: 240 U/L

P.C.R: positive (++++)

Prothrombin time: 77%

Partial thromboplastin time: 31 ' '

Total proteins: 6,.98 g/dl

Albumin: 2.63 g/dl

There was still an elevation of cardiac enzymes CPK: 240 U/L, and positive (++++) P.C.R.

Commentary: the elevation of CPK enzymes was interpreted as a slight acute myocardial infarction (the third one). According to the electrocardiographic changes from V₁ to V₅, an ischemia post MI was also interpreted.

16th day of rehospitalization. October 16th, 2006. 15th day of antibiotics. (total days: 29)

Relatives of the patient requested a discharge and she was transferred to Buenos Aires by ambulance. They were aware of the risks she ran once she was taken out of the hospital.

While discharged, I prescribed two tablets of Oseltamivir at the beginning, and one a day in the following 10 days as an independent physician -(due to renal insufficiency). **Within the following 48 to 72 hours the patient improved conditions. Asthenia disappeared. Sensory and respiratory symptomatology improved. She got over her viral pneumonia, the ischemic cardiopathy got stabilized and the function of her kidneys improved as well. She recovered up to a 90% in ten days of treatment.**

After her recovery, the patient asserted that she did not remember anything about the hospitalization time. Only after the 10-days treatment with Oseltamivir she came round and felt more alert. She said she felt like she used to be (normal). Thorough sensory improvement. There was a possible diagnosis of encephalitis. Four days later, she visited a hospital in Buenos Aires, but doctors found her well and did not justify a hospitalization or immediate dialysis. After a week of ambulatory assistance and evaluation, she started her hemodialysis plan again.

On November 17th 2006, the clinical history was abducted from the hospital. This was reported to the police and the court.

After 17 days, the clinical history reappeared out of the blue.

A kidney ultrasound done in Buenos Aires on 20th November 2006 showed the following: both kidneys with increased cortical echogenicity; both normal in shape and size. Non-dilated excretory tract.

Right kidney: 114 mm.

Left kidney: 124 mm.

A Doppler echocardiogram done in Buenos Aires on 12th December provided the following information: normal systolic function, normal auricular and

ventricular cavities, slight aortic disease, slight mitral regurgitation, septal hypertrophy.

Commentary: this 70-year-old patient who was vaccinated for the first time on May 10th 2006, presented with symptoms of prolonged influenza after an incubation period of 5 days. The acute period lasted 20 days. After 5 months, she was not cured. She suffered four relapses. The worst relapse, which was the last one, occurred in September and presented more severe symptoms. A pneumonia was diagnosed at the time as a complication in the clinical manifestations. The pneumonia was treated with antibiotics; however, the patient did not get over it completely. In the following month, she suffered from another pneumonia which again was treated with antibiotics and once more, she did not get over it completely. Therefore, after a consultation, the affected person was hospitalized. Her diagnosis was bilateral pneumonia and respiratory insufficiency.

In total, the patient was in hospital for 29 days; that is, the first hospitalization plus the second one. In this period she presented respiratory semiology like persistent crepitant and subcrepitant rales in the lower lobes of both lungs. Leukocytes rose to 33.700 mm³; they were more predominant than neutrophils. Also, there was a persistent inflammatory reaction showed by the ESR 140 mm/1st H - and the positive P.C.R (++++). Despite the patient's poor condition, no bacterial infection was detected in any of the three hemocultures done in different times of both hospitalizations.

In spite of having been treated with antibiotics twice –the first time with ampicillin and sulbactam for 11 days and the second time with vancomycin and ciprofloxacin for 15 days- she neither healed nor improved. All these suggest the presence of a primary viral bilateral pneumonia.

In September, October and November, the patient presented four pneumonias in total, which were treated with four different antibiotic treatments; however, they were not cured. This fact indicated the **seriousness of the persistent viral pneumonia during these continuous months**. Not to mention that the relapses affected the patient and the antibiotics did not help.

- We can notice then, that there was only one primary viral bilateral pneumonia that persisted along three continuous months and not four separate ones. It had a higher or lower degree of severity in its relapses. It did not heal with antibiotics but it improved rapidly with Oseltamivir antiviral and cured in 10 days –without antibiotics.

She had two acute myocardial infarctions and a third slighter one with a post-AMI ischemia.

- The acute myocardial infarctions happened consecutively and the fact that they did not produce Q-wave showing necrosis could be due to mechanisms of arterial inflammation of vasculitis or vascularitis in the myocardium. This generated different degrees of ischemia and necrosis, with their different clinical manifestations: non-Q infarctions, post-MI ischemia with more or less severe symptoms, which make it more difficult for a diagnosis. That

was why a very strict clinical monitoring with an electrocardiogram, cardiac enzymes, troponin "T" and other complementary methods were required. The persistent positive P.C.R (++++) also indicated that the arterial vascular system could have been affected as well as the respiratory system by the persistent pneumonia.

During the hospital admission, the patient presented acute renal failure which evolved to be chronic. (She had never had this problem before).

- This renal insufficiency cannot be explained by four years of hypertension. In this case, the acute renal failure could have been the product of an inflammation of the blood vessels, vasculitis or vascularitis in the kidneys. At the same time, this vasculitis was the product of the influenza vaccine. In fact, the transitory affections of the kidneys have been reported as an adverse effect. Nevertheless, what has not been reported is that it is through this mechanism that the severe kidney disease like the acute renal failure and then the chronic renal insufficiency is produced and there are serious consequences. This relationship between the influenza vaccine and the transitory renal failure or the acute renal failure which leads to chronic renal failure is very frequently observed.

Complications:

1. Persistent primary viral bilateral pneumonia
2. Prolonged viral respiratory disease. "Prolonged influenza".
3. Two acute myocardial infarctions with ischemia post infarction and the possibility of a third A.M.I.
4. Acute renal insufficiency followed by a permanent chronic renal insufficiency.
5. Persistent inflammatory syndrome.
6. Possible encephalitis.

These were typical complications of the "Prolonged Influenza" that this patient suffered after being vaccinated with the influenza vaccine in 2006. Unfortunately, she could not get the treatment with Oseltamivir antivirus during the hospitalization. This would have improved the patient's conditions before and it would have reduced or avoided successive complications and serious life risks.

This woman was another patient affected by the influenza vaccine. She suffered "Prolonged influenza" with serious complications like pulmonary, cardiac and kidney complications that put her life in risk. She did not have an accurate diagnosis, neither a specific treatment.

Out of thousands of affected people in the world, this is one of the unlucky cases of prolonged influenza. It was not diagnosed or treated adequately, thus it endangered life.

THIRD ADMISSION:

CLINICAL HISTORY:

1) Personal information:

Sex: female

Age: 70 years old.

Address: Encarnacion, Paraguay
Occupation: A housewife
Nationality: Paraguayan

2) Hospitalization:

Admission date: 5th February 2007
Date of demise: 8th February 2007

3) Reason for consultation: fever and asthenia.

4) Antecedent of the present disease: fever, asthenia, adynamy, generalized pruritus, that had started approximately 48 hours before consultation; then chills, profuse sweating, pain at doble-lumen cannula level that she had suffered for 24 hours. Her condition was poor. After the consultation she was hospitalized. Once in hospital, the patient had diarrhoea and yellow stools, without blood.

5) Important antecedent: the patient was affected by the flu vaccine in 2006. Thus, she suffered "Prolonged influenza" during six months and a half which got complicated with pulmonary, cardiac and renal affections. This is a primary viral bilateral pneumonia which persisted for two months and a half and presented ischemic cardiomyopathy, two acute myocardial infarctions with ischemia post A.M.I, acute renal failure that required hemodialysis and then became chronic. Hemodialysis three-times per week began in October 2006.

After the second admission (rehospitalization), during her voluntary discharge, she had a 10-days treatment with Oseltamivir antiviral (one tablet a day) until November 2006. Her disease had a good progression in those 10 days.

Despite the enhancement of the viral pneumonia, the stability of the coronary disease and the slight improvement of the renal failure, no healing criteria could be evaluated due to the patient's trip to Buenos Aires.

Also, she had had arterial hypertension for 4 years and pulmonary tuberculosis healed 30 years ago.

The patient had an arteriovenous fistula on January 16th, 2007.

6) Physical examination :

Patient in poor general condition, asthenic, adynamic, well placed in time and space. No improvement could be evaluated.

Arterial blood pressure: 90/60 mmHg.

Cardiac frequency: 70 bpm

Respiratory frequency: 18 breaths per minute

Temperature: 36.2° C

The patient had generalized muco- cutaneous paleness, arteriovenous fistula without murmur, without thrill, and without inflammation signs. She presented a dual light cannula on the right side of her neck.

Respiratory system: crepitant rales were auscultated in the lower base and third mid of the right hemithorax.

Cardiovascular system: no murmurs were auscultated. First and second hypophonesis noises.

Abdomen: soft and depressible, no pain during the abdominal palpation, there was no organomegaly, there was air-fluid noises

Thorax X-ray: congested hili, redistribution of flow.

Electrocardiogram: cardiac frequency 75 bpm, left ventricle overload, isolated ventricular extrasystoles, negative T-wave in V₁ and V₂.

Laboratory tests:

Leukocytes: 11900 cells/ml

Glucose: 0.80 g/L

Urea: 4.60 g/L

Hematocrit: 28%

Ionogram: Na: 136 meq/L

K: 4.95 meq/L

Cl: 101 meq/L

7) Admission diagnosis:

1- acute fever syndrome

2- chronic renal failure

Presupposed diagnosis:

1- possible septal myocardial ischemic

Other diagnosis:

1- Arterial hypertension

2- Sequel of tuberculosis (from 30 years ago)

Another Laboratory tests examination was required, panculture (hemoculture, uroculture, coproculture, and retro-culture), electrocardiogram.

8) Treatment:

1- Hyposodic and kidney protection diet.

2- Atenolol 12,5 mg p/ day.

3- Calcium, 1 gr, every 8 hours.

4- Folic acid, one tablet a day

5- B12 vitamin, one tablet a day.

6- Low-flux humid oxygen

2nd day of hospitalization. 6th February, 2007.

Arterial blood pressure: 110/60 mmHg.

Temperature: 36.5° C

Patient in poor general condition. Subcrepitan rales were auscultated in the lower lobe and third-mid of the right lung. There were no more yellow stools in diarrhoea.

Laboratory tests:

Leukocytes: 17000 cells/ml
Neutrophils: 92 %
Lymphocytes: 8 %
Hematocrit: 29 %
E.S.R.: 115 mm/1st H
P.C.R: positive (++++)
Glucose: 0.56 g/L
Urea: 0.72 g/L
Creatinine: 4.51 mg/dl
Platelet count: 116000
Calcaemia: 8.26 mg/dl
Phosphatemia: 2.72 mg/dl
Total proteins: 6.46 g/dl
Albumin: 2.88 g/dl
PH: 7.44
pO₂: 50% mmHg
pCO₂: 32% mmHg
Sat O₂: 86%
VDRL: non-reactive
Chagas: non-reactive

Coproculture:

Leukocytes, 5 per field. There were no microorganisms or parasites.

Hemoculture:

Gram positive cocci was developed in diplo and bunches.

Retro-culture:

Gram positive cocci in diplo and bunches.

Admission to intensive care was required, however, there were no beds available.

3rd day of hospitalization. 7th February, 2007. (1st day of antibiotics)

Arterial blood pressure: 80/50 mmHg.
Cardiac frequency: 100 bpm
Temperature: 36.7° C

Patient in general poor general condition. Crepitant rales were auscultated in lower lobe and third-mid of right hemithorax. No diuresis.

Hemoculture: typification: staphylococcus spp.

Retro-culture sample typification: staphylococcus spp.

Laboratory tests:

Glucose: 1,01 g/L
Urea: 0.70 g/L
Ionogram: Na: 145 meq/L
 K: 6,06 meq/L

Cl: 107 meq/L

Bacteremia diagnosis and staphylococcus sepsis.

Treatment: vancomycin 1 gr. every 12 hours was added to the treatment. Admission to intensive care was required, but there were no beds available.

4th day of hospitalization. 8th February, 2007. (2nd day of antibiotics)

Arterial blood pressure: 60/20 mmHg.

Temperature: 37.5° C

Patient in severe general conditions. Crepitant rales were auscultated in lower lobe and third-mid of right hemithorax.

Hemoculture: staphylococcus aureus was found.

•**Diagnosis:** sepsis due to staphylococcus aureus.

Antibiogram: resistance to gentamicin

Sensitivity:

Clindamycin

Eritromycin

Refampicin

1st generation cephalosporin

Ciprofloxacin

Tetracyclines

Sulfamethoxazole Trimethoprim

Laboratory tests:

Ionogram: Na: 141 meq/L

K: 6.92 meq/L

Cl: 108 meq/L

PH: 7, 38

pO₂: 78% mmHg

pCO₂: 42% mmHg

Sat O₂: 95%

Treatment: dopamine drip with inotropic. Once again, a bed in the intensive care unit was required but there was none available. The patient was seriously ill, with dyspnea type IV, with hypertension and imminent life risk. In poor conditions, the patient presented a cardiopulmonary arrest. Cardiopulmonary resuscitation was carried out but the patient did not come round. She passed away.

Comments:

The patient had been hospitalized, a bacterial infection due to staphylococcus aureus was detected and she died due to sepsis.

The cause of her staphylococcus aureus infection could be hemodialysis cannula. The patient had pain in that zone, which became infected and produced this sepsis.

The death of the patient was caused by an infection as a final cause. But, at the beginning, it had been produced by the influenza vaccine and its disease "Prolonged influenza". After its subsequent complications, the case ended fatally.

If the patient had not been vaccinated with the influenza vaccine, she would not have had this prolonged viral disease, with relapses and complications, and she would have not died.

This is another unfortunate case of thousand patients who had "Prolonged influenza" with complications. However, they were not diagnosed or treated correctly and died due to this disease.

CLINICAL CASE N° 7

PROLONGED INFLUENZA

"Prolonged influenza"
complicated with viral bilateral pneumonia and acute-chronic renal failure. (Conditions improved with Oseltamivir antiviral)

(Pneumonia caused by the influenza virus from the anti-influenza vaccine)

CLINICAL HISTORY:

1) Personal information:

Gender: male

Age: 56 years old

Address: Capitán Meza – Paraguay

Occupation: Shopkeeper

Nationality: Paraguayan

2) Hospitalization:

Date: 30th April 2007

3) Reason for consultation: dyspnea type III and IV, dizziness, difficulties to walk, nausea and vomiting.

4) Disease Background: still in healthy conditions, the patient got the influenza vaccine on April 3rd, 2007. 24 hours later he felt pain in the place where he got the vaccine (left shoulder) which lasted two days. 7 days after the vaccination, he had fever, sneezing, intense mucus rhinitis, headache, marked asthenia, photophobia, lacrimation, intense coughing with mucous expectoration that lasted 7 days and then became mucopurulent, night sweats, earache, difficulties in walking. Then, he felt epigastric pain, vomiting and diarrhoea which lasted 3 days.

These symptoms remained for three days with no improvements. He was prescribed antibiotics for fifteen days. During this time he did not improve; thus, these viral and prolonged respiratory manifestations persisted.

The patient worsened with dyspnea type III, dizziness and difficulties to walk and then nausea and vomiting. For these reasons, he consulted again and was admitted to hospital.

5) Important background: he had type II diabetes for 8 years; at present, treated with glibenclamide 5mg, every twelve hours. Arterial hypertension for three years, treated with enalapril, 10mg a day. Not clarified hepatopathy three months before (normal at the time). Important haematemesis two months before.

•Clinical analysis from March 2007 presents urea of 0,44 g/L and creatinine of 0,77 mg/dl, normal.

6) Physical examination: lucid patient, without fever, aware of time and space.

Arterial blood pressure: 110/40 mmHg.

Cardiac frequency: 110 bpm

Respiratory frequency: 22 breaths pm

Temperature: 36° C

Weight: 65.200 Kg

Height: 1.57 mtrs.

The respiratory system showed a decrease of the expansion and abolished vocal vibrations in the right lower lobe, dullness in the same lobe. At auscultation, it presented hypoventilation in the right lower lobe and crepitant rales above the right lower lobe, in the right mid field. Hypoventilation was generalized in both lungs. Cardiovascular system: normal pulse rate, same. No murmurs were auscultated. First and second sounds, normal.

7) Diagnosis: with this clinical presentation in mind, the following diagnosis was made:

- 1) Viral pneumonia with pleural effusion in the right lung.
- 2) Viral and prolonged respiratory disease.
- 3) Prolonged influenza

Other diagnosis:

- 1) Diabetes type II
- 2) Arterial hypertension

8) Treatment: he was treated with cephalosporin, antibiotic of third generation (cefotaxime, 1gr every 6 hours) and other prescriptions. Oseltamivir antiviral was suggested for the treatment but it was not prescribed.

9) Complementary methods:

Front view of chest x-ray: homogeneous opacity in the right lower lobe with exposure of right costophrenic breast.

Electrocardiogram: normal, sinus tachycardia.

Laboratory:

Leukocytes: 15000 cells/ml

Hematocrit: 20 %

Neutrophils: 87 %

Lymphocytes: 12 %
Monocytes: 1%
Glucose: 2,04 g/L
Creatinine: 4.57 mg/dl
Urea: 0.77 g/L
Ionogram: Na: 135.8 meq/L
 K: 6.01 meq/L
 Cl: 108 meq/L

Fluid in pleural puncture: scarce quantity, light yellow, limpid aspect.
Pleural fluid culture: klebsiella pneumoniae was detected.
No etiology of tuberculosis was detected, B.A.A.R in pleural fluid, negative sputum.

Progression of the disease: he was hospitalized and treated with antibiotics during 11 days. Leukocytes decreased to 8.500 mm³ before the discharge.

The patient was transferred to another hospital to keep on with the treatment. The patient was discharged on May 10th, 2007.

Other diagnosis during the hospitalizations:

1. Anemia
2. Acute renal failure

REHOSPITALIZATION

May 16th, 2007

He was admitted to hospital again, 6 days later. He presented exacerbation of the same symptoms and fever, cough with mucous expectoration, functional dyspnea type III.

On physical examination crepitant rales were auscultated in the right mid-lobe of the respiratory system, rhonchi and generalized sibilances and hypoventilation. Also, crepitant rales were auscultated in the left mid-lobe. The patient presented bronchospasm which he had never had before.

Complementary methods: front view of **chest x-ray** May 15th, 2007: interstitial alveolar infiltrates, diffuse left parahilar and homogeneous opacity in the right lower lobe. (see fig.1)

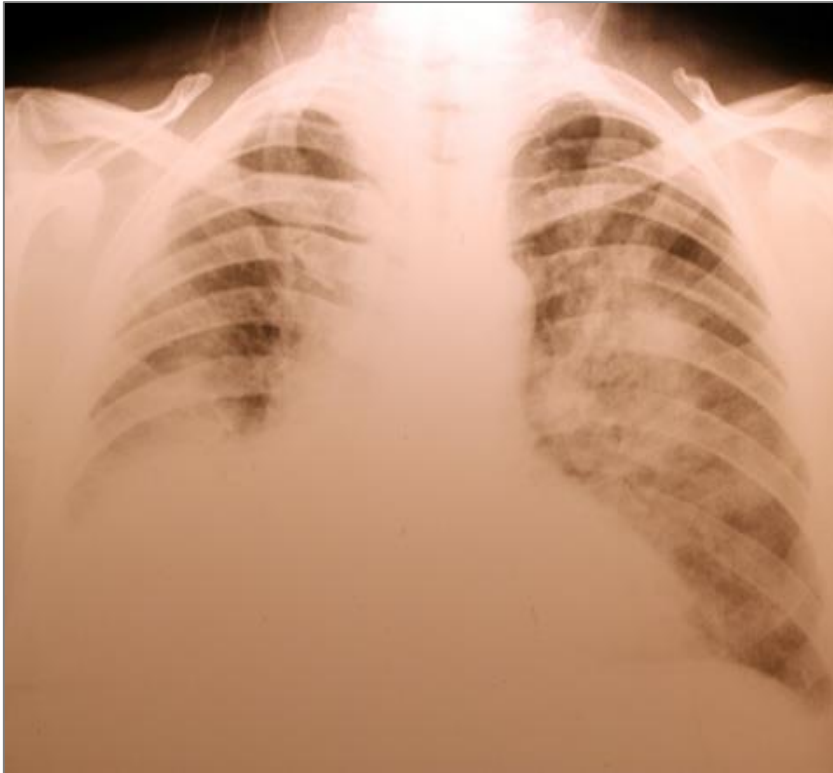

Fig. 1: Date May 15th, 2007

Laboratory:

Leukocytes: 19100 cells/ml

Hematocrit: 20%

Neutrophils: 94 %

Lymphocytes: 6%

Glucose: 3.34 g/L

Creatinine: 3.02 mg/dl

Urea: 1.06 g/L

Ionogram: Na: 137 meq/L

K: 3,78 meq/L

Cl: 108 meq/L

P.C.R: positive (++++)

Prothrombin time: 83%

Platelet count: 282000

Creatinine clearance: 24 ml/min.

Total proteins: 6.4 g/dl

Albumin: 2.31 g/dl

Diuresis 1.400 to 2.400 cc/day.

A pleural ultrasound was performed: in the lower lobe, a slight pleural effusion was detected and consolidation in the right lower lobe. Also, a slight pleural effusion in the left lower lobe was detected.

A hemoculture, a uroculture, a sputum culture and a pleural fluid culture were carried out. All of them had no development and were negative for bacteria, fungus and tuberculosis.

Echocardiography: slight pericardial effusion, slight dilatation of the left atrium, concentric hypertrophy of the left ventricle. Ventricular function: normal.

Eye examination: multiple hemorrhages, cotton-wool exudation and fine vessels.

Kidney ultrasound: normal kidneys, conserved diametre (10 cm long)

Latest diagnose at second hospitalization:

- Second viral pneumonia (left hemithorax) with left pleural bleeding.
- First persistent viral pneumonia in the right lower lobe with right pleural effusion.
- Viral bilateral pneumonia
- Acute to chronic kidney failure.
- Prolonged viral respiratory syndrome (exacerbation)
- Persistent prolonged influenza
- Pericardial effusion

Treatment: once again he was treated with antibiotics: Another cephalosporin of third generation (ceftriaxone every 12 hours) for 15 days. Again, a treatment with Oseltamivir was suggested although it was not carried out.

Progression: once the treatment with the antibiotics was finished, he had front view chest x-rays done on May 30th, 2007. There was persistency of radiopacity in the right lower lobe and although there was a decrease of the interstitial alveolar infiltrates in the left hemithorax, they persisted. (See fig. 2)

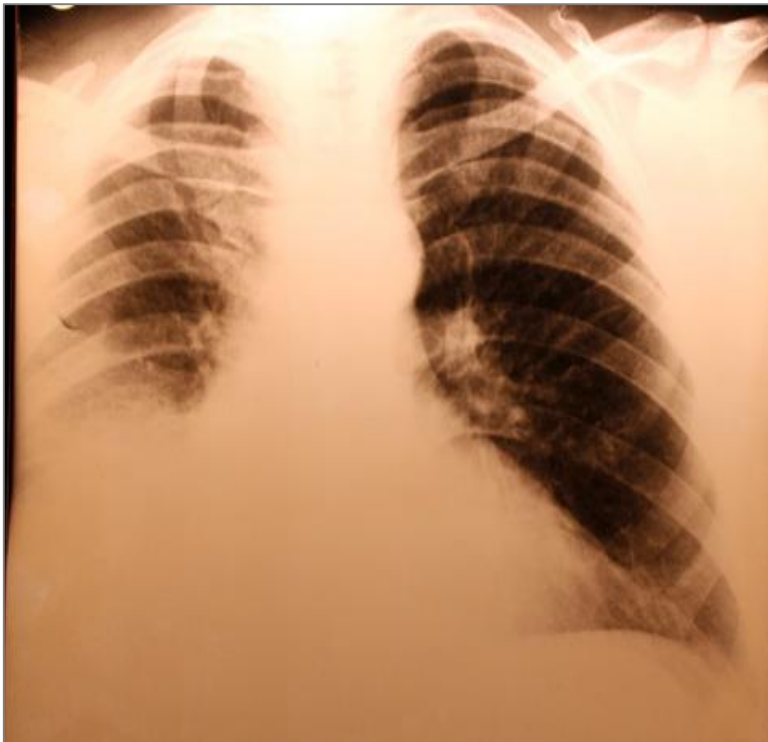

Fig.2: Date May 30th, 2007

Progression: once the treatment with antibiotic was over, a chest CT was done showing contradistinction on June 1st, 2007 (see pic 3, 4, 5, 6, 7, 8, 9 and 10) and guided pulmonary puncture (see pic. 11 and 12). The conclusions were as follows:

Parenchymal condensation of middle lobe with air-bronchogram.

Pleural thickening of the right lung. No pleural effusion was detected on the right lung.

Slight infiltrates, interstitial type of irregular distribution in the left lung.

Slight pleural effusion in the left lung.

Paratracheal lymphadenopathies on the right side.

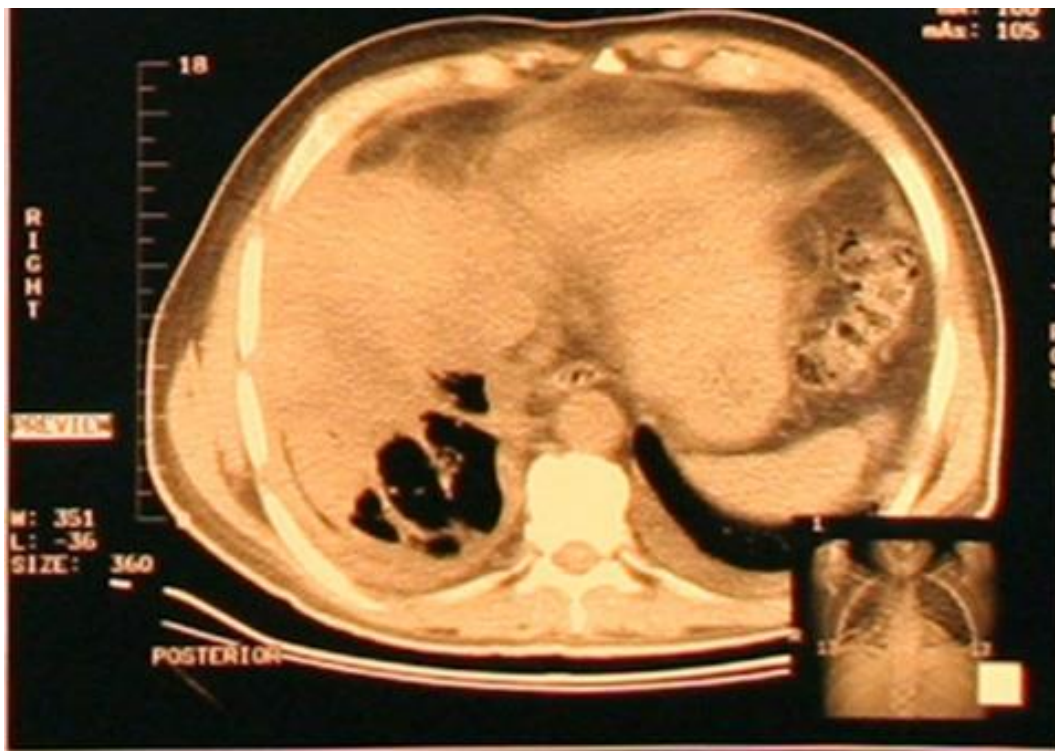

Fig. 3: Date: June 1st, 2007

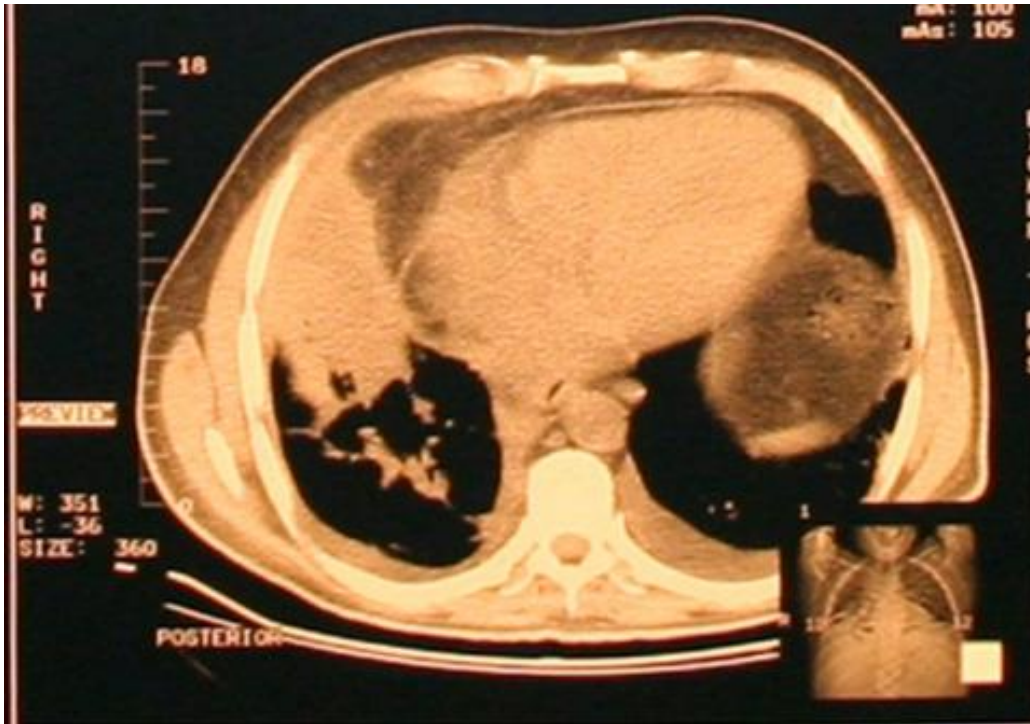

Fig .4: Date: June 1st, 2007

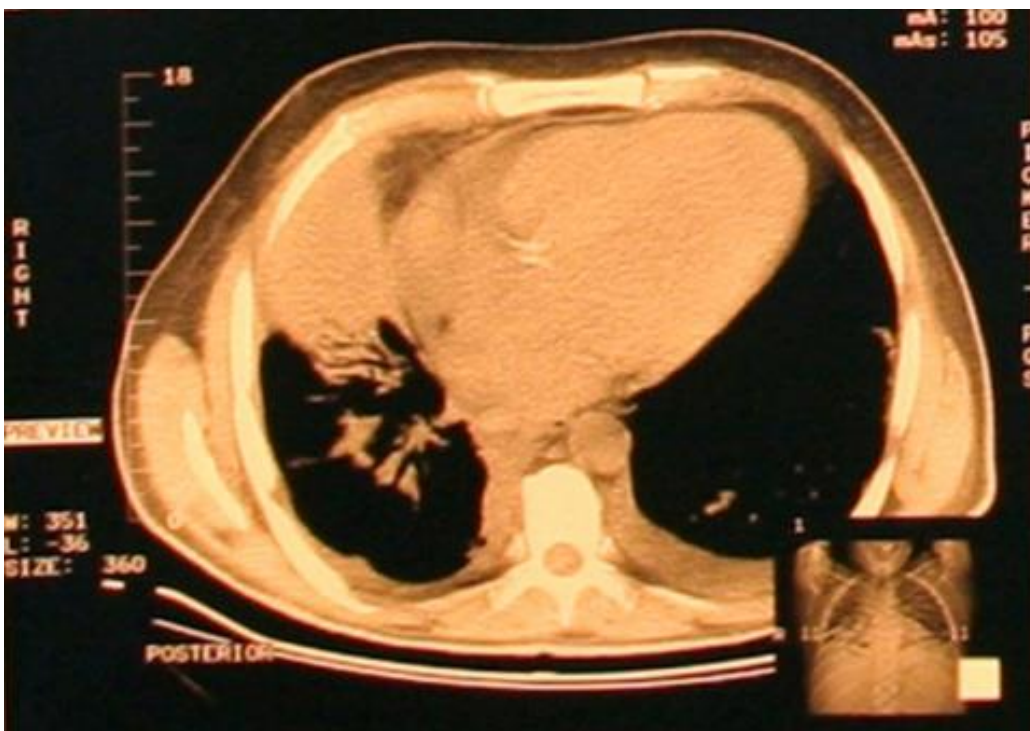

Fig. 5: Date: June 1st, 2007

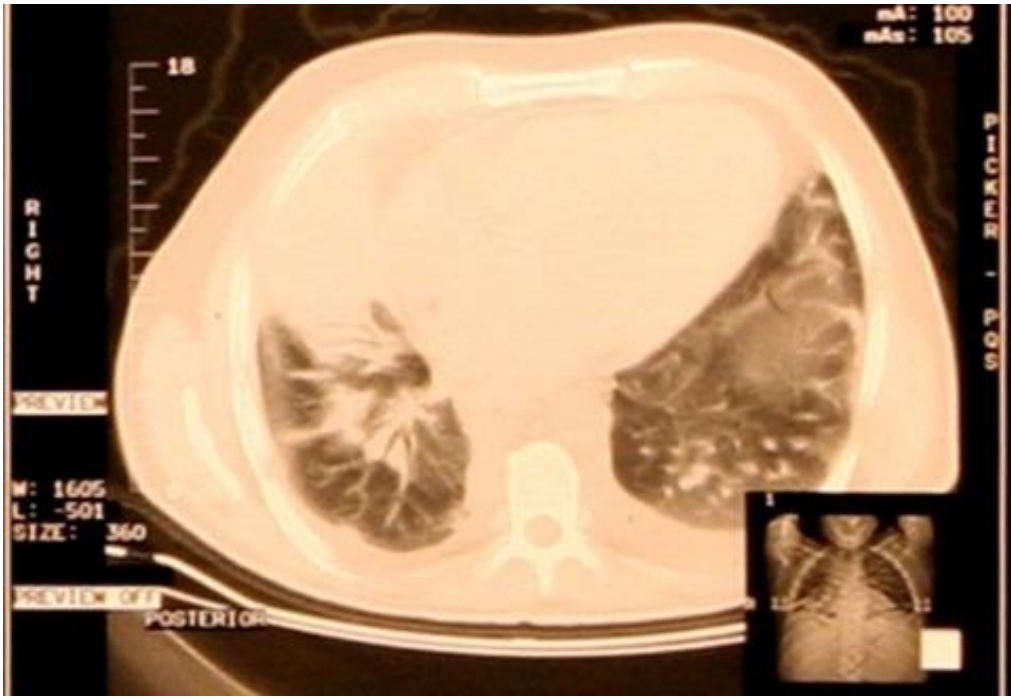


Fig. 6: Date: June 1st, 2007

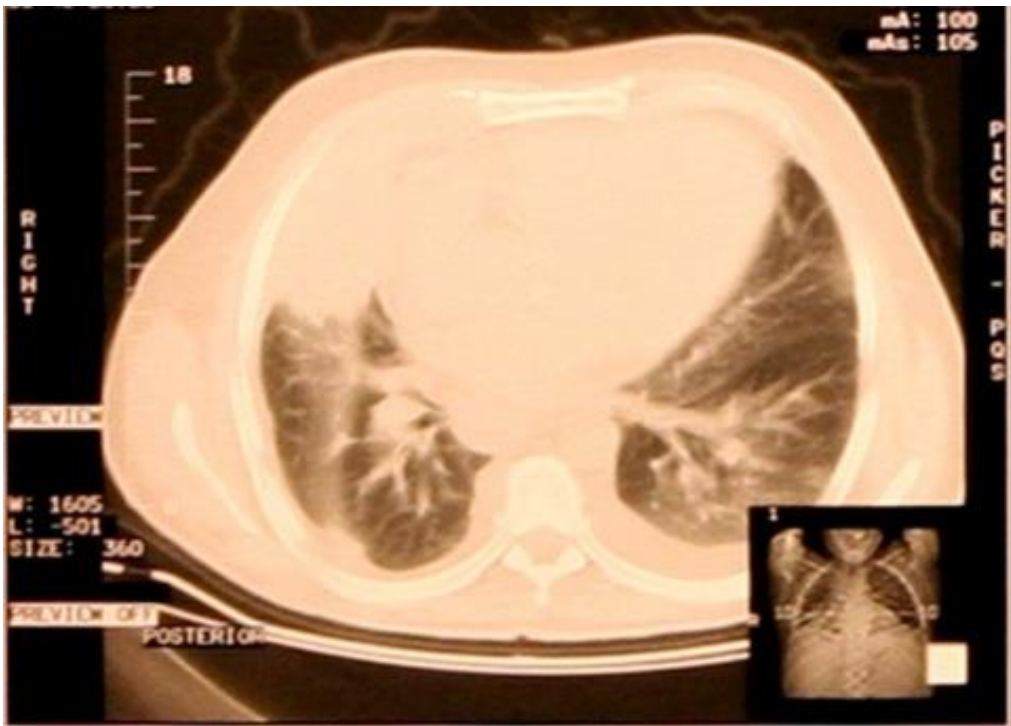

Fig. 7: Date: June 1st, 2007

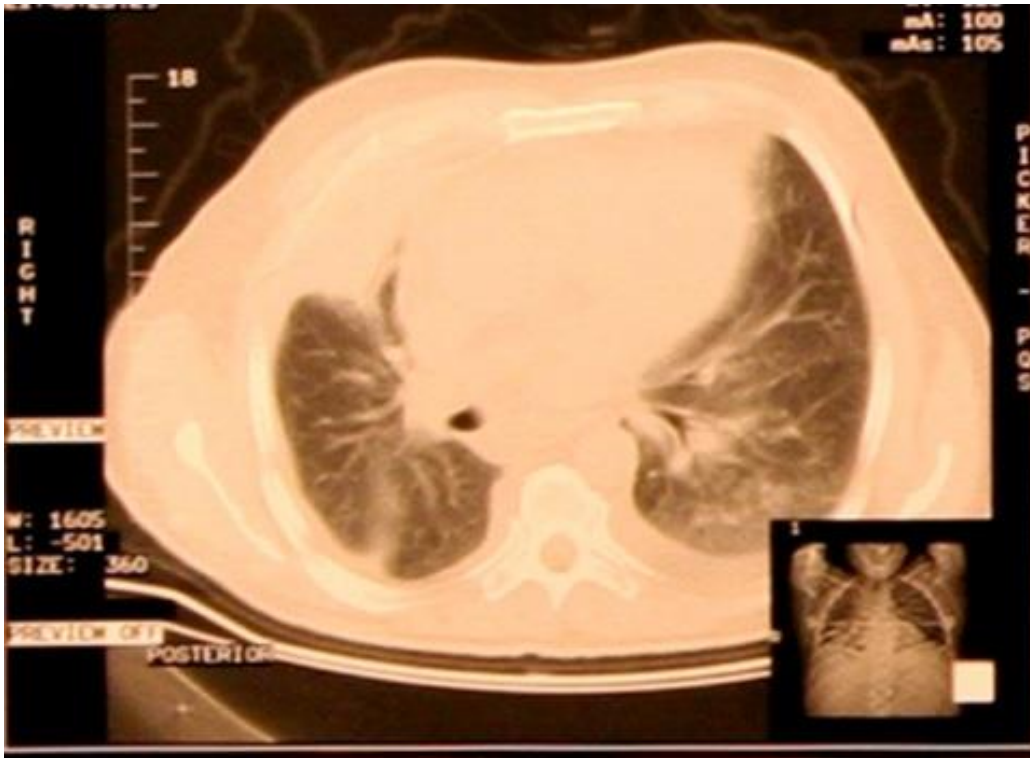

Fig. 8: Date: June 1st, 2007

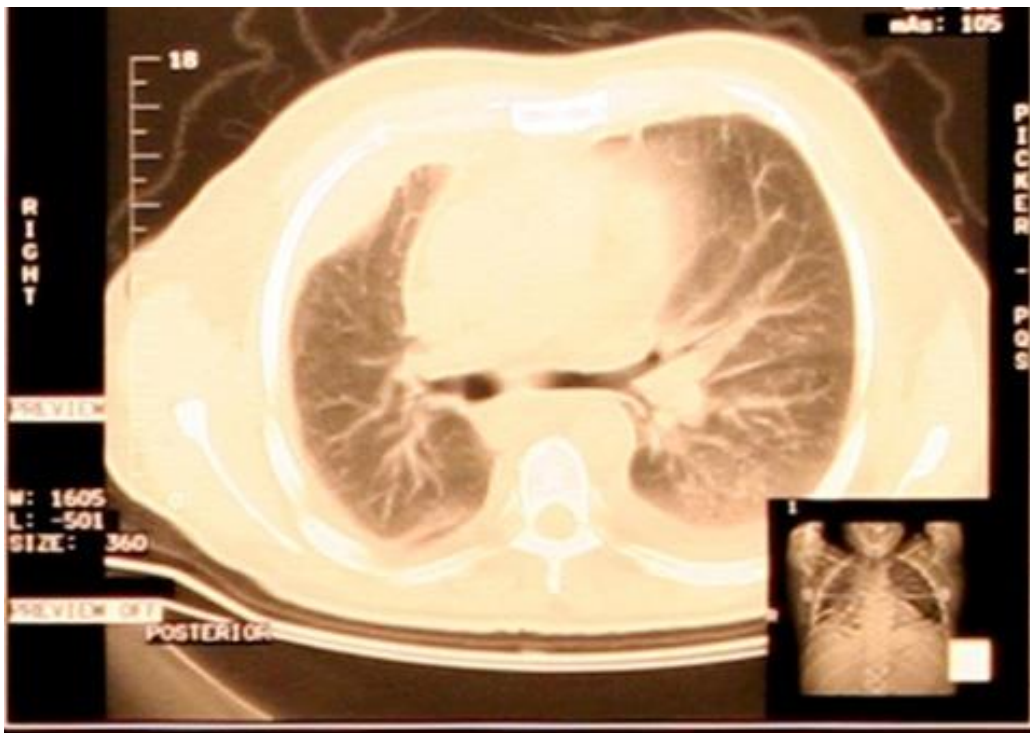

Fig. 9: Date: June 1st, 2007

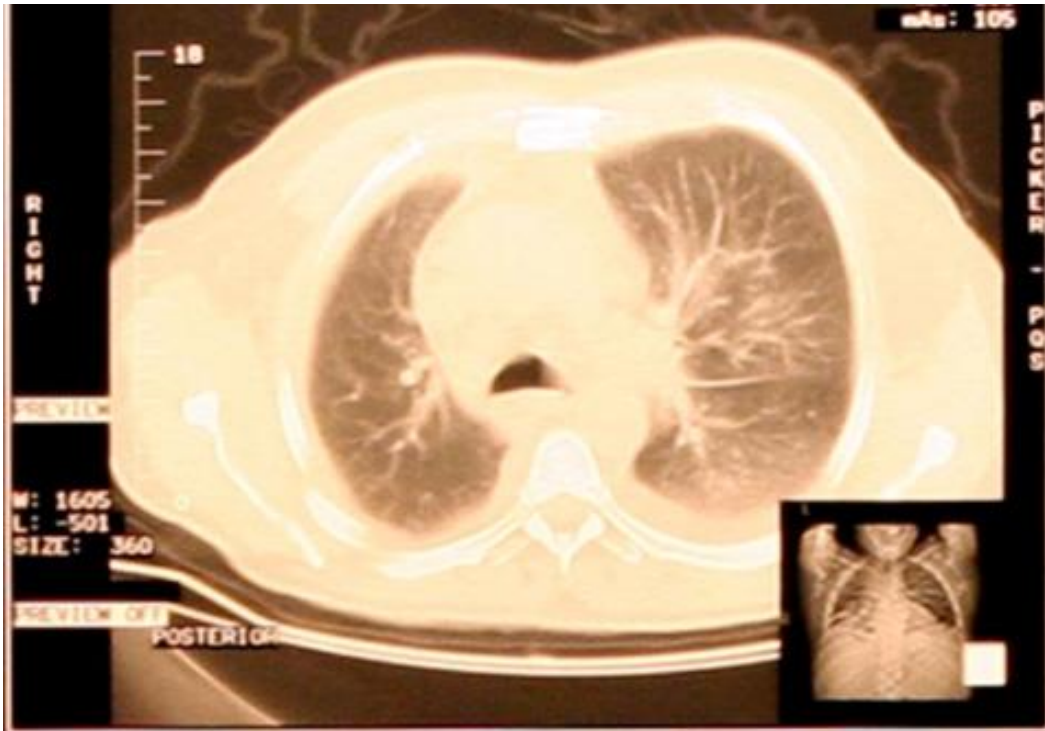

Fig. 10: Date: June 1st, 2007

Pulmonar punction guided by T.A.C: it was performed in the area of parenchymatous condensation in the right lung, in a central area with less density, purulent material was extracted.
The report about the puncture fluid showed no bacterial development.

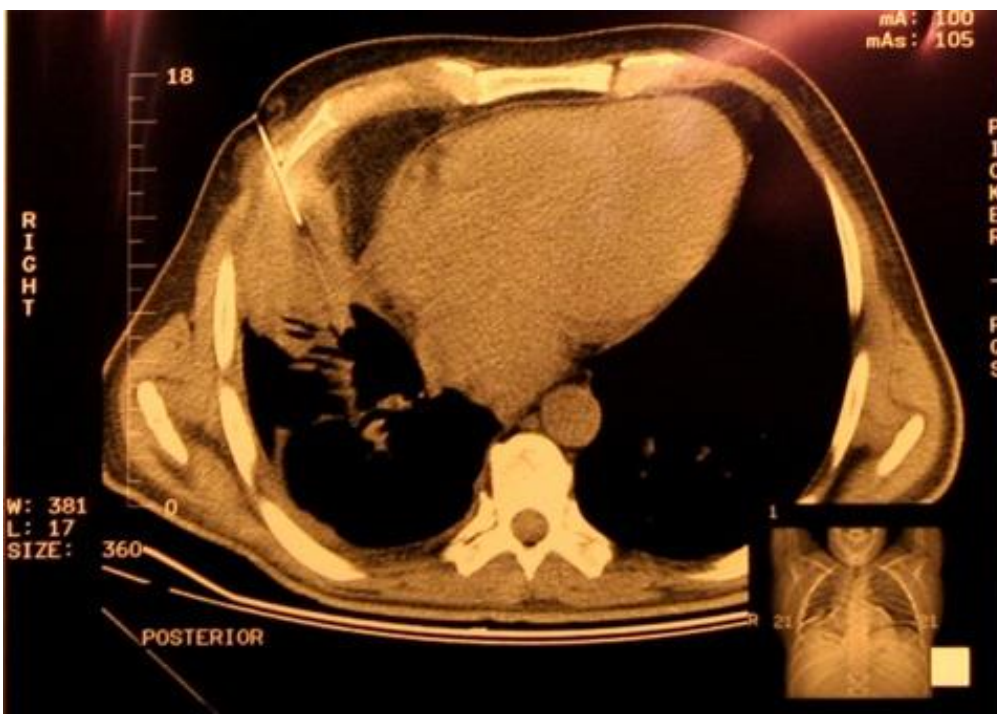


Fig. 11: Date: June 1st, 2007

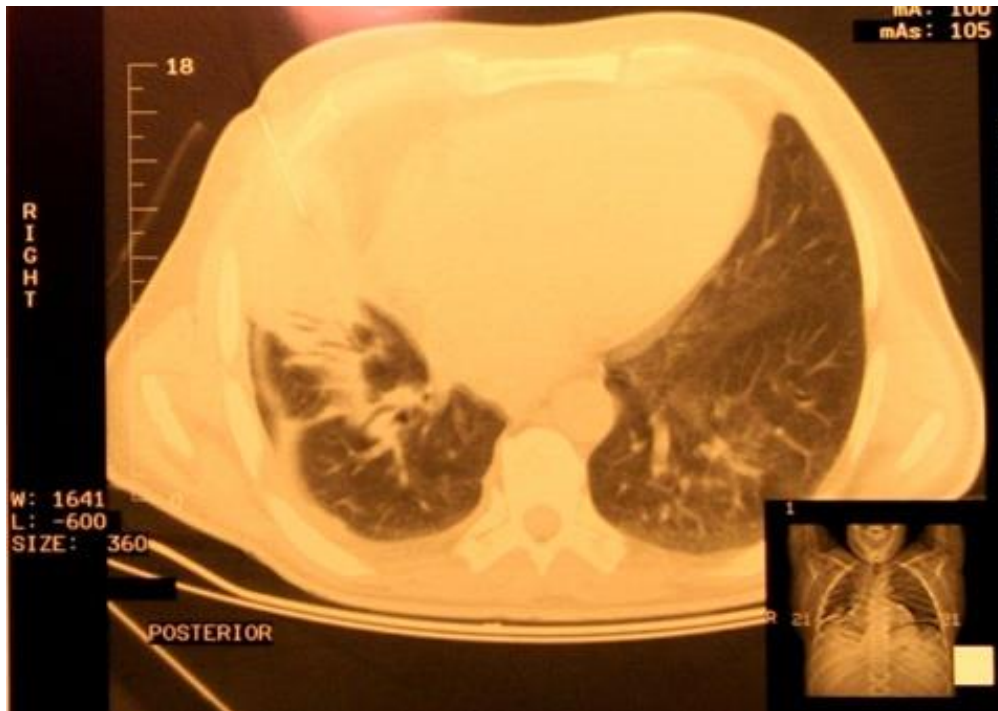

Fig. 12: Date: June 1st, 2007

Progression: he was still hospitalized for 30 days although he was in better conditions. His new viral pneumonia on the left had not healed, nor had his pneumonic consolidation in right lower lobe, which was persistent. Leukocytes decreased to 7900 cells/ml.

The patient was discharged from hospital. The patient still had a viral pneumonia not cured. For this reason, a treatment with Oseltamivir was decided. When the patient was discharged, he was prescribed Oseltamivir antiviral, one tablet a day, for ten days. This dose -one tablet a day- was prescribed due to his renal failure.

Clinically, the patient had improved 90% on the fourth day of treatment and remained like that till the tenth day.

The chest x-ray on the tenth days presented radiopaque persistence in the right lung and disappearance of the interstitial alveolar infiltrates in the left lung.

The patient did not come back to the medical checkup.

- It was the first time the patient had been vaccinated with the influenza vaccine.
- The patient had never had such a prolonged influenza.
- The patient had never had pneumonia.
- The patient had never presented with bronchospasm in his life.
- The patient did not have renal failure before being vaccinated.
- The patient had not had pericardial effusion before being vaccinated.

Observations: in spite of being in good conditions, this patient got the influenza vaccine. 7 days after that, he presented all the symptoms of a viral, prolonged respiratory disease for 20 days. It did not heal even when

he was being treated with antibiotics for 15 days. This disease is called "Prolonged influenza". The clinical manifestations worsened and got complicated with:

1. Viral pneumonia in the right lower lobe with pleural effusion.
2. Acute renal failure

All the bacterial, fungus and tuberculosis culture tests were negative. Only an infection was found in the fluid from the right pleural bleeding due to klebsiella pneumoniae. This was treated with a third generation cephalosporin antibiotics for 10 days. The clinical manifestations improved but he was not thoroughly cured. He was transferred to another hospital to keep on with the hospitalization and treatment.

After 5 days, he came back with exacerbation of the symptoms of his respiratory infection but now with respiratory semiology in left hemithorax and interstitial alveolar infiltrates in the left lung as well. This confirmed another viral pneumonia in the left hemithorax.

This was another viral exacerbation of the disease "Prolonged influenza" with a new viral pneumonia on the left side. Also, there was a persistence of the pleural effusion in the right lower lobe, and a pneumonic infiltrate in the same lobe.

Once again the bacterial, fungus and tuberculosis culture tests were done, with negative results.

He was treated with a third generation cephalosporin once more, for 15 days, but he was not thoroughly cured for the second time.

Once again, the following diagnosis was confirmed:

- 1- New viral pneumonia in the left lung with a minimal pleural effusion.
- 2- Persistent viral pneumonia in the right lower lobe with pleural effusion.

This is persistent viral pneumonia caused by the disease "Prolonged influenza". It did not cure with antibiotics because it had a viral etiology.

This was confirmed by the x-ray computed axial tomography where a pneumonic condensation with persistent air-bronchogram could be observed. Also, there was pleural thickening on the right without pleural bleeding. In left lung, an interstitial infiltrate with uneven distribution and a slight pleural bleeding was observed. There was no more pericardial effusion present.

Another diagnosis was acute renal failure which he had never had before.

This could have been triggered or worsened by the renal vasculitis that the influenza vaccine generates. There is also a persistent inflammatory state of positive PCR (++++).

The patient had been treated with two schemes of antibiotics for 25 days without curing two pneumonias and without detecting bacterial infections. This proved that neither of the pneumonias had a bacterial or mycotic origin, or tuberculosis. This reaffirmed that these pneumonias had viral origins: respiratory virus of prolonged action which is the "Prolonged influenza". We should point out the fact that the patient had improved 90% on the fourth day when being treated with Oseltamivir antiviral and maintained this state during the following ten days. Also, the images of the front view chest x-rays improved. The interstitial infiltrates on the left disappeared and the radiopaque image persisted in right lower lobe. This image was interpreted as a secular pachypleuritis since no more pleural

effusion on the right was found in the computed tomography but a pleural thickening.

Once again, this demonstrated that this disease "Prolonged Influenza" produces **serious pulmonary complications**, persistent viral pneumonia, primary viral bilateral pneumonia, pleural affections with pleural effusion, **pachypleuritis** and **cardiac complications like pericarditis**.

Also, **renal complications**, an acute renal failure produced by the influenza vaccine and the disease "Prolonged influenza", renal vasculitis making more serious the injuries of the diabetes and arterial hypertension that he previously had.

If the patient had been treated with Oseltamivir antiviral at the beginning of this disease, "Prolonged influenza", he would have been cured and therefore he would not have presented with pulmonary, renal and cardiac complications.

Even when the complications were present, if he had been treated with Oseltamivir during that time, they would have been less serious and would have cured faster.

This was another case out of thousands of patients affected by the prolonged influenza that present pulmonary, renal and cardiac complications that are neither diagnosed nor treated specifically and thus they remain with sequels and their lives are at risk. They are not treated in time with Oseltamivir because the diagnosis are not well made even in this year, 2013.

- There are still hundreds of thousands of affected people, that have not been diagnosed or treated specifically. They suffer from this disease and risk getting complications or dying even in this year 2013.

CLINICAL CASE N° 8

"PROLONGED INFLUENZA"

Year 2006 "Prolonged influenza" and medium term-delayed effect complicated with primary viral bilateral pneumonia.

(Pneumonia caused by the influenza virus from the anti-influenza vaccine)

CLINICAL HISTORY: Year 2006

1) Personal information:

Gender: female

Age: 74

Address: Posadas

Occupation: Retired

Nationality: Argentine

2) Hospitalization:

Admittance day:

- September 1st 2006, emergency room. (day 1)

- September 4th 2006, common room. (day 4)

Discharge day:

- September 20th 2006

3) Reason for consultation: dyspnea at rest and hemoptysis.
She had been derived from a minor complexity centre with a diagnosis of bilateral pneumonia and respiratory insufficiency.

4) Background of the present disease: 15 days before hospital admission (August 15th) she had flu-like symptoms. Fever, mainly at night, myalgia, rhinorrhea, cough without expectoration, presence of hemoptysis, dyspnea type IV, pleural pain in both lower lobes that increased with deep inspiration and when coughing.
As an important fact, 2 months before this, she already had dyspnea type II, polydipsia and urinary incontinence.

5) Important background: diabetes type II diagnosed 6 years before, irregular treatment with oral hypoglycaemic, metformin, glibenclamide. Arterial hypertension diagnosed 2 years before, treated with enalapril 20 mg a day.

- She got the influenza vaccine in 2005, in a health care centre. Seven days later, she presented a viral respiratory manifestation similar to a cold which lasted for three months. She presented with two exacerbations, one in October and the second one in December 2005. In August 2006 another exacerbation occurred (the third one) and it got complicated with bilateral pneumonia. This was what pushed the patient to the consultation and hospitalization.

- Between the second and the third exacerbations, she spent eight months without symptoms, normal.

The patient had never been asthmatic, nor had presented with bronchospasm or pneumonia.

She did not smoke or drink alcohol.

She was overweight.

6) Physical examination: when admitted to hospital, she was lucid though in bad conditions, Glasgow 15/15, obliged supine position, dyspnea type IV.

Arterial blood pressure: 130/70 mmHg.

Cardiac frequency: 95 bpm

Respiratory frequency: 32 breaths per minute

Temperature: 38.6° C

Subcutaneous cellular tissue: without edema.

Neck: jugular engorgement of 1/3 with inspiratory collapse.

Respiratory system: dyspnea type IV in orthopnea, generalized hypoventilation with predominance in both bases, rhonchi and sibilance, crepitant rales in both bases of lungs.

Cardiovascular system: normal rhythm. Hypophonetic sounds and superposition of respiratory sounds which were not measurable.

Abdomen: no pain on palpation, without organomegaly, positive air-fluid sounds.

7) Diagnosis:

1. Bilateral pneumonia.
2. Severe respiratory insufficiency
3. Exacerbated viral respiratory disease (third relapse)
4. "Prolonged influenza", affected by the influenza vaccine in 2005, 3 months duration, 3 relapses.
5. "Retarded effect" at medium term, because of the influenza vaccine.
(third relapse complicated with pneumonia)

Other diagnosis:

1. Diabetes type II
2. Arterial hypertension
3. Obesity

Required: double hemoculture, bladder catheterization, routine blood test, blood gas, chest x-ray (front view), electrocardiogram, echocardiogram, pleural ultrasound, abdominal ultrasound and eye fundus exam.

Treatment:

1. Venipuncture and hydration
2. Semi-sitting position
3. Diabetes and hyposodic diet
4. Humid low flux oxygen
5. Nebulizations with physiological solution and salbutamol, every 6 hours.
6. Ampicillin + sulbactam. 1,5 gr every 6 hours.
7. Enalapril, 10 mg every 12 hours.
8. Ranitidine 300 mg a day.
9. Hydrocortisone 500 mg a day.
10. Insulin, depending on glucose control results.
11. Kinesio-respiratory care.

9) Complementary examination

Chest x-ray: congestive hila, interstitial alveolar infiltrates in both lower lobes, predominantly on the left side.

Electrocardiogram: compatible with normal ECG. Low voltage complexes.

Laboratory:

Leukocytes: 10500 cells/ml
Hematocrit: 40%
Glucose: 3.80 g/L
Urea: 0.16 g/L

Final diagnosis:

1. Primary viral bilateral pneumonia.
- This diagnose was confirmed by the examination and tests, by the interstitial alveolar infiltrates in the chest x-rays.

2nd day of hospitalization. 2nd September, 2006. (In the emergency room)

Arterial blood pressure: 110/70 mmHg.
Cardiac frequency: 80 bpm
Respiratory frequency: 18 breaths per minute
Temperature: 38.5° C

Patient in rather poor condition. Her respiratory system still had generalized hypoventilation, mainly in both bases, bibasal crepitant rales.

Sodium heparin was started, 5.000 subcutaneous units, every 12 hours.

3rd day of hospitalization. 3rd September, 2006. (In the emergency room)

In the respiratory semiology, generalized hypoventilation and bibasal crepitant rales persisted predominantly in both bases.

4th day of hospitalization. 4th September, 2006.

Positive data in physical examination: the patient was in poor condition. Lucid, dyspnea type IV in orthopnea with expansion in bases and diminished vertices. Abundant wheezing in both lungs. Crepitant rales were auscultated in the right lower lobe and fore right region. Bladder catheter was removed.

Laboratory:

Leukocytes: 6400 cells/ml
Neutrophils: 75 %
Lymphocytes: 23 %

Eosinophils: 2 %
Monocytes: 0 %
Basophils: 0 %
Urea: 0.28 g/L
Cholesterol: 116 mg/dl
Glucose: 2.10 g/L
Triglycerides: 119 mg/dl

Hydrocortisone increased, 1 gr every 8 hours. This was due to the bronchospasm.

Comments: a treatment with Oseltamivir was proposed but not carried out.

5th day of hospitalization. 5th September, 2006.

Patient in rather poor condition, without fever, normotensive, glucose 2.86 g/L.

In the respiratory semiology, wheezing in both lungs was auscultated, and crepitant rales on the right lower lobe. She did not walk by herself. Diuresis in diapers due to urinary incontinence.

Laboratory:

Leukocytes: 5000 cells/ml
Neutrophils: 74 %
Lymphocytes: 21 %
Eosinophils: 3 %

Monocytes: 2 %
Basophils: 0 %
Urea: 0.38 g/L
Creatinine clearance: 0.81 ml/min.
Prothrombin time: 79%
Partial Thromboplastin time: 31"
Platelet count: 205000
Total proteins: 7.30 g/dl
Albumin: 3.05 g/dl

Abdominal ultrasound: multiple biliar litiasis was observed without any other abdominal alteration.

Pleural ultrasound: no free fluid was observed. There was no pleural bleeding.

6th day of hospitalization. 6th September, 2006.

Patient with no fever. Blood pressure 140/70 mm.Hg. No more wheezings were auscultated but crepitant rales persisted in both lung bases plus half third of the left lung.

The patient was improving conditions, she moved with her relatives' help and sat on a wheelchair. The echocardiogram could not be done due to a bad thoracic window and difficulties in the patient's thorax.

7th day of hospitalization. 7th September, 2006.

Laboratory:

Leukocytes: 6200 cells/ml
Neutrophils: 84 %
Lymphocytes: 15 %
Eosinophils: 0 %
Monocytes: 1 %
Basophils: 0 %
P.C.R: Positive (++++)
Eritrosedimentation: 85 mm/1st H

Despite the seven days of treatment, the inflammatory reaction went on. Medication was changed from hydrocortisone to prednisone 40 mg a day, oral route. Insuline NPH was prescribed, 30 units a day (30/10) subcutaneous.

8th day of hospitalization. 8th September, 2006.

Afebrile patient, blood pressure 140/80 mm.Hg, glucose 1.80 g/L. Better general conditions. She presented crepitant rales in lower lobes and mid third of left hemithorax. Sputum bacilloscopy (BAAR) was lost.

9th day of hospitalization. 9th September, 2006.

Afebrile patient, blood pressure 160/90 mmHg, glucose 2.79 g/L. Better general conditions. She presented crepitant rales in lower lobes and mid third of left hemithorax.

10th day of hospitalization. 10th September, 2006.

Afebrile patient, blood pressure 150/100 mmHg. She maintained the same condition as the previous day.

11th day of hospitalization. 11th September, 2006.

Afebrile patient, blood pressure 150/70 mmHg. Bibasal crepitant rales were auscultated. A chest x-ray was done.

Laboratory:

Leukocytes: 7600 cells/ml
Neutrophils: 74 %
Lymphocytes: 22 %
Eosinophils: 2 %
Monocytes: 2 %
Basophils: 0 %
Glucose: 1.01 g/L
Urea: 0.54 g/L
Creatinine: 0.80 mg/dl
Platelet count: 378000
Eritrosedimentation: 80 mm/1st H

12th day of hospitalization. 12th September, 2006.

Patient in poor condition, afebrile, blood pressure 140/90 mmHg, crepitant rales in both lower lobes and rhonchi in both lungs. The patient manifested intercostal pain in lateral right region of thorax.

In spite of the 12 day-treatment, crepitant rales in both lung bases as well as rhonchi persisted. Therefore, the viral pneumonia persisted too.

Ampicillin and sulbactam were left off after 12 days of treatment. Instead, amoxicillin + clavulanic 1 gr was prescribed every 12 hours, oral route. Prednisone was decreased to 20 mg a day.

13th day of hospitalization. 13th September, 2006.

Afebrile patient, blood pressure 130/100 mmHg, crepitant rales were auscultated only on the right base. The patient walked alone slowly. Corticosteroids were left off.

14th day of hospitalization. 14th September, 2006.

Afebrile patient, blood pressure 130/70 mmHg, crepitant rales were auscultated only on the right base. The patient walked alone slowly.

Ibuprofen was prescribed for the treatment, one tablet every 8 hours due to the pain on the right lateral region of the thorax.

15th day of hospitalization. 15th September, 2006.

Afebrile patient, blood pressure 160/80 mmHg, isolated crepitant rales were auscultated in the right lower lobe.

Laboratory tests:

BAAR: negative
Leukocytes: 8000 cells/ml
Neutrophils: 87 %
Lymphocytes: 15 %
Monocytes: 1 %
Eosinophils: 0 %
Basophils: 0 %
Eritrosedimentation: 75 mm/1st H

Sulbatamol was left off in nebulizations.

16th day of hospitalization. 16th September, 2006.

Afebrile patient, blood pressure 120/80 mmHg, isolated crepitant rales were auscultated in the right lower lobe. Her clinical condition improved. Antibiotics were left off (amoxicillin + clavulanic).

17th day of hospitalization. 17th September, 2006.

Afebrile patient, blood pressure 140/80 mmHg. She was stable with normal general condition.

18th day of hospitalization. 18th September, 2006.

Afebrile patient, blood pressure 110/80 mmHg. Isolated crepitant rales persisted in the right lower lobe and there were generalized rhonchi. Clinical and general state, better.

Laboratory:

Leukocytes: 5500 cells/ml
Neutrophils: 55 %
Lymphocytes: 40 %
Monocytes: 2 %
Eosinophils: 0 %
Basophils: 0 %
Eritrosedimentation: 74 mm/1st H
Glucose: 1.68 g/L
Urea: 0.38 g/L
Creatinine: 0.85 mg/dl
Once again a checking chest x-ray was done.

19th day of hospitalization. 19th September, 2006.

Afebrile patient, blood pressure 130/80 mmHg.

Respiratory system: the patient did not have crepitant rales or rhonchis, nor other noises. Better condition.

20th day of hospitalization. 20th September, 2006.

Patient afebrile, blood pressure 130/80 mm.Hg. The patient was discharged.

Comments:

The patient had a respiratory semiology of crepitant rales for 18 days, even with the prescribed treatment. The diagnosis was complications of the influenza vaccine "retarded effects in mid term" (less than a year her influenza had healed).

She was vaccinated with the flu vaccine in April 2005. Seven days after the shot, she got sick with prolonged influenza which lasted for three months (until July 2005) and had two relapses afterwards, one in October and the second one in December 2005.

In 2006, she did not have relapses until August 2006 when she had a third relapse with the same symptomatology of a prolonged influenza complicated with viral pneumonia. This motivated her current disease and she was hospitalized. Eight months with no symptoms elapsed, which reflects the diagnosis of "retarded effects in mid term".

A treatment with Oseltamivir was proposed but not carried out.

The patient had never been asthmatic before, neither had she suffered from bronchospasm or had pneumonia. However, she was hospitalized during 20 days and presented with manifestations like bronchospasm for 5 days, persistent crepitant rales for 18 days, increment of leukocytes and formal deviation to left (neutrophilia), with intense inflammatory reaction due to the positive P.C.R (++++) and ERS 85 mm/1st H. After 7 days in hospital 74 mm/1st H. persistent, negative culteres for bacteria and negative smear (TBC). She had a 12-day treatment with antibiotics, parenteral, and four more days, oral. 16 days in total. Also on steroidal anti-inflammatory drugs for 8 days.

Analysis:

These manifestations of viral respiratory relapses which got complicated with this bilateral pneumonia without mucoserous or mucopurulent expectoration and a long hospitalization, did not correspond to a common bacterial pneumonia but to a long lasting persistent pneumonia. Due to the crepitant rales and erythro sedimentation ERS 75mm/1st H, with a significant inflammatory reaction with persistent P.C.R +++++, treated with antibiotics and corticosteroids. Despite the treatment, the patient did not improve her condition quickly but she did it slowly. This showed the primary viral pneumonia.

This clinical study is a typical case of the influenza vaccine, more exactly "a mid-term retarded effect" complicated with primary viral bilateral pneumonia.

This is another case among the thousand affected patients with complications, without diagnosis and without specific treatment in its clinical manifestation or etiology, and which was life risking.

CLINICAL CASE N° 9

"PROLONGED INFLUENZA"

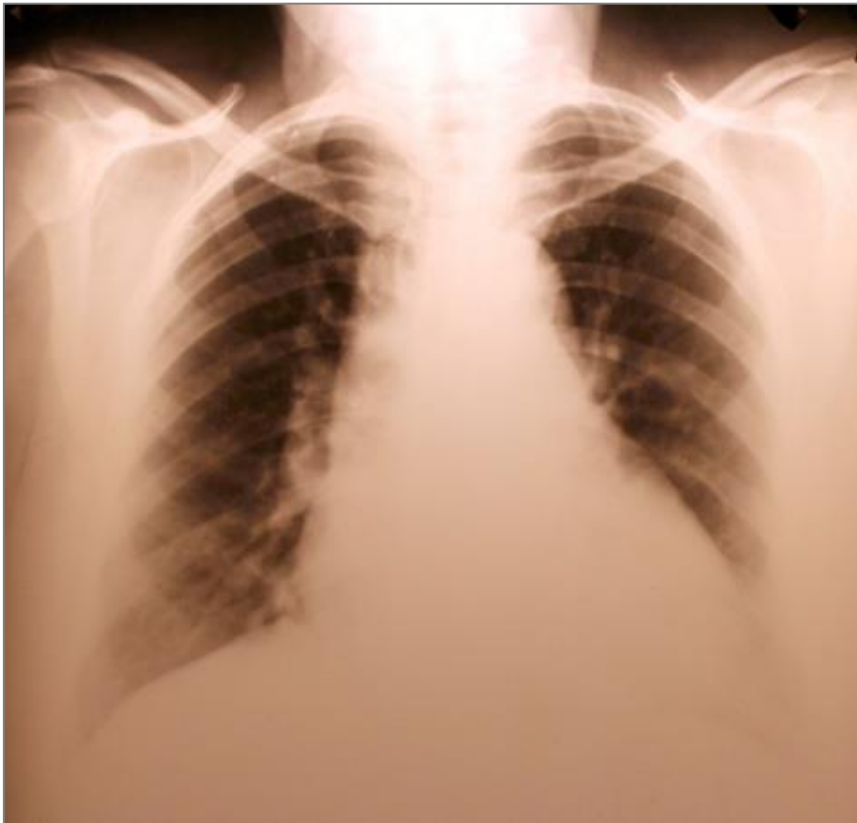Year 2007 "Prolonged influenza" and medium term-delayed effect complicated with primary viral bilateral pneumonia.

(Pneumonia caused by the influenza virus from the anti-influenza vaccine)

A female patient vaccinated with the influenza vaccine in May 2006. She presented the disease "prolonged influenza" with seven successive relapses, from June to November 2006.

In March 2007, without being vaccinated with the flu vaccine, she presented with another relapse with the same symptoms of the previous year for the first time. This got complicated with a viral bilateral pneumonia, predominantly on the left lung.

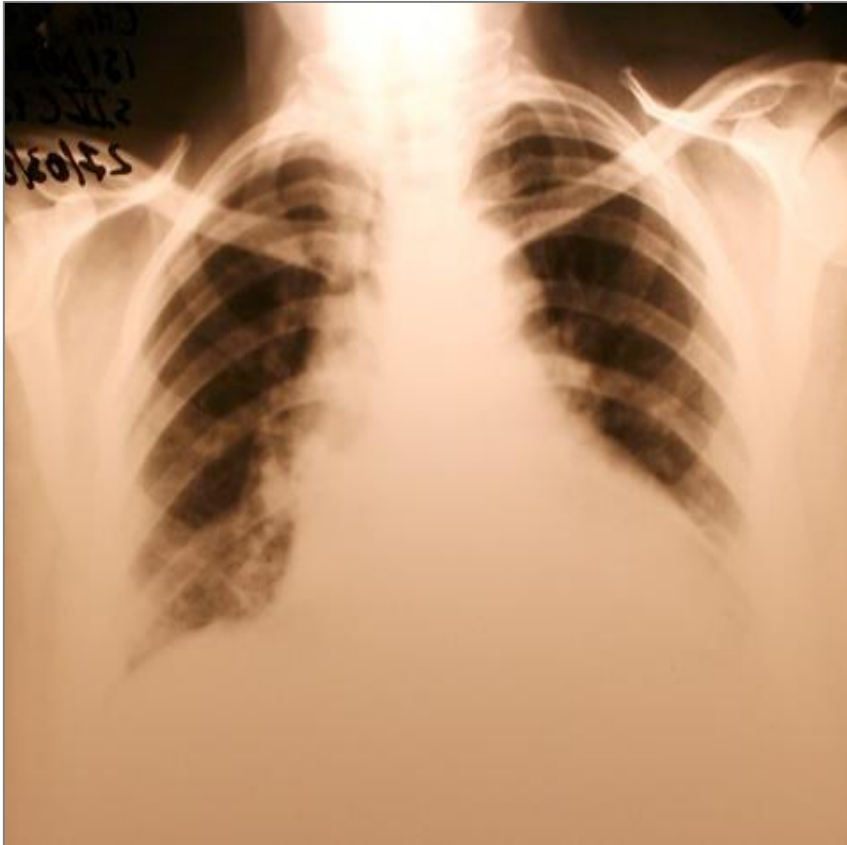In spite of a seven-day treatment with antibiotics, the images of the bilateral pneumonia persisted in a slight degree. (see p. 1 and 2)



Picture 1: date: March 21th, 2007

Viral bilateral pneumonia with left predominance

Note alveolar interstitial infiltrates on the right lower lobe. Alveolar interstitial infiltrates (more radiopaque) on the left lower lobe. Congestive hilum. Cardiothoracic ratio 0,64. She did not present cardiac insufficiency.



Picture 2: date: March 27th, 2007

Viral bilateral pneumonia with left predominance

Front view chest x-ray, 6 days after the treatment with antibiotics. Alveolar interstitial infiltrations persisted in both lung bases. There was a decrease in the congestion of the left hilar region. left congestive hilum.

The patient was treated with antibiotics during 10 days, however, she was not treated with Oseltamivir.

She did not present with cardiac insufficiency.

The pulmonary semiology and the radiology did not match a bacterial pneumonia, but they showed a bilateral pneumonia with viral origin.

In spite of the treatment with antibiotics, the patient did not recover completely before the discharge.

This case corresponds to a *medium term-delayed effect*, a consequence of the influenza vaccine. This is due to the fact that it presented a relapse complicated with viral bilateral pneumonia 4 months after it had been cured (from November 2006 to March 2007)

The patient did not have another shot of the flu vaccine in 2007 because of the relapses complicated with pneumonia and her affections in 2006.

She had never had pneumonia before, this was the first time.

This is another case of thousands of patients without diagnosis or specific treatment that the disease "prolonged influenza with medium term delayed effect" shows. Still with complications in 2013.

CLINICAL CASE N° 10

Year 2008. "Prolonged Influenza" Complicated with Acute Myocarditis, and Acute Heart Failure. It Improved with the Treatment of Antiviral Oseltamivir

(Myocarditis caused by the influenza virus from the anti-influenza vaccine)

CLINICAL HISTORY: YEAR 2008 (Outpatient)

1) Personal information:

Date: October 10th, 2008.

Sex: Male.

Age: 72 .

Address: La Paz - Paraguay.

Job: A farmer.

Nationality: A Paraguayan.

2) Reason for coming to the surgery: Type III-IV Dyspnea, trouble when walking, and pain in both legs when trying to walk along 20 - 30 m. He visited my office on October 10th, 2008.

3) Antecedents of the disease: The patient was healthy, he had no previous disease, he was in good condition. He took the anti-influenza vaccine on June 13, 2008. Ten days later, he presented with muco-serous rhinitis, sneezing, important asthenia, arthromyalgia, a low fever, headache, pain at the back of the neck, itching in the throat, intense irritative coughing, little thick sticky white expectoration, disphonia and bronchospasm that lasted four days. He also complained of weak legs and both his legs hurt. The acute period lasted 10 days. This disease developed but did not improve, with coughing, asthenia, dysphonia, an itchy throat, weak legs, and 7 days after the onset of the disease, type III-IV dyspnea. He had five relapses that lasted 7 days, with all the symptoms until the visit to the hospital on October 10th. He had been ill for 3 months and 14 days, but his disease had not been cured.

He had been prescribed non-steroidal anti-inflammatory drugs, descongostants, and antibiotics, but his symptoms did not improve. Twenty days after having received the vaccine, and seven days after the onset of the disease, he presented with type III-IV progressive dyspnea and heart failure. The diagnosis was Acute Myocarditis, with acute heart enlargement, first-degree AV block and cardiomegaly. He was treated with enalapril and hydrochlorothiazide and his dyspnea improved only 10 %. This treatment was still being followed.

The disease did not stop. He suffered it for three months and a fortnight, with serious complications until the visit to the hospital on October 10th, 2008.

4) Important antecedents: A healthy patient, he did not have a previous condition. He did not drink, nor did he have a pulmonary or heart disease. He was fit and he did hard work on a farm.

5) Physical examination: The patient was lucid, he did not have a temperature, well placed in time and space.

Arterial Pressure: 100/60 mmHg

Heart rate: 75 bpm

Respiratory frequency: 20 breaths per minute

Temperature: 36°C

Weight: 80 kg.

Height: 1.65 mts.

Skin y T.C.S.: He presented with edema in both legs up to the lower thigh with a positive Godet sign (+++).

Neck: Jugular ingurgitation, no inspiratory collapse.

Respiratory System: He presented with a good air intake, few crepitant rales in the right lower lobe and normal expiration.

Cardiovascular system: Regular rhythm, even. No murmurs were heard, hypo-phonetic first and second noise. Neither a third noise nor a gallop was heard.

Abdomen: A painful hepatomegaly about three fingerbreadths below the costal margin, liver height 15 cm.

6) Diagnosis: In view of these signs and symptoms, the following diagnosis was made:

- 1) Prolonged influenza.
- 2) Prolonged viral respiratory disease.
- 3) 3rd Degree heart failure.
- 4) Acute myocardiopathy (still being studied).

7) Complementary methods:

Front chest x-rays: Dated in June 2008 (--/06/08) at the beginning of his heart disease. An important cardiomegaly was seen. Both lungs, with little fluid redistribution and little hilar enlargement. (See Fig.1)

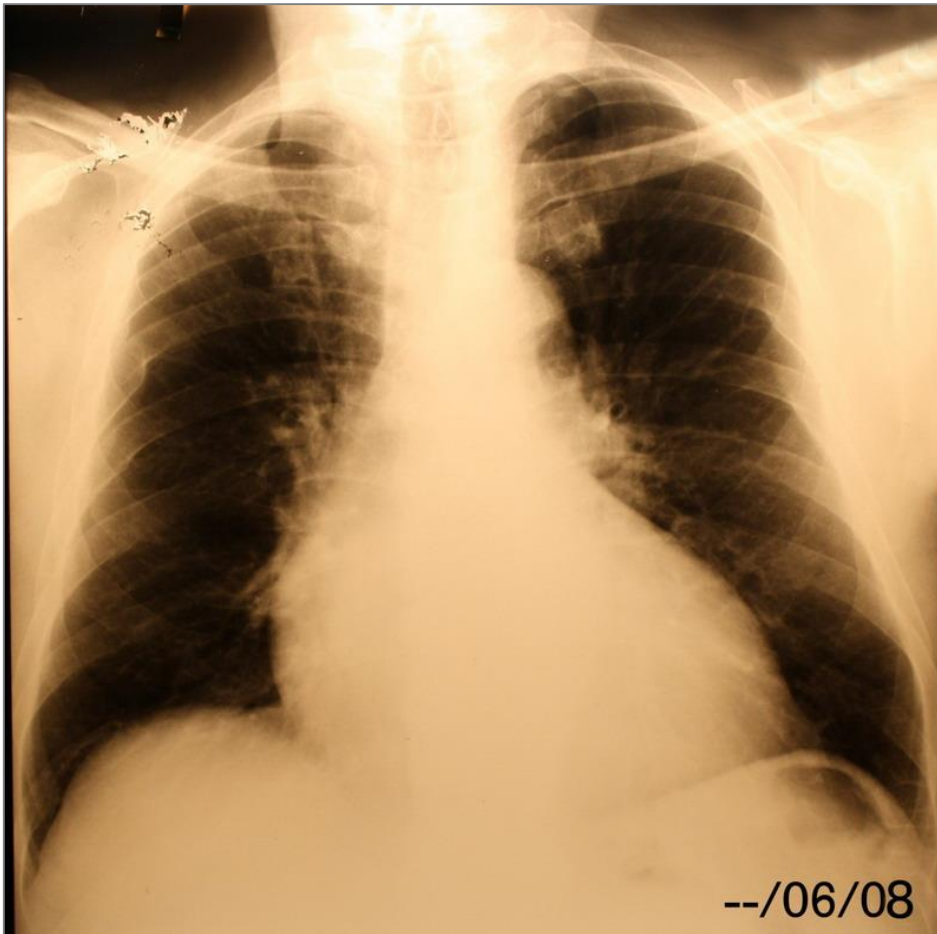


Fig.1: Date June 2008

Electrocardiogram: Date: 10 October 2008.

Heart frequency 75 beats per minute, prolonged P-R 0.28, poor R wave progression in leads V1-V3, lack of R wave in DIII

Conclusion: 1) First degree AV Block, 2) Electric inactivation in anterior septal face and in DIII.

Lab Tests: June 2008

Normal Thyroid Hormones

8) Treatment: The patient was still suffering from his prolonged influenza, and the live or active virus from the anti-influenza vaccine was the etiologic agent of his acute myocarditis. On October 12, 2008 the patient started the treatment with:

1) Antiviral Oseltamivir 75mg. every 12hs. for 10 days.

2) Dexamethasone prolonged fast effect ampoule . One dose.

He continued with enalapril 5mg. every 12hs., and hydrochlorothiazide (1 capsule a day) for his heart failure, low salt diet and other general measures.

9) Development of the disease:

Clinic Cardiac Control on 27 October 2008: With the antiviral Oseltamivir treatment, his viral respiratory condition improved and was

cured in four days. As regards his heart condition, the patient noticed that the grade IV dyspnea improved evidently and progressively until the fifth day. On that day he noticed a great improvement; his dyspnea improved to grade I. The jugular ingurgitation, the hepatomegaly and leg edema disappeared.

Front chest x-rays: On 20 October 2008, eight days after the antiviral treatment started, he still had cardiomegaly, little hilar enlargement and fluid distribution. (See Fig. 2)

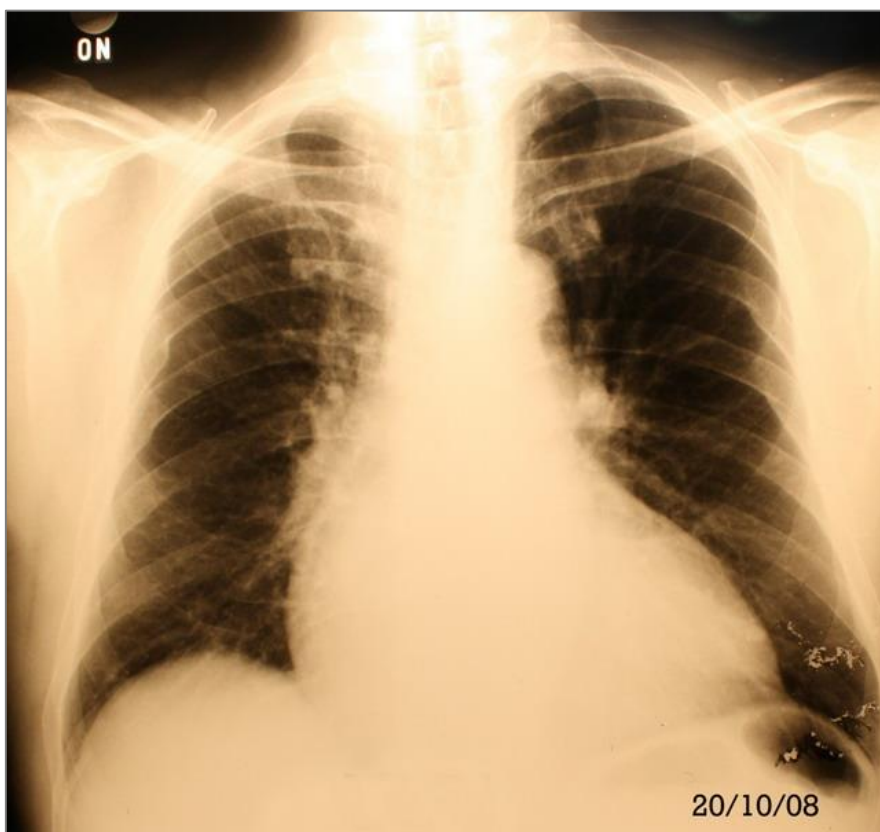


Fig.2: Date 20 October 2008

Lab Blood Tests: October 23, 2008

Erythrocytes: 4450000/mm³

Leukocytes: 6500/ mm³

Bands: 0%

Segmented neutrophils: 60%

Lymphocytes: 35%

Eosinophils: 2%

Monocytes: 3%

Basophils: 0%

Hematocrits: 44%

Platelet count: 165000/ mm³

E.S.R.: 22mm/ 1st hour

P.C.R.: Not reactive

Alkaline Phosphatase: 340 U/L (increased)

GPT: 85 UI/L (increased)

Glucose in blood: 1gr/l
Creatinine test: 1.08 mg/dl
Uric acid test: 78mg/l
Direct bilirrubine: 0.44 mg/dl
Total bilirrubine: 1.14 mg/dl
Qualitative V.D.R.L.: Not reactive
Urine: Normal

Clinical and Cardiac Examination on November 19th 2008: He was in better condition, degree I dyspnea.

M-mode, 2D and Doppler Echocardiography: on November 12, 2008. See Fig.3. Enlarged left ventricle – enlargement of both atria – parietal motility with global hypokinesia – mild deterioration of the function of both ventricles – indirect signs of high pressure in the right cavities. Dilated inferior vena cava, no inspiratory collapse. Normal-size right ventricle, its systolic function was slightly reduced. Dilated left ventricle, its telediastolic diameter was 68mm (normal value up to 56mm), no hypertrophy, slightly reduced deteriorated systolic function, ejection fraction 52 % (Simpson) for a normal value higher than 55%. Global hypokinetic parietal motility. Normal vitral valve, lack of coaptation of its valves in systole (mild to moderate secondary mitral failure – mild-to-moderate mitral insufficiency secondary to dilatation of mitral ring). Normal aortic valve, normal aortic root, normal pulmonary valve.

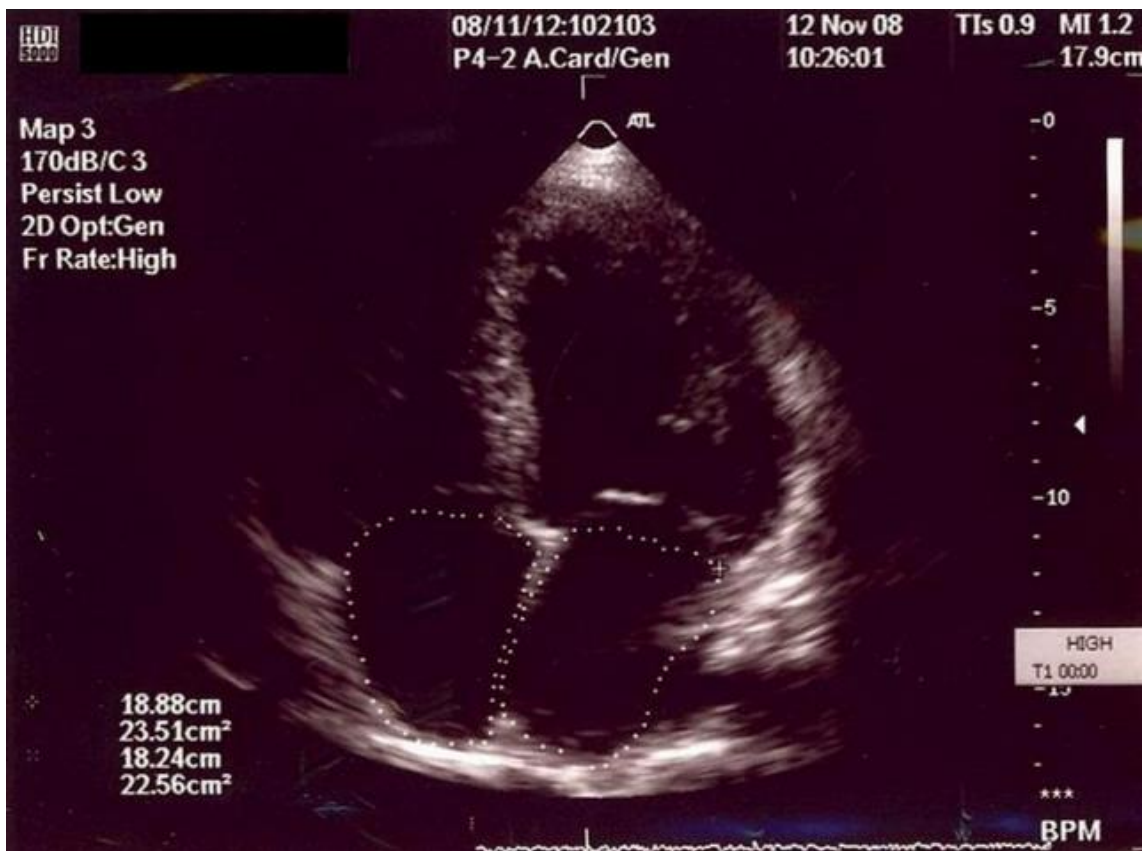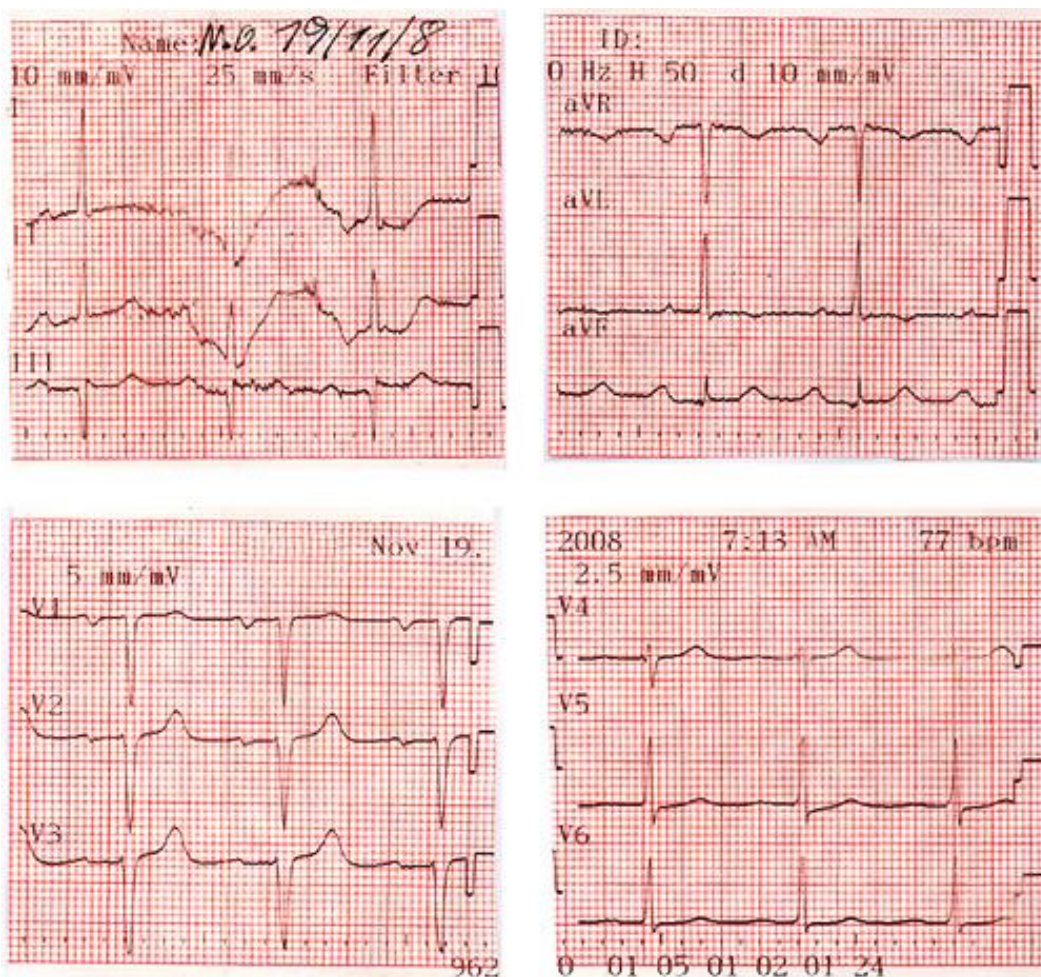


Fig.3: Date 12 November 2008

Dilatation of left ventricle and both atria.

Unfortunately, it was not possible to get the first echocardiogram done on July 2008, which was suspected of being in a worse condition, in order to be compared with this one.

Electrocardiogram: Dated on November 19, 2008. Similar to the previous electrocardiogram, the first degree AV block persisted as well as the electric inactivation of V1, V2, V3 and in DIII, alteration of the repolarization in aVL.



E.C.G.: 19 November 08

Diagnosis:

- 1) Prolonged Influenza.
- 2) Acute myocarditis with stage III-IV cardiac failure . It had a viral etiology, due to an active or live virus of the anti-influenza vaccine.

Comments: Four months after the onset of the disease, a soon as the patient was treated, his respiratory disease – prolonged influenza - was cured in four days and his cardiac failure improved 70%. It went back to stage I fifteen days later with the treatment of antiviral Oseltamivir. He went back to work.

Diagnosis:

1) Adverse effect of the anti- influenza vaccine.

1.1) Prolonged Influenza complicated with **1.2) Acute myocarditis** with stage III-IV acute heart failure.

Development of the disease: February 13, 2009: His heart failure having progressively improved, he was able to run 50 metres without experiencing dyspnea and do very hard work on his farm (at the onset of his disease, when he walked 30 metres his dyspnea was degree III-IV).

Physical examination: The patient was in good condition, normal blood pressure, a systolic mitral murmur was auscultated (a sixth heart sound).

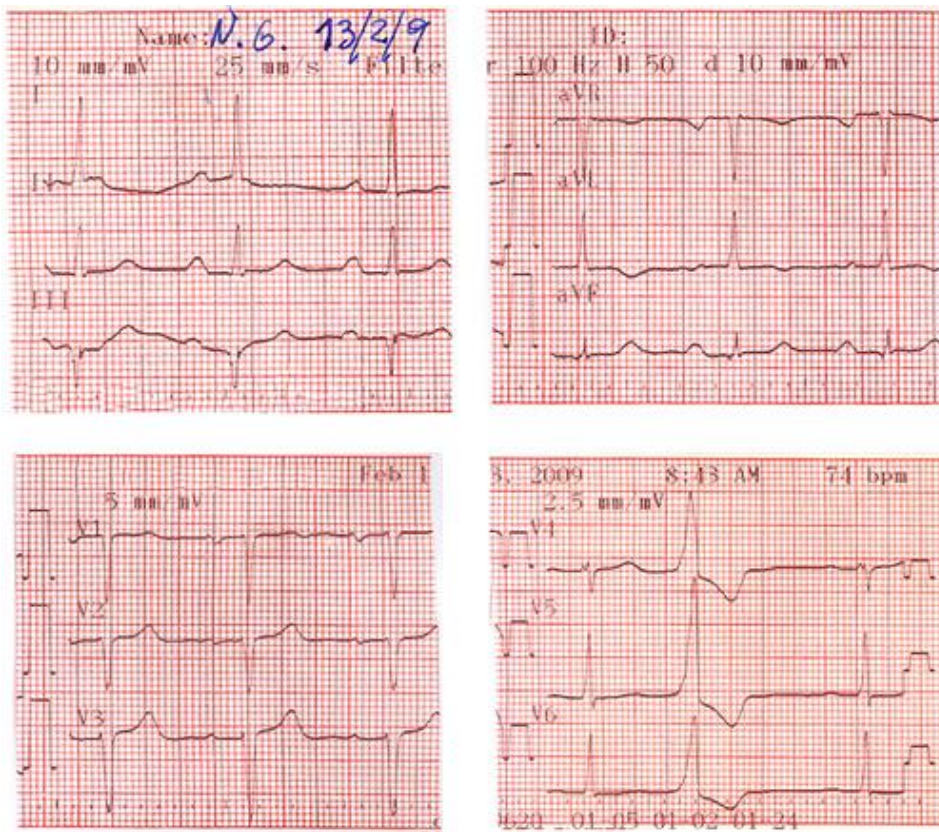
Treatment:

Enalapril 5mg. every 12hs. Hydrochlorothiazide 1 capsule a day.

Aspirin 250mg. a day.

Spironolactone 25mg. a day was added.

Electrocardiogram: February 13, 2009. Persistence of the first degree AV block. Electric inactivation and lack of progression of "R" from V1 to V4 and in DIII. Alteration of repolarization in D1, AVL, V5 and V6. A ventricular extrasystole.



Electrocardiogram dated on February 13, 2009

Front view chest x-ray: Dated on February 13, 2009, a radiological improvement was seen, few hilar enlargement, and better fluid distribution,

- with less cardiomegaly – even though the cardiothoracic index was the same in all the x-rays. (See Fig.4)

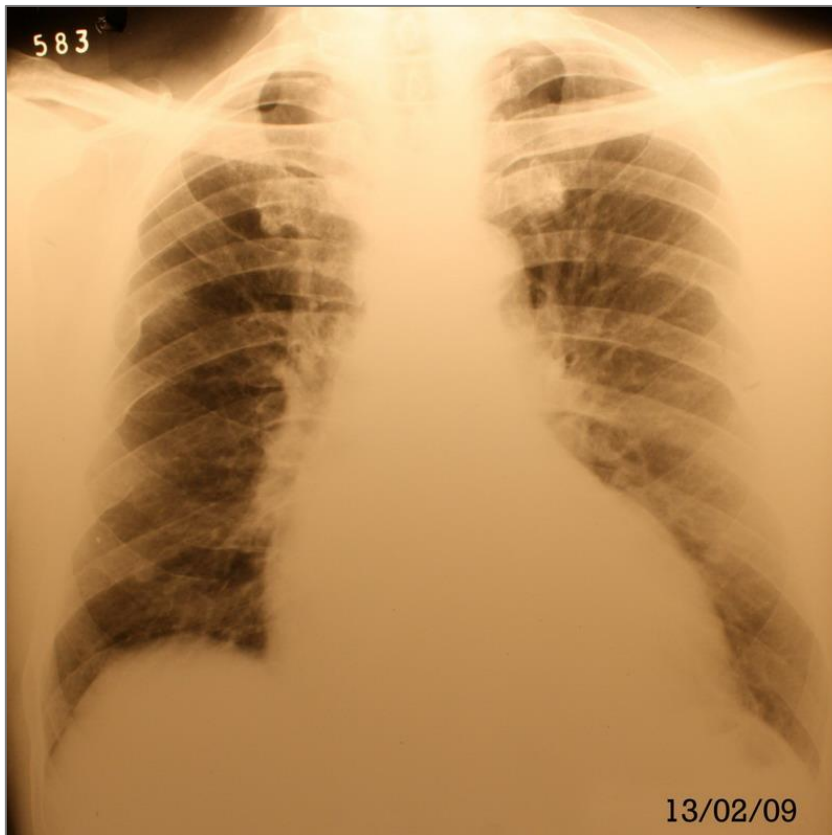


Fig.4: Date 13 February 2009

Comments: If this patient had been treated with the antiviral drug (Oseltamivir) at the onset of his respiratory disease, he would have been cured quickly and he would not have presented the cardiac complications, cardiac failure and acute myocarditis.

Comments:

- It was the first time he had taken the anti-influenza vaccine in his life.
- He had never presented with this prolonged disease and these symptoms, it was the first time.
- Common influenza had always been mild and short, not longer than five days and he had never visited the doctor. He used to suffer from it once every three years.
- He had never presented with bronchospasm. It was the first time when he took the vaccine.
- All signs and symptoms revealed a quick cure of his respiratory disease in four days with the antiviral treatment, even though his prolonged respiratory disease was treated three months and a half after its onset.

- A quick and clear recovery from his heart condition and his myocarditis was seen clinically 15 days later with the antiviral treatment.
- He had never suffered from cardiac failure before.
- He experienced consequences of cardiac failure and first degree AV heart block.
- The patient said that he would never take the anti-influenza vaccine again.

Comments: This is another case of thousands of patients affected by the badly-manufactured anti-influenza vaccine. It presented serious cardiac and respiratory complications, very risky and with serious consequences. These cases are neither diagnosed nor treated specifically in time.

CLINICAL CASE N° 11 (Synthesis)

Year 2010. "Prolonged Influenza" Complicated with Red Lichen Planus. It Improved with the Treatment of Antiviral Oseltamivir

Year 2010. A 63-year-old woman was given the anti-influenza vaccine and she immediately presented with Prolonged Influenza with Red Lichen Planus - Confirmed by biopsy. See Fig.1 (She was treated with Oseltamivir Antiviral and got better quickly 80% in seven days)

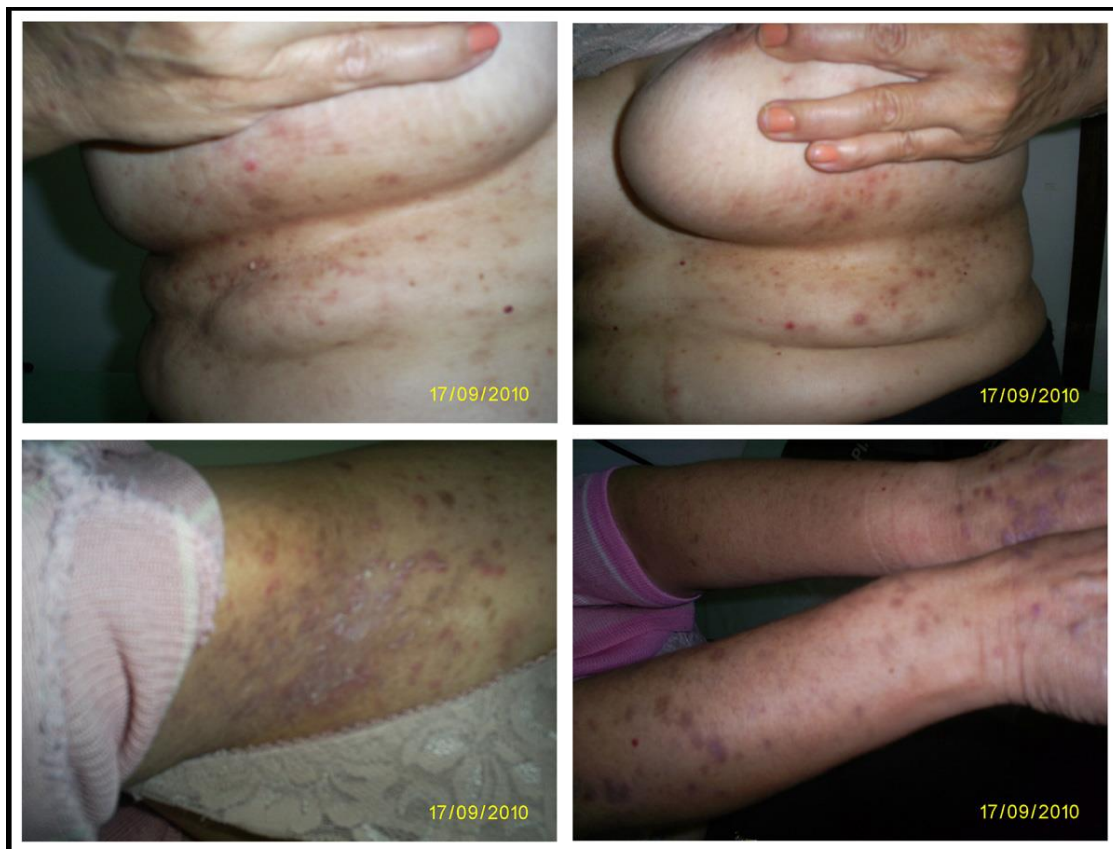

Fig. 1

CLINICAL CASE REPORT N° 12

PROLONGED INFLUENZA (a 9-month-old baby girl)

"Prolonged Influenza"

Complicated with Primary Viral Unilateral Pneumonia and Respiratory Insufficiency. Cured with Oseltamivir Antiviral in 6 days

(Pneumonia caused by an influenza vaccine virus)

CASE HISTORY: YEAR 2012 (an outpatient)

1) Personal information:

Gender: female.

Age: 9-month-old baby girl.

Address: Posadas, Misiones.

Nationality: Argentina.

2) Date of visit to the doctor's office: July 26, 2012.

3) Reasons for the visit: III -IV- grade dyspnea, cough.

4) Antecedents of the present disease: the patient had received the trivalent pandemic influenza vaccine AH1N1 - which had been prescribed by her doctor and because it is mandatory by law in Argentina - for the first time on June 6, 2012. 7 days later she began with mucoserous and then mucopurulent rhinitis, sneezing, a fever of 37.8 °C, asthenia, marked anorexia. Then she presented with mucoserous expectoration and some days later, mucopurulent expectoration. Dyspnea and bronchospasm occurred afterwards, with crying, vomiting and insomnia, there was rejection of breast feeding.

The acute phase lasted 20 days. There were consultations with several pediatricians who prescribed corticoids, bronchodilators (salbutamol), amoxicillin, ibuprofen. The respiratory viral condition persisted, but less intense. Later on, she presented with an exacerbation of the same disease on July 5, 2012 with greater intensity of dyspnea, with bronchospasm and increased high fever 38.5. On July 6, there was a consultation to another pediatrician, who requested a chest x -ray and confirmed pneumonia. He treated it with amoxicillin antibiotic + clavulanate for 7 days. It ended on July 14, 2012, but the baby was not better or cured with this antibiotic treatment.

The baby girl patient's prolonged respiratory infection did not improve, there were symptoms that persisted: fatigue, cough, mucopurulent expectoration, with bronchospasm and dyspnea grade III-IV. The condition went on until July 26, 2012, when the patient was seen at the doctor's office in the adults hospital. The baby's mother was very worried and distressed by the prolonged respiratory viral disease that did not cure. She reported that the baby also had anorexia and her weight had not increased during the month of July.

She had been seen and treated by 4 (four) pediatricians during the months of June and July, with various treatments but her prolonged respiratory viral condition had not cured in a month and 12 days, **in total (42) forty two days**.

She was still suffering from a viral respiratory disease, with a prolonged duration of 42 days of treatment in spite of the four (4) pediatricians who treated her, but her condition had not improved. On the contrary, she was worse and she had pulmonary complications like dyspnea , bronchospasm and pneumonia.

5) Other important antecedents: a fully healthy patient with no previous disease.

6) Physical examination: the patient weighed 9 kg, she was lucid , afebrile , asthenic , she had a mucopurulent rhinitis, cough and mucopurulent expectoration .

Respiratory system: with decreased air entry to both lungs , with bronchospasm, and sibilant rhonchi. Few crepitant rales were heard in the middle and upper fields of the left hemithorax.

Cardiovascular system: regular pulse, even. There were no murmurs, first and second noises were normal.

Front chest x-rays: July 6th . . It has alveolar interstitial filtering in the left upper third of the left lung and bronchovascular congestion in both lungs. Some filtering in the left base. (see fig.1)

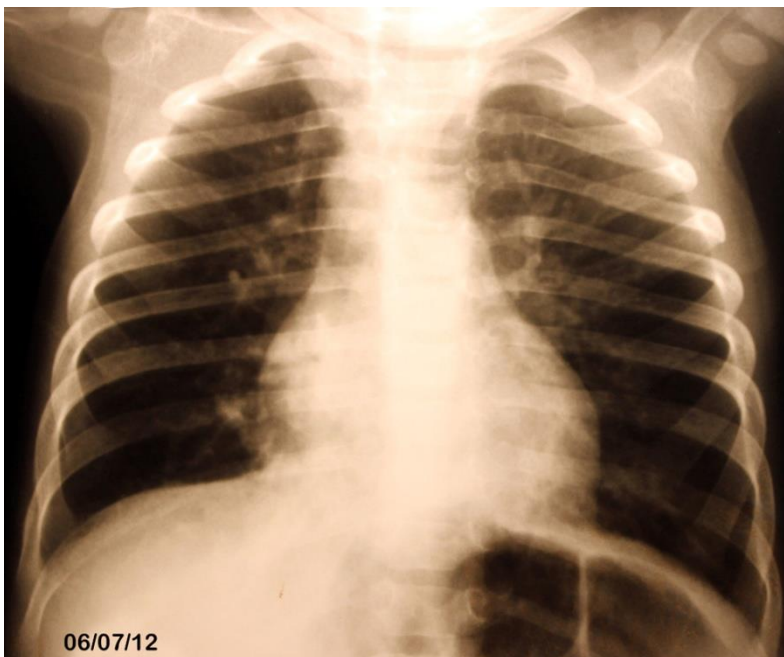


Fig. 1

7) Diagnosis: In view of this clinical presentation the following diagnosis was made:

- 1) Primary viral unilateral pneumonia, produced by the influenza vaccine.
- 2) Prolonged influenza in a 9-month-old baby girl.
- 3) Influenza complicated with severe respiratory insufficiency, bronchospasm, dyspnea, and viral influenza pneumonia.
- 4) Prolonged respiratory viral disease complicated influenza dyspnea, bronchospasm and pneumonia .
- 5) 42-day prolonged respiratory viral influenza.
- 6) Adverse effect of the trivalent influenza vaccine -pandemic H1N1 2012 influenza virus - infected with a live influenza virus from the vaccine
and complicated with primary viral pneumonia from the live viruses of the vaccine.

In view of this diagnoses and its complications, a treatment was prescribed.

8) Treatment : On July 26, 2012 an antiviral treatment for the influenza virus is started: Oseltamivir (original formulation) a 30mg capsule every 12 hours for five days and ibuprofen every 12 hours for five days (Oseltamivir capsules are opened and dissolved with liquid or food).

9) Development of the disease : August 1st.: the girl improved when she took the second capsule (24 hours) and 48 hours later, she recovered 40%, 4 days later 80% and 5 days later, 90%.

This improvement was reported by the mother and confirmed by the good clinical signs and symptoms.

The girl was in good condition, no fever, cough disappeared 24 hours after she started the treatment. The rhinitis and the mucopurulent discharge disappeared as well as mucopurulent expectoration, and no antibiotics. Anorexia disappeared, the girl drank liquids, she ate well , and breastfeeding was normal.

A 90 % (ninety percent) healing and recovery was noted in six (6) days of treatment.

Physical examination : the dyspnea disappeared, there were no adventitious sounds or wheezes, nor bronchospasm, nor adventitious sounds, both hemithoraces were well-ventilated.

10) Development of the disease: August 8th

At the consultation the girl was found to be in a good general condition. On physical examination, pulmonary ventilation was good, there were no adventitious sounds, everything was normal. The patient was 100% cured.

The front chest X-ray control on August 8th. presented a significant improvement of the image. The alveolar interstitial filtering had disappeared in the left upper third, there was less bronchovascular congestion and no filtering in the left lower lung. (see Fig. 2)

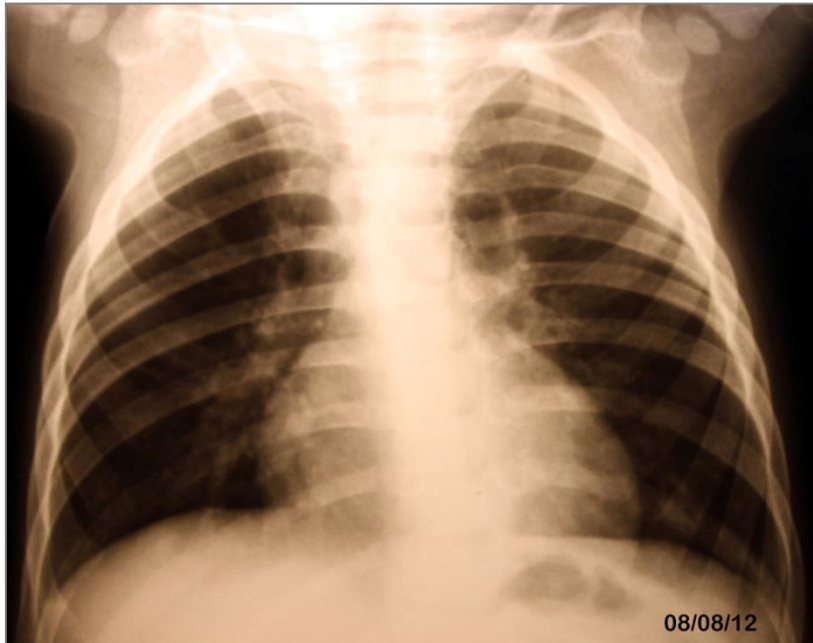


Fig. 2

11) Development and comments on the treatment: the antiviral therapy showed a good clinical response, the patient healed 90% in 5 days.

This fast and effective therapeutic effect of the antiviral Oseltamivir for the influenza virus, demonstrated once again that this disease is caused by a live influenza virus.

If she had not been treated with the specific antiviral Oseltamivir, she would not have recovered or healed and she would still be sick, presenting with relapses and pulmonary, cardiac, renal and other life-threatening complications.

Important comments: The patient had never before been given the anti-influenza vaccine. For the first time, she received the influenza vaccine in this year 2012. She received it in a primary health care center and got sick like other children with prolonged respiratory symptoms, repeating the same disease after receiving the influenza vaccine. She had never had sibilances or bronchospasm before. She had never presented with pneumonia before.

It was the first time she got sick from such an intense viral respiratory prolonged disease that did not cure.

Never before had she presented with such a long influenza in her life, but only after receiving the influenza vaccine. The patient`s mother decided not to take it again.

- This is another case of a nine-month-old baby girl who received the 2012 influenza vaccine (required by law), with serious and life-threatening consequences from a badly manufactured influenza vaccine which has live influenza virus. The disease was correctly diagnosed and treated with the corresponding antiviral, so the patient was completely cured.
- But there are still hundreds of thousands of children affected, undiagnosed and untreated specifically, who suffer from this disease, with serious complications and even hundreds of dead people even in this year 2012.

PART VII

CLINICAL CASES OF PROLONGED INFLUENZA BY MUTATION

CLINICAL CASE N° 1

PROLONGED INFLUENZA BY MUTATION CURED WITH OSELTAMIVIR ANTIVIRAL

CLINICAL HISTORY:

1) Personal information:

Gender: Female

Age: 24 years old

Address: Posadas

Occupation: College student

Nationality: Argentina

2) Consultation date: April 26th, 2006

3) Reason for the consultation: cough, asthenia, headache, rhinitis, fever below 38°, and a prolonged viral respiratory syndrome that was hard to heal.

4) Background of current disease: it started two years ago with not very high fever, 38° C, sweating, asthenia, arthromyalgias, headache, rhinitis, sore throat, cough and mucus, epiphora, congested conjunctiva, bed repose for 7 days. These manifestations repeated every three months and lasted 30 days approximately. In the first days they were mild, and on the six following days they were more severe.

From 2004 until the consultation day in April, she presented 9 exacerbations.

In 2004, 2005 and 2006 she had different treatments with different drugs – antihistamines, anti-inflammatory, nonsteroidal, penicillin, amoxicillin, ampicillin + sulbactam, amoxicilin + sulbactam. In some occasions, she made some progress but the disease was not cured.

5) Important background: she had never had been operated on. She had not got the influenza vaccine.

6) Physical examination: the patient was lucid, blood pressure 110/70 mmHg. There were no heart murmurs. No peculiarities in the respiratory system.

There were slight submaxillary adenomegalies with little pain. The rest of the physical examination did not have peculiarities.

7) Diagnosis: prolonged influenza by mutation.

Doctors that treated her during these three months told her it was a cold.

8) Complementary methods: chest x-rays, a blood test and a urinalysis were requested.

9) Treatment: Oseltamivir antiviral was prescribed, 1 tablet every 12 hours, for 5 days. The patient admitted that after the intake of Oseltamivir, she immediately improved an 80% in 3 days and got totally over it in 10 days.

10) Progression: she did not have symptoms of prolonged influenza by mutation again until the day of the next appointment on February 15th 2007, 10 months after the treatment. The patient got completely healed from her prolonged and viral respiratory symptoms (prolonged influenza by mutation) with Oseltamivir antiviral. The patient had not carried out the required medical studies.

11) Comments: this is another clinical case of "Prolonged influenza by Mutation" which presents exacerbations, 9 times in a three-year progression.

This case shows once again, how prolonged this disease is, with frequent relapses. It affects thousands of people without diagnosis or treatment who suffer this disease with complications and life risk.

CLINICAL CASE N° 2 **PROLONGED INFLUENZA BY MUTATION** **CURED WITH OSELTAMIVIR ANTIVIRAL**

CLINICAL HISTORY:

1) Personal information:

Gender: Female

Age: 62 years old

Address: Posadas

Occupation: Bachelor in social work

Nationality: Argentinian

2) Consultation date: April 26th, 2004

3) Reason for the consultation: intense asthenia, fever, below 38°; muco-serous rhinitis, epistaxis, persistent cough, muco-serous and mucopurulent expectoration, marked dysphonia, night sweat and chills. These symptoms started in 2004 and since then on they happened once and again until the consultation day.

She presented with a prolonged respiratory viral syndrome that had not healed for the last two years and which was also the reason for the consultation.

4) Background of current disease: it started in March 2004 with marked asthenia, diminished strength, fever above 38°, arthromyalgia, profuse sweating in the afternoon and at night, anorexia, sneezing, muco-serous rhinitis, epistaxis without relationship with the rhinitis, intense sore throat,

marked dysphonia, very persistent irritative cough which preceded mucus expectoration and afterwards mucopurulent expectoration, chills at night time, otalgia, photophobia. The patient stayed in bed for 15 days. The same flu manifestations are repeated with less intensity and duration, in May, August and November getting complicated with pneumonia. In 2005, the same flu manifestations repeated in February, March and June and again, complicated with pneumonia. Also in October, it complicated with bronchospasm until November. In 2006, once again the manifestations repeated, in February and April. Then, she came to my office. In 2004, 2005 and 2006 she carried out different treatments with non-steroid anti inflammatories, amoxicillin, ampicillin + sulbactam, erythromycin and antihistamine many times during all the times she was affected but she had bad results. The disease was not cured.

5) Important background: she had never suffered pneumonia, bronchial asthma, or bronchospasm.
She had never had the influenza vaccine.
Acute kidney failure, cured.
Hypothyroidism treated with levothyroxine.
Bladder surgery.

6) Physical examination: lucid patient, afebrile, blood pressure 120/70 mmHg.
No heart murmurs.
Respiratory system without peculiarities.
Abdomen without peculiarities.

7) Diagnosis: "Prolonged Influenza by Mutation". Persistent since 2004 (almost 2 years)

8) Complementary methods: a front view chest x-ray, an electrocardiogram, blood tests and a urinalysis were requested.

9) Treatment: Oseltamivir antiviral was prescribed, one tablet every 12 hours for 5 days. The patient decided not to carry out the treatment. She did not take Oseltamivir and did not come back to consultation.

10) Progression: the patient came back to consultation one year later, in May 2007, due to the same relapse and the same symptoms of intense asthenia, fever below 38°; muco-serous rhinitis, epistaxis, persistent cough, muco-serous and mucopurulent expectoration, important dysphonia, night sweat and chills. During the time she had not come to the hospital, she suffered another exacerbation in June 2006 and three other exacerbations in 2007 which proved the persistence and repetition of the disease.

11) Treatment: once again Oseltamivir was prescribed, one tablet every 12 hours for 5 days and this time, the patient did carry out the complete treatment.
The patient improved immediately. She presented a clinical progression of a 70 % within 48 hours, and at the 7th day, a 100 % improvement. She healed completely and the symptoms of the disease were not repeated.

12) Progression: 5 months after the treatment, the patient had not presented with any symptoms or a relapse, she was completely cured.

Final comment: this is another case of "Prolonged Influenza by Mutation" where for 3 years and a half the patient presented 15 exacerbations due to the mutated flu virus, getting complications with pneumonias and bronchospasm which she had never suffered before. The antiviral treatment with Oseltamivir improved her condition a 70 % in 48 hours and cured completely in 7 days. This very prolonged respiratory viral disease, with a duration of 3 years and half is the "Prolonged Influenza by Mutation" produced by the mutated influenza virus.

This case proves once more the length of the disease, with frequent relapses, complications and life risk just as thousands of affected people without diagnosis or treatment.

Attached comment: at the end of the year 2006, she had a minor surgery done, being in good health condition although it got complicated with a serious bacterial infection, staphylococcus. This is interpreted as the permanence of the prolonged influenza by a mutation virus in the patient. As a disease carrier and facing the stressing surgery situation, the virus might have been reactivated with little virulence effect and enough to enhance the staphylococcus and produce a serious infection. It is already known that the common flu virus enhances the pathogenic effect of the staphylococcus.

In all preoperative of any surgery type, like in this case, it would be convenient to treat with Oseltamivir, one 75mg-tablet every 12 hours for 5 days in order to avoid complications with staphylococcus or any other bacteria.

CLINICAL CASE N° 3

PROLONGED INFLUENZA BY MUTATION

Prolonged influenza by Mutation complicated with primary viral bilateral pneumonia and death.

The treatment with the antiviral Oseltamivir was not carried out

(Community-acquired pneumonia)

CLINICAL HISTORY: YEAR 2005 (Hospitalized patient).

1) Personal information:

Gender: male

Age: 53 years old

Address: Posadas

Occupation: A physician

Nationality: Argentinian

2) Hospitalization date: September 7th, 2005

3) Reason for the consultation: altered mental status, vomiting, and mild diarrhoea.

4) Background of current disease: 7 days before the admission day (Sept 1st), the patient started with manifestations such as viral respiratory exacerbations typical of a flu, and the following symptoms: 38° C fever, asthenia, arthromyalgia, backache, intense and persistent sneezing, muco-serous rhinitis, irritating cough, slight muco-serous expectoration; after these symptoms some others were added: vomiting, mild diarrhoea and altered mental status which motivated the consultation and hospitalization.

5) Important background: this disease had started three month before (June 6th, 2005) with viral respiratory manifestations of a flu and the following symptoms: 38° C fever, asthenia, arthromyalgia, backache, intense and persistent sneezing, muco-serous rhinitis, irritating cough, slight muco-serous expectoration and little diarrhoea. All these acute manifestations lasted 7 days, did not improve thoroughly as time went by, hence, the asthenia, feverishness, cough and rhinitis remained to a lesser extent for three months. Every month he presented with an exacerbation, which lasted four days, with the same symptoms. In total, there were three exacerbations or relapses, in July, August and September. The last relapse was the reason of complications and hospitalization.

Family questioning: the patient was healthy, there was no previous disease, his mother had died two months before his admission to hospital. He had not got the influenza vaccine.

6) Diagnosis: the patient was admitted and immediately taken to intensive care with a diagnosis of:

1. Severe respiratory failure
2. Bilateral pneumonia
3. Viral respiratory syndrome

7) Treatment: the patient was treated with triple coverage of antibiotics that covered gram-positive bacteria, gram-negative and staphylococcus aureus. Oseltamivir antiviral was not prescribed.

8) Complementary methods:

Chest x-ray: Alveolar interstitial infiltration in both lung bases and middle lobes, and condensing images in upper third of left lung.

Lab: blood gas: severe hypoxemia.

Hemoculture, uroculture and coproculture: negative for bacteria.

Negative serology for HIV.

Negative serum virological studies of respiratory virus, chlamydia and mycoplasma pneumoniae, carried out at the Malbrán Institute in Buenos Aires, the results were obtained a month and a half later.

9) Progression: his disease had a bad progression. His condition aggravated quickly in hours. He had a serious respiratory failure and mechanical assistance was required. He did not respond to the treatment

and died on September 9th 2005, two days after the admission. No postmortem examination was done.

10) Final diagnosis:

1. Serious respiratory failure.
2. Primary viral bilateral pneumonia.
3. Prolonged exacerbated viral respiratory syndrome.
4. "Prolonged Influenza by Mutation"

11) Comments: the patient passed away with a diagnosis of viral respiratory disease, primary viral bilateral pneumonia, a serious respiratory failure, a prolonged exacerbated viral respiratory syndrome. It was not known what virus he had been affected by, his death was due to an unknown micro-organism.

This is serious and if we think that the tests of the examined viruses were negative, it is even worse, because that means it is an unknown respiratory virus, and this is what I state: the signs and symptoms are the same as those of the "Prolonged Influenza by Mutation" already described.

This diagnosis is asserted because this is a respiratory viral disease that lasted three months, had three exacerbations or relapses, got worse and more complicated in the last exacerbation and the patient died due to a serious respiratory failure with viral bilateral pneumonia. For this reason, the clinical studies and epidemiology point to "Prolonged Influenza by Mutation"

The wake over was held with the coffin closed and the burial was done before time which led us to think that nothing was to be investigated. Was there any concealment in the virological report from the Malbrán? Or else from of the National Department of Public Health? Was the virus not identified indeed?

This is another case of "Prolonged Influenza by Mutation", complicated with a serious respiratory failure and primary viral bilateral pneumonia. This is one of the affected people who were not diagnosed nor treated and unluckily ended up in death without finding out an etiological diagnosis of the respiratory virus that caused the demise.

We insist on the fact that this is a new mutated and unknown virus that thoroughly coincides with the clinical manifestations and epistemology that caused the death of the patient.

CLINICAL CASE N° 4

PROLONGED INFLUENZA BY MUTATION

"Prolonged influenza by Mutation" complicated with primary pneumonia and cured with Oseltamivir.

(Complicated with community-acquired pneumonia)

CLINICAL HISTORY: year 2006 (outpatient)

1) Personal information:

Gender: male

Age: 68

Address: Posadas

Occupation: A physician

Nationality: Argentinian

2) Consultation date: October 2nd, 2006

3) Reason for the consultation: marked asthenia, arthromyalgia, cough, fever.

4) Background of this disease: it started at the end of August 2006 with influenza and the following symptoms: fever, asthenia, arthromyalgia, muco-serous rhinitis, persistent cough without expectoration. The whole acute manifestation lasted 20 days in a row and the rhinitis decreased slowly.

Then, he recovered though not completely for some days, and on September 29th (in total, he was ill for 30 days) he started to have the same flu symptoms but more intense and in an acute way, with fever, marked asthenia, arthromyalgia, rhinitis, intense coughing, which was frequent, persistent and without expectoration, significant shivering and no dyspnea. This last exacerbated manifestation evolved very fast (3 days).

5) Important background: hypertension, sedentarism and obesity. He did not take the flu vaccine.

6) Progression: the patient consulted a neurologist about his shivering, but the specialist discarded a neurological disorder. After that, on October 1th 2006, he had a front view chest x-ray done where an interstitial-alveolar infiltration was observed in the left lower lobe, and a laminar atelectasis in the right lower lobe. (See fig. 1)

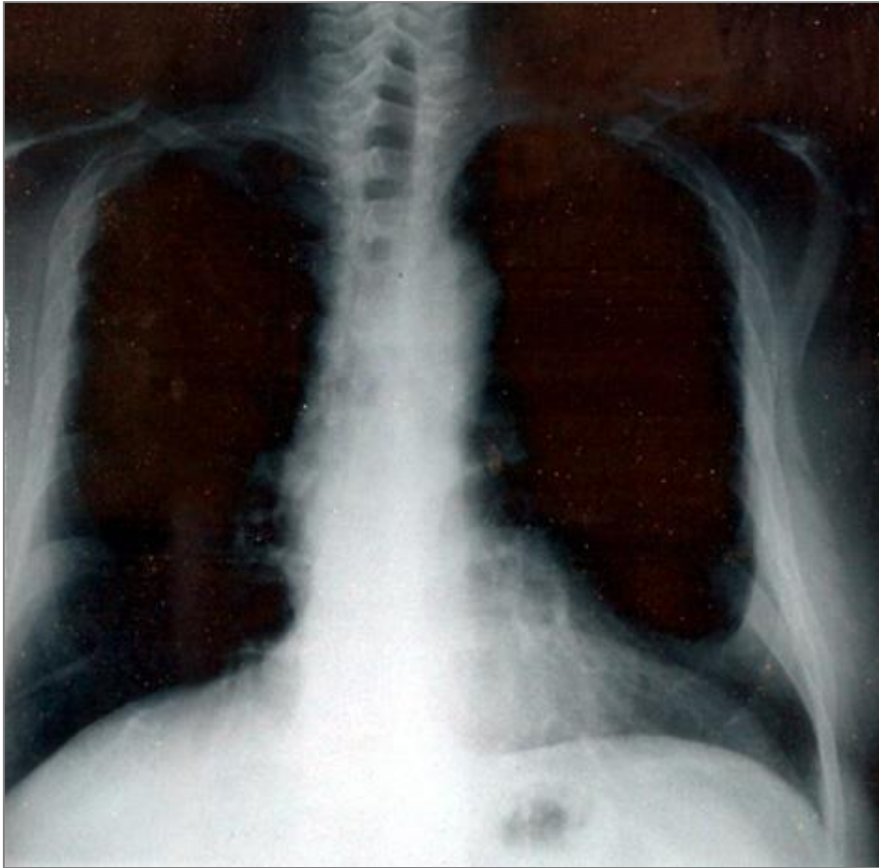

Fig.1: Date: October 1st, 2006

7) Physical examination: a lucid patient, afebrile, Glasgow 15/15, fairly good condition, very asthenic.

Blood pressure: 140/95 mmHg.

Temperature: 38.5° C

Skin and mucous membrane: high temperature, maintained turgor and elasticity. Humid mucous.

Respiratory system: crepitant rales were auscultated in the left base as well as a reduction in the air intake in the right base, no bronchospasm or dyspnoea.

Cardiovascular system: no heart murmurs were auscultated, first and second sounds were maintained.

During the consultation, the front view x-ray which presented alveolar interstitial infiltrates in the left lower lobe was checked.

8) Diagnosis: considering this clinical presentation and the x-ray, the following diagnosis was made:

1. Respiratory viral disease.
2. Primary viral pneumonia.
3. Prolonged Influenza by Mutation.

Diagnosis: Prolonged Influenza by Mutation complicated with primary viral pneumonia.

9) Treatment: this medical treatment with an antiviral drug against flu viruses was prescribed: a dose of Oseltamivir, one 75mg tablet every 8 hours for two days, and then, one every 12 hours. Also two Dexamethasone ampoules (8 mg.), one every 12 hours.

10) Medical decision: the decision of not hospitalizing the patient until the following day was taken and the clinical progression would be checked. Laboratory tests and an electrocardiogram were requested.

11) Progression, October 3rd: on the following day and 4 hours after taking the first tablet, the patient improved up to 50% and after 12 hours, 70%. Also, the clinic noted 70 % improvement. Patient in better general conditions, afebrile, blood pressure 130/90 mmHg.

Respiratory system: few crepitant rales in the left bottom lobe and better air intake in the right bottom lobe.

Lab tests on October 3d:

On the following day, the lab blood tests gave the following interesting piece of information:

Glucose: 2.74 g/L (it was high, he had never had high glucose levels before)

Creatinine 2.2 mg/dl (it was high, he had never had high creatinine levels before)

- P.C.R. (+++++) (high).
- WPC 450000 cells/ml (increased level, thrombocytosis).
- Electrocardiogram: normal, slight increase in the level in the inferior and lateral face, possible pericarditis.
- Front chest X-rays: alveolar interstitial infiltrations in the bottom lobe of the left lung.

12) Diagnosis:

1- Respiratory viral disease.

2- Left bottom lobe primary viral pneumonia

3- Prolonged Influenza by Mutation (33-day progression with a relapse).

4- Acute renal failure.

5- Thrombocytosis.

6- Hyperglucemia.

Presumptive Diagnosis:

7- Type II diabetes (very recent).

8- Pancreatitis.

9- Pericarditis.

Known previous diagnosis:

10- Old arterial hypertension.

11- Obesity.

Main definite diagnosis: "Prolonged Influenza by mutation" complicated with a primary viral pneumonia.

13) Progression and decision taken by the physician: The patient was not hospitalized, due to the fast good clinical evolution. All the elements needed for a diagnosis were there, there was not a respiratory failure or other clinical elements that justified his hospitalization.

14) Treatment:

1- Oseltamivir one tablet every 8 hours for two days, and then one every twelve hours for thirteen days. To sum up, fifteen days.

2- Dexametasone an ampoule for IM administration every 12 hours, 2 doses. When high levels of glucose were detected, one every 12 hours. Also a non-steroid anti-inflammatory, one tablet a day for 7 days.

15) Progression on October 4: The patient was in better conditions, he had no fever, arterial blood pressure 130/90mmHg.

Respiratory system: There were no crepitant rales in the left bottom lobe and a good air intake in the right bottom lobe.

16) Progression and commentary on the treatment: The first time the patient was examined, he was lucid, very asthenic, fever 38.5, not very good general condition.

He was prescribed Oseltamivir, he recovered immediately after taking the medicine, in 4 hours he had recovered 50%. He commented on that to the physician who verified his good clinical recovery.

- 24 hours later he had recovered 70%.
- 7 days later he had recovered 90%.
- 20 days later he had recovered 100%.

This shows the efficient performance of the antiviral drug Oseltamivir that surprised the patient and the physician with a fast clinical recovery.

Analysis of lab blood tests showing the progression of the disease

- From 9000 white blood cells to 7000 (in 7 days).
- 3 band neutrophils, which disappeared later (in 7 days).
- P.C.R. from (+++++) to (+++), (++) , (+) (in 20 days).
- Platelet count 450000 cells/ml to 300000 cells/ml and later 200000 (in 20 days). A thrombocytosis at the beginning.
- Creatinine from 2.2 mg/dl to 1.40 mg/dl (in 20 days).
- Urea 0.60 g/L.
- Glucose from 2.74 g/L to 2.50 g/L – 2.10 g/L – 0.97 g/L (in 20 days).

Comment on the lab blood tests:

There was a WGC rise, there was prevalence of neutrophils and band neutrophils that disappeared afterwards.

Intense inflammation shown by P.C.R (++++), which decreased slowly.

Increase of platelets than decreased slowly later.

Increase of creatinine levels that also decreased slowly even when the patient was not dehydrated.

Increase of glucose that then got normal (he did not have any hyperglucemy background or diabetic relatives)

- This progress could have been shortened with corticosteroids but the physician did not prescribe them because of the high glucose levels.

Comments: it is outstanding that this described clinical case presented other injuries and affected other organs and systems like:

1. An intense inflammatory reaction.
2. An increase of white blood cells as a consequence of the action of the virus or due to the inflammatory reaction.
3. An unusual increase of platelets, that could have led to a major hypercoagulability condition with arterial and venous thrombosis. This is more severe when there are alterations in the arterial endothelium, veins or any other place of the cardiovascular system, like localized or segmented endothelial injuries, for example, from pathologies like atherosclerosis or other that affect the vascular endothelium or could lessen the blood circulation.
4. A kidney injury that was understood as a kidney failure with increase of creatinine and urea.
5. A pancreas injury with glucose increase.

- All this affections that the patient suffered correspond to the disease "Prolonged Influenza by Mutation"

Comments: the patient improved his state quickly with the first dose of Oseltamivir, four hours after the intake, the clinical and subjective improvement reached a 50%. The progression in a few hours and a few days was extraordinary with this treatment.

The neutrophilic leukocytosis was outstanding, the great inflammation shown by the P.C.R (++++), the increase of platelets (thrombocytosis) 450000 cells/ml, increase of glucose and creatinine which also showed the pancreatic and renal affection.

This is another case of "Prolonged Influenza by Mutation" complicated with primary viral pneumonia, out of thousand of cases without diagnosis or treatment, with complications and life risk.

CLINICAL CASE N° 5

PROLONGED INFLUENZA BY MUTATION

"Prolonged influenza by Mutation"

complicated with primary pneumonia

(Infected with community-acquired pneumonia)

CLINICAL HISTORY: Year 2007 (Hospitalized patient)

1) Personal information:

Gender: Male

Age: 47

Address: Posadas
Occupation: Self-employed
Nationality: Argentine

2) Patient hospitalized: in a public hospital

Admission date:

September 6th, 2007 in the emergency room. (1st day)

September 7th, 2007 in a regular room. (2nd day)

Discharge date:

September 13th, 2007

3) Reason for the consultation: hyperthermia, chest pain, asthenia.

4) Background of the current disease: the patient said he had started feeling that way 72 hours before, unquantified asthenia, chills, pleuritic chest pain on the right side.

But this disease had really started 20 days before the consultation with marked asthenia, intense headache, arthromialgias, fever, intense sneezing one after another and impossible to restrain, muco-serous rhinitis, sore throat, dry throat and hot, intense and irritative cough, scarce mucoserous expectoration, bronchospasm, night sweats, palpitations, dizziness, shivering, photophobia, vision loss, hearing loss, drowsiness, anorexia, walking difficulties, strength lessening in lower limbs, hypogastric pain with dysuria and urinary frequency. He had rested in bed for 3 days.

The acute stage of the viral manifestations lasted 7 days; and in total, the affection lasted 20 or 25 days. 72 hours before the consultation, the patient presented with the symptoms of hyperthermia, chills and pleuritic chest pain on right side, symptoms that motivated the consultation and he was hospitalized

5) Important background: 25 years smoking, penicillin allergy.

This disease started indeed in the winter of 2006, presenting with the same clinical manifestations described in the current disease. Then, there were three subsequent viral respiratory relapses that lasted 20 or 25 days, with the same symptoms which he had never suffered before.

In January, March, June, August and September 2007, he presented with the same viral respiratory relapses. In the last month, the disease complicated and he was hospitalized.

In 2007, the viral respiratory relapses lasted the same length of time, but every time the relapse was more intense and serious.

He had never presented with such intense and prolonged viral respiratory manifestations before.

He had never had bronchospasm.

Years before, a flu used to last 4 days at the most and only once a year in the winter.

He had never taken the flu vaccine.

He had friends that were suffering the same viral respiratory and prolonged disease. It was an epidemic.

The patient regarded that this disease was the same as a flu but more intense, prolonged, with relapses and which did not cure even when it was being treated with antibiotics, anti-inflammatories and decongestants.

6) Physical examination:

Arterial blood pressure: 100/60 mmHg.
Heart frequency rate: 130 bpm
Respiratory frequency: 23 bpm
Temperature: 37.8° C
Weight: 76.4 Kg.

The patient was in rather bad conditions, lucid, Glasgow 15/15, febrile, when he was admitted he was in a wheelchair.

Subcutaneous tissue: no edema or emphysema was found.

Mouth: erythematous pharynx, moist mucous.

Respiratory system: palpation: vocal vibrations lessened in his mid right hemithorax.

Percussion: dullness in his mid right hemithorax.

Auscultation: rhonchi and scarce wheezing in both hemithorax but mostly on the right. Decrease in bilateral airintake, no tubal murmur was auscultated.

Cardiovascular system: first and second heart sounds, hypo phonetic. No heart murmurs or added sounds were auscultated. Regular heart rate.

7) Diagnosis:

Pneumonia.

Prolonged viral respiratory syndrome.

Presumptive diagnosis: urinary tract infection.

Other diagnosis: smoking.

8) Complementary methods:

Blood lab tests on September 6th

Hematocrits: 40%

Leukocytes: 21.300 mm³

Band neutrophils: 4 %

Segmented neutrophils: 88 %

Lymphocytes: 8 %

Eosinophils: 0 %

Basophils: 0 %

Monocytes: 0 %

Glucose: 1.67 g/L

Urea: 0.54 g/L

Serum ionogram: Na: 131.5 meq/L

K: 3.93 meq/L

Cl: 97.2 meq/L

Hemoculture and uroculture were requested (September 6th). The treatment with antibiotics started.

Blood lab tests on September 7th

Hematocrits: 34%
Leukocytes: 16000 cells/ml
Neutrophils: 80 %
Lymphocytes: 10 %
Eosinophils: 0 %
Basophils: 0 %
Monocytes: 0 %
Glucose: 1.12 g/L
Uremia: 0.65 g/L
Creatinine: 0.81 ml/min.
Total bilirubin: 0.55 mg/dl
Direct bilirubin: 0.03 mg/dl
GOT: 19 U/L
Alkaline phosphatase: 210 U/L
Cholesterol: 116 mg/dl
Triglycerides: 109 mg/dl
Prothrombin t: 76%
Partial thromboplastin t: 34"
Platelet count: 128000 cells/ml

Comments about the test:

He presented with a neutrophilic leukocytosis, and the urea and creatinine high levels were remarkable. This showed a renal injury in a patient who was normally hydrated. Also the thrombocytopenia.

Front view chest x-ray, September 7th, 2007

Congestive hilar, interstitial alveolar infiltrates in the mid-third of right hemithorax with diffuse border. (See fig. 1)

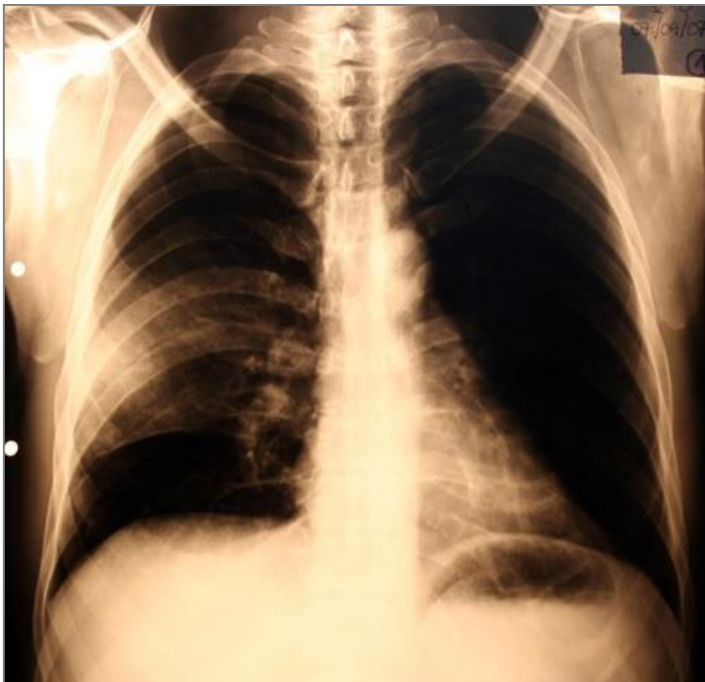


Fig.1: Date: September 7th, 2007

Electrocardiogram:

Sinus rhythm, cardiac frequency rate 130 bpm, "image" of right line incomplete blockade in V₁, V₂.

Final diagnosis:

1. Primary viral pneumonia
2. Prolonged Influenza by Mutation

Other diagnosis:

1. Thrombocytopenia
2. Renal affection (possible kidney failure)

Treatment:

1. Light diet
2. Nebulizations with saline water + sulbatamol, every 6 hours.
3. Levofloxacin 750 mg. every day, oral route.
4. Diclofenac 50 mg. every 8 hours, oral route.
5. Dextrose 5% alternating with saline water 2,5 L a day, parenterally.

Comments: Levofloxacin antibiotic was prescribed because of the patient's allergy to penicillin, diclofenac for the chest pain, a bronchodilator in nebulizations and hydration.

He was not treated with Oseltamivir although it had been requested by the physician in charge. The hospital authority refused permission to administer Oseltamivir.

3rd day of hospitalization. 8th September, 2007 (2nd day on antibiotics)

Blood pressure: 100/60 mmHg

Temperature: 37°

The patient was in not very good general conditions.

Respiratory system: scarce rhonchi and wheezing in his mid right hemithorax, generalized hypoventilation.

No expectoration was present.

Blood lab tests:

Hemoculture: positive for: diplo-coques gram positive.

Typification: streptococcus pneumoniae.

Antibiogram: sensitive to penicillin and by-products.

Uroculture: no development.

Possible diagnosis: secondary bacterial pneumonia.

4th day of hospitalization. 9th September, 2007 (3rd day on antibiotics)

Blood pressure: 110/60 mmHg

Temperature: 36°

The patient still followed the same indications.

5th day of hospitalization. 10th September, 2007 (4th day on antibiotics)

Blood pressure: 100/60 mmHg

Temperature: 36°

The patient was in not so good general conditions. Normotensive and afebrile.

Respiratory system: scarce rhonchi and wheezing in his mid-right hemithorax, generalized hypoventilation. No expectoration.

Laboratory blood tests:

Hematocrit: 40%

Leukocytes: 10300 mm³

Band neutrophils: 5 %

Segmented neutrophils: 52 %

Lymphocytes: 28 %

Eosinophils: 8 %

Basophils: 0 %

Monocytes: 1 %

Myelocytes: 2 %

Metamyelocytes: 4 %

Glucose: 0.80 g/L

Urea: 0.40 g/L

Creatinine: 1.13 mg/dl.

Total bilirubin: 0.42 mg/dl

Direct bilirubin: 0.02 mg/dl

LDH: 548 U/L

GOT: 26 U/L

GPT: 34 U/L

Alkaline phosphatase: 250 U/L

Gamma glutamyltransferase: 115 U/L

Cholesterol: 182 mg/dl

Platelet count: 440000 cells/ml

V.D.R.L. test: non-reactive

H.V.I.: non-reactive

Hepatitis C: non-reactive

Hepatitis B: non-reactive

Abdominal ultrasound: normal

6th day of hospitalization. 11th September, 2007 (5th day on antibiotics)

Arterial blood pressure: 110/70 mmHg.

Temperature: 37.2° C

The patient was in good general conditions, normotensive.

Respiratory system: scarce rhonchi were auscultated in his mid-right hemithorax, generalized hypoventilation in both lungs.

Front view chest x-ray, September 11th 2007

There were still interstitial alveolar infiltrates in his mid-third right hemithorax and the right upper-third was added; both with less radiological density than in the previous x-ray. (See fig. 2)

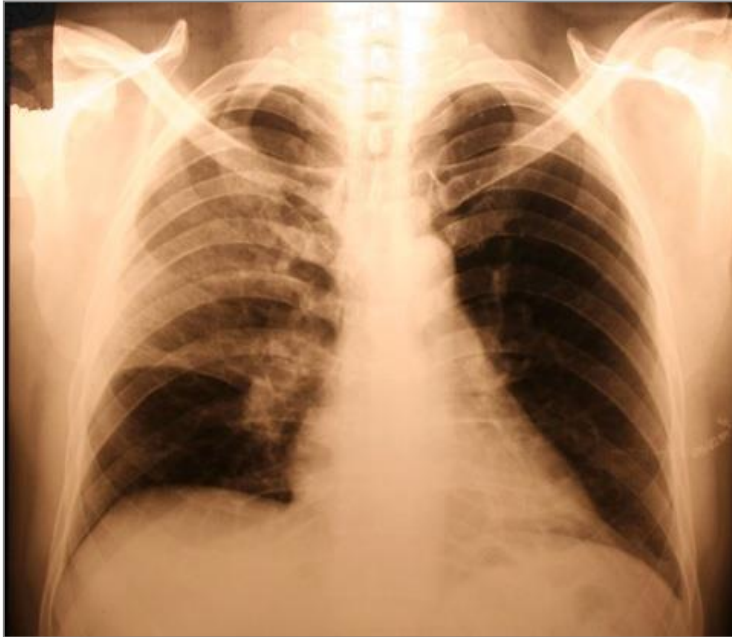


Fig. 2: date: September 11th, 2007

Laboratory:

Serum ionogram: Na: 136 meq/L
K: 6.28 meq/L
Cl: 113 meq/L

Sulbatamol was stopped.

7th day of hospitalization. 12th September, 2007 (6th day with antibiotics)

Arterial blood pressure: 120/70 mm. Hg.

Temperature: 36° C

The patient was in good general conditions, lucid, afebrile, helpful.

Respiratory system: the patient continued with generalized hypoventilation in both lungs, no rhonchi. The doctor's indications were carried on.

8th day of hospitalization. 13th September, 2007 (7th day with antibiotics)

Arterial blood pressure: 110/70 mmHg.

Temperature: 36° C

The patient in good general conditions, he was discharged on this day with an antibiotic treatment for the following 8 days.

Comments: this patient had never taken the influenza vaccine. In winter 2006, he presented the first viral respiratory manifestations that lasted 25 days which he had never suffered before. This clinical manifestation was the same as those patients affected by the flu vaccine.

He presented three exacerbations in 2006 and 5 more in 2007. The last ones in January, March, June, August and September were more intense. He got complicated with bronchospasm and primary viral pneumonia, bronchial bacterial overinfection due to streptococcus pneumoniae, and for this reason he was hospitalized. Secondary bacterial pneumonia? Other complications were: thrombocytopenia and transitory renal affection.

In this case, the indication for antibiotics was the correct one because of the bacterial overinfection. However, a prolonged viral respiratory infection was the cause of the disease, not the bacteria.

What called my attention here, was the scarce mucoserous expectoration for a few days which was mucopurulent and contrasted with the positive hemoculture for streptococcus pneumoniae.

A sputum culture was not performed due to lack of expectoration.

A flu used to last 4 days and it happened once a year in winter.

This patient knew friends who suffered the same viral manifestations, respiratory, prolonged and repetitive which did not cure even with antibiotics in 2007.

In most community-acquired pneumonias, this viral respiratory disease is not diagnosed and no clinical diagnosis of a viral respiratory disease is done.

This is another case among thousands of patients affected by a mutated flu virus whose clinical appearance was described in the year 2000 and had epidemic features in 2004 and 2005, when the number of cases increased considerably. This case from 2007, reaffirmed that this mutated virus kept producing an epidemic with greater intensity.

This disease which I call "Prolonged Influenza by Mutation" or "Prolonged Mutated Flu" is originated in the flu vaccine with a mutation of the flu common virus.

This is another case of the mutated flu virus among thousand of affected patients. This disease is "Prolonged Influenza by Mutation" with serious complications which is life-risking if it is not diagnosed or specifically treated. From the beginning of the year 2000, until 2013, despite all the alerts already notified 13 years ago and with the consequence of an epidemic that started in 2004 and 2005 and continues in 2013, there are thousands of sick people and deaths.

There is still the possibility, even more serious, that this disease could mutate with the avian flu or other flu viruses generating a new flu virus even more lethal and very contagious which could cause a PANDEMIC with millions of sick people and deaths.

CLINICAL CASE REPORT N° 6

PROLONGED INFLUENZA BY MUTATION

"Prolonged Influenza by Mutation"

Complicated with Primary Viral bilateral Pneumonia and IV degree Respiratory Insufficiency (community-acquired pneumonia)

CASE HISTORY: YEAR 2012 (hospitalized patient)

1) Personal information:

Sex: Female.

Age: 50.

Address: Posadas.

Job: a nurse

Nationality: Argentinian

2) Hospitalized patient: at a clinic

Admission date: July 2, 2012 at 11.52 am.

Discharge date: July 6, 2012.

3) Reason for coming to the surgery: Type IV dyspnea, bad general condition, running a temperature, marked asthenia, intense cough, back ache, dysphonia.

4) Antecedents of the present disease: The patient had been healthy before. The condition started with a 38- degree fever, marked asthenia, intense repetitive coughing, (little) mucoserous expectoration, rhinitis with little mucoserous discharge.

She was examined by a physician and prescribed dexamethasone and an antihistamine but her condition did not improve. More symptoms appeared, arthromyalgia, generalized skin hyperesthesia, brochospasm. She was examined again and prescribed the antibiotic azithromycin, and an antihistamine again. Her condition did not improve but had worsened five days before she was hospitalized. Her coughing had become more intense, she had a sore throat, precordial ache and retrosternal pain that increased with deep inspiration, back pain in both lung bases that increased with inspiration, the right hemithorax hurt more. She presented with degree-III dyspnea that developed quickly to degree IV, headache, dysphonia, dizziness, nausea, vomiting.

The expectoration was never mucopurulent.

The rhinitis discharge was never mucopurulent. All the signs and symptoms persisted for 15 days, worsening the last days until she visited the doctor's office on July 2. The physician decided to hospitalize her.

5) Important Antecedents: 1 – High blood pressure for 5 years, treated with hydrochlorothiazide intermittently for a long time. 2 – She was not allergic 3- She did not have asthma – 4- She had never had pneumonia before.

6) Physical examination: The patient was lucid, she had a good sense of time and space. Glasgow 15/15.

She was in bad condition, feverish, with tachycardia, looking very ill, pale, IV-degree dyspnea at rest, coughing continuously and persistently, disphonia, little mucoserous expectoration, there was no nasal or pharyngeal discharge.

Arterial Pressure: 110/60 mmHg

Heart rate: 120 bpm

Respiratory frequency: 24 breaths per minute

Temperature: 37.8°C

Subcutaneous tissue: She did not present edema or emphysema.

Mouth: Erythematous pharynx, humid mucosa.

Respiratory System: Auscultation: Decrease in the lateral air intake. Fine crepitant rales were heard in the base and in the middle lobe of the right hemithorax and smaller-degree fine crepitant rales in the base of the left hemithorax.

There was a smaller air intake mainly in the right themithorax when breathing in and a whizzing noise (of the inspiring sound) due to a reduction of the bronchial calibre (by a spasm or edema of the bronchial mucosa).

Percussion and fist percussion produced pain in both lung bases.

Cardiovascular system: Normal first and second cardiac noise, no murmur or added noises were heard. A regular pulse.

Abdomen: Negative renal fist percussion.

7) Diagnosis at hospitalization: In view of these signs and symptoms, the following diagnosis was made:

- 1) Primary viral bilateral pneumonia.
- 2) III-IV degree lung insufficiency.
- 3) Prolonged Influenza by mutation (15-day evolution).
- 4) Pneumonia through a mutated virus.

5) Community-acquired pneumonia.

6) Prolonged viral respiratory syndrome.

Presumptive Diagnosis: Viral pericarditis.

Other diagnosis: arterial hypertension.

8) Treatment

1 – Antiviral: Oseltamivir 75 mg. every 8 hs. (oral)

2 – IV Dexamethasone 8 mg every 6 hs

3- Venoclysis with saline solution 500 cm³ a day.

4 – A hot water bottle on the chest.

5 – Daily diuresis and weight control.

6 – A light diet.

9) Complementary Methods:

Lab tests on July 2nd.

Hematocrits: 36 %.

Hemoglobin: 11.9 gr-/dl

Leukocytes: 16100 mm³

Bands: 0%

Segmented neutrophils: 80%

Lymphocytes: 12.6 %

Eosinophils: 0.2%

Basophils: 0.3%

Erythrocytes: 4450000/mm³

Leukocytes: 6500/ mm³

Bands: 0%

Lymphocytes: 35%

Monocytes: 6.5%

Glucose in blood: 107 g/L

Creatinine Test: 0.75 mg/dl

E.S.R.: 14mm/ 1st hour

C-reactive protein: 226.41 mg/L (normal value up to 5.00)

Platelet count: 465,000/mm³ (normal value 150,000 up to 450,000)

GOT: 48 U/L (normal value 5-34)

GPT: 86 (U/L) normal value up to 55)

Alkaline Phosphatase: 169 U/L (normal value 40-150)

CPK: 63 U/L

CPK MB: 0.30 ng/ml

HDL: 355 U/L

Troponine I: 0.000 ng/ml

Urine complete tests:

Proteins: positive (+)

Epithelial cells: 4 per field.

Leukocytes: 2-3 per field

Amilase: 71 U/L

Cholesterol: 175 mg/dl

Serum ionogramm: Na: 138 meq/L

K: 2.7 meq/L

Cl: 99 meq/L

Lactate: 2.7 mmol/L (normal value 0.5 – 1.6)

Gases in blood:

pH: 7.493

pCO₂: 34.2 mmHg

ppO₂: 53.8 mmHg

sO₂: 88.6 %

Respiratory virus: Nasal and pharyngeal swab

Method: Direct immunofluorescence

Influenza A virus: negative

Influenza B virus: negative

Parainfluenza: 1, 2, 3: negative

Human respiratory syncytial virus: negative

Adenovirus: negative

A blood culture was requested.

Electrocardiogram: Date: 2 July 2012.

Heart frequency 100 beats per minute, a slight ST depression in DI, DII, AVF, V₅ and V₆. "T" wave voltage reduction in all pre-cordial derivations.

Presumptive Diagnosis: hypopotassemia – pericarditis? (see Fig. 1)

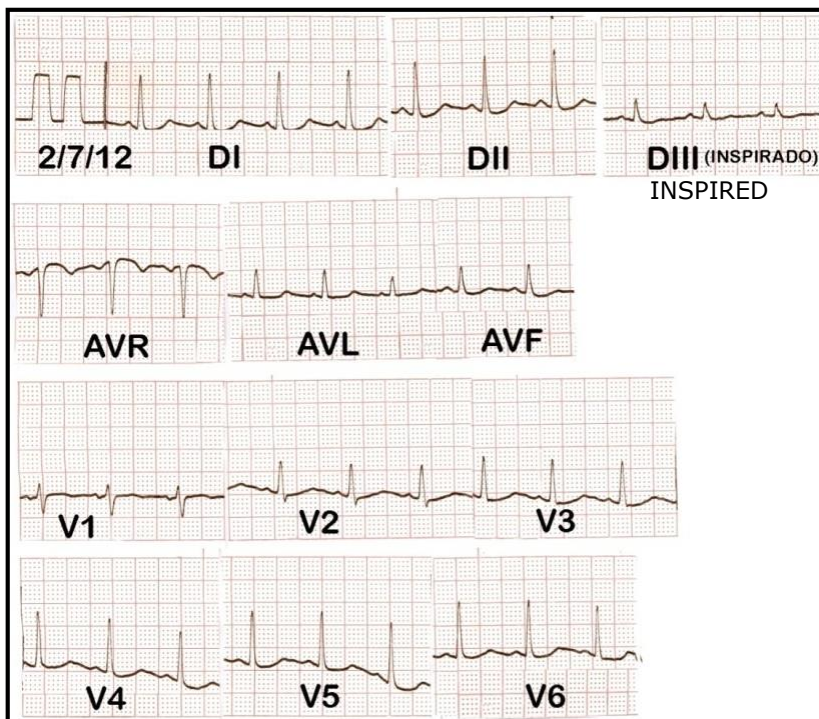
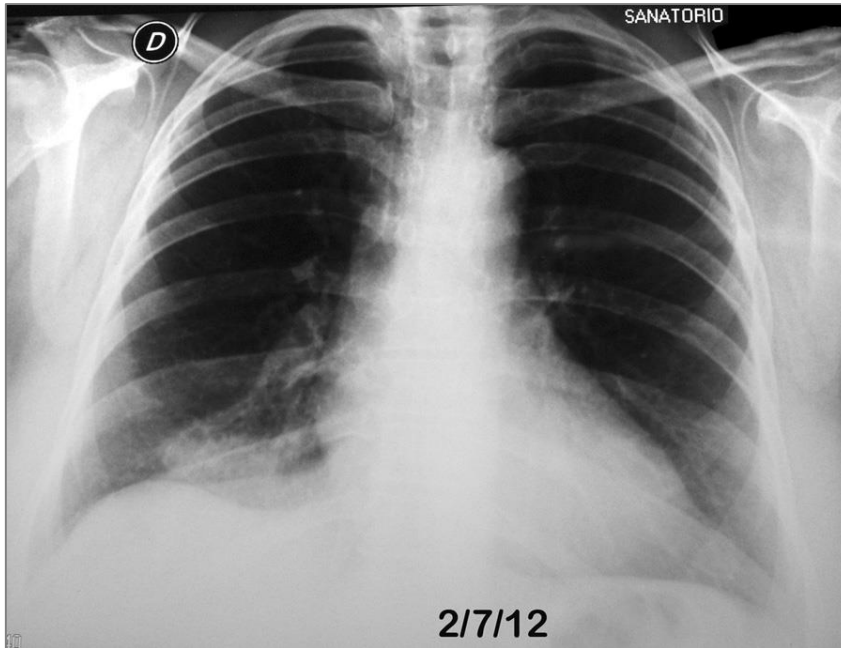


Fig.1. ECG on July 2nd. 2012



Chest X-ray: July 2nd. 2012 Bilateral alveolar interstitial filtering, in both lung bases and middle fields with image of condensation in the right base. Bronchovascular congestion.

Evolution:

5 hours later, after having taken Oseltamivir antiviral 90 mg (3 30-mg. capsules), her condition improved clearly, the respiratory frequency decreased to 14 bpm., her degree-IV dyspnea disappeared and her coughing was reduced 50%.

Comments on the lab tests: There was a leukocytosis with a 16100 white cell count, neutrophils were predominant, very high positive C-reactive protein, high count of platelets, high hepatic enzymes, proteins in the urine, 71 U/L amylase, hyponatremia, hypokalemia, high lactate. There was an alteration of gases in the blood, with hypoxemia and mixed alkalosis, a respiratory insufficiency diagnosis.

The analysis of type A and B influenza respiratory virus, adenovirus, respiratory syncytial virus, the 1,2 and 3 parainfluenza viruses were all negative. Positive results of these tests, especially the flu virus, are obtained when taken on the first three days after the onset of the disease. That is why on the 15th day of the disease, the tests were bound to be negative. Consequently, these negative findings were not relevant for diagnosis.

The serum electrolyte levels were low, due to the chronic use of hydrochlorothiazide.

2nd. Day of Hospitalization : July 3, 2012 (2nd day on Oseltamivir)

The patient's condition was better, there was a clear recovery, she was well oriented to time and space, no fever.

Blood pressure: 150/100 - 130/90 mmHg

Heart rate: 90 beats per minute

Respiratory frequency: 15 bpm

Temperature: 36°C

The heart rate lowered from 120 to 90 and the respiratory frequency from 24 to 15 bpm. She did not run a temperature, her coughing was less intense and frequent, it had decreased 50%.

Lungs: She still had pain in the right base, rough crepitant rales in the base and the middle field of the right lung (the fine crepitant rales disappeared). Little mucoserous expectoration, there was no rhino-pharynx discharge.

Lab Tests: Blood culture report: three samples, inflammatory response. Bacterian culture: first and second control: no development in any of the three samples.

Gases in blood:

pH: 7.408

pCO₂: 43.8 mmHg

pO₂: 73.0 mmHg

sO₂: 94.5%

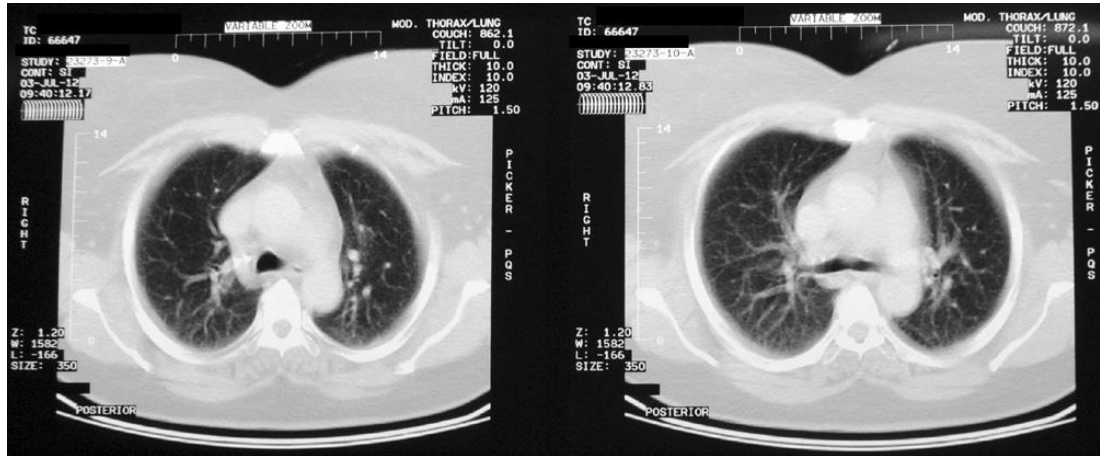
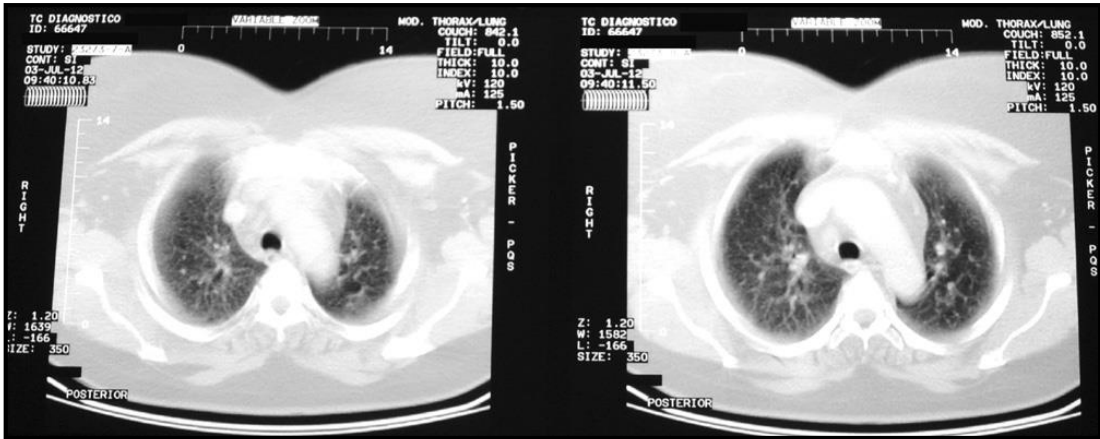
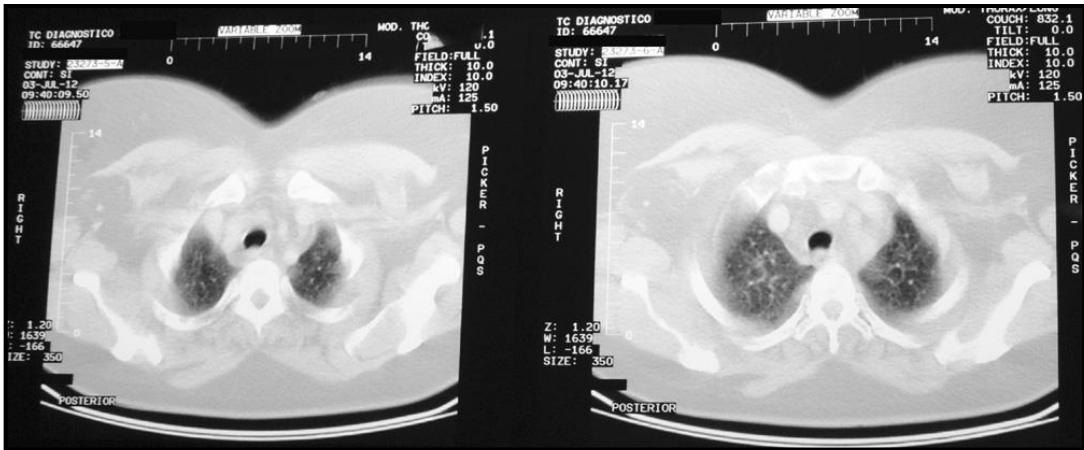
lactate: 1.5

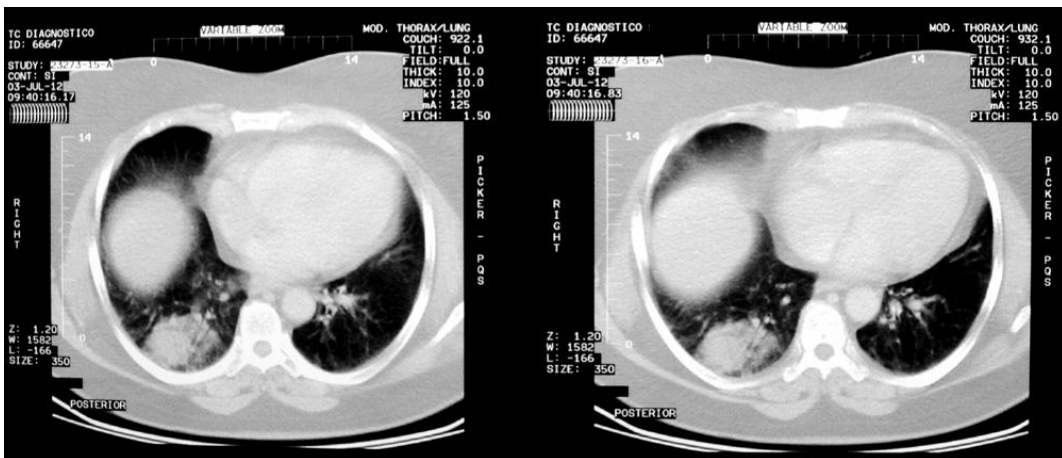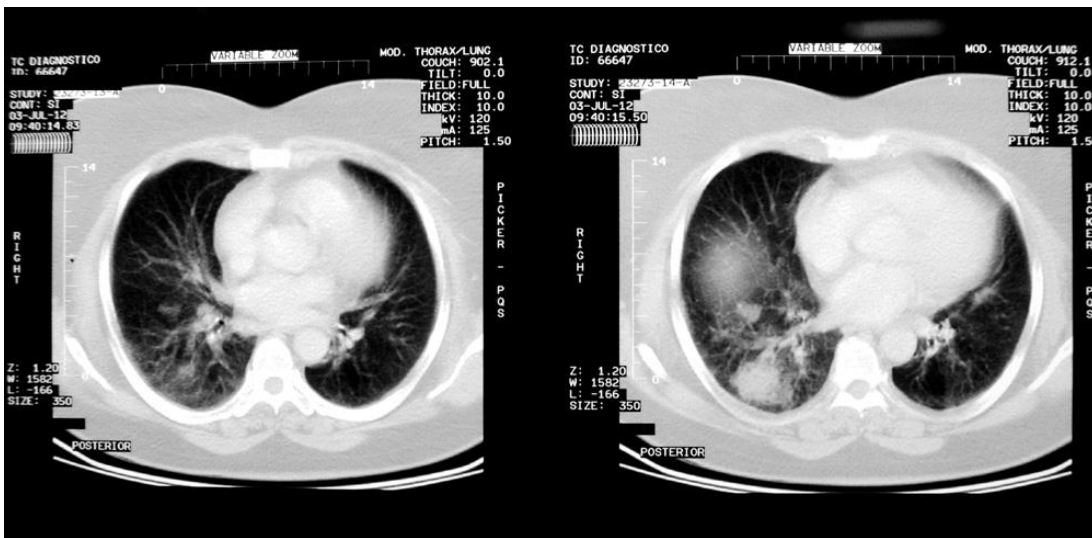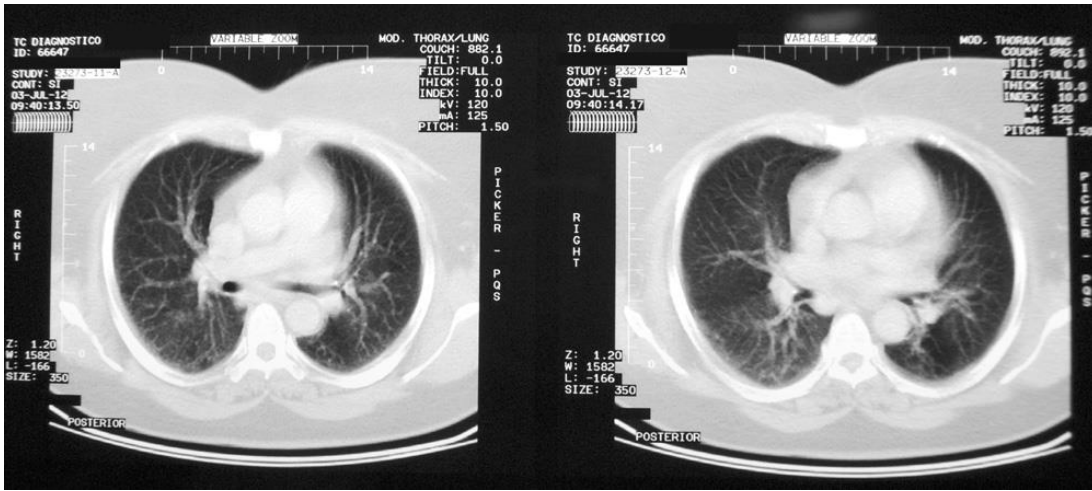Comments: The condition was improving, the recovery was told by the patient and qualified by the physician as a 70 % recovery after 12 hs of treatment.

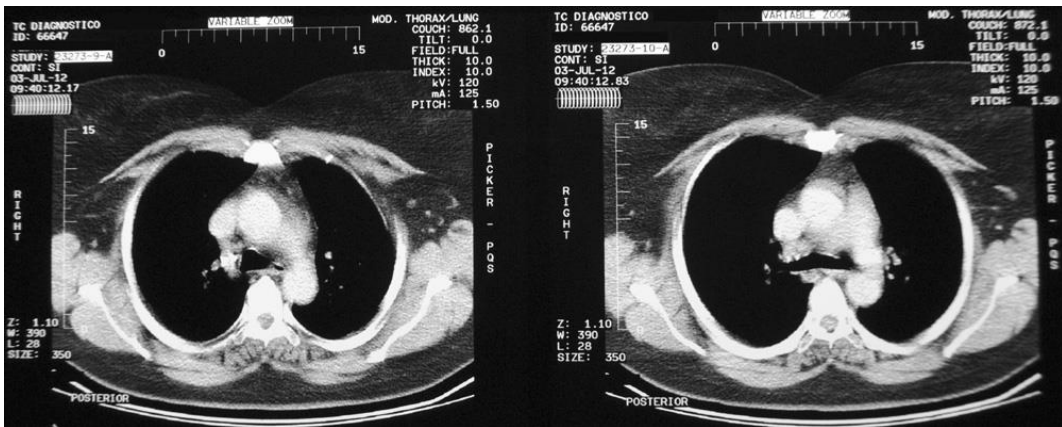
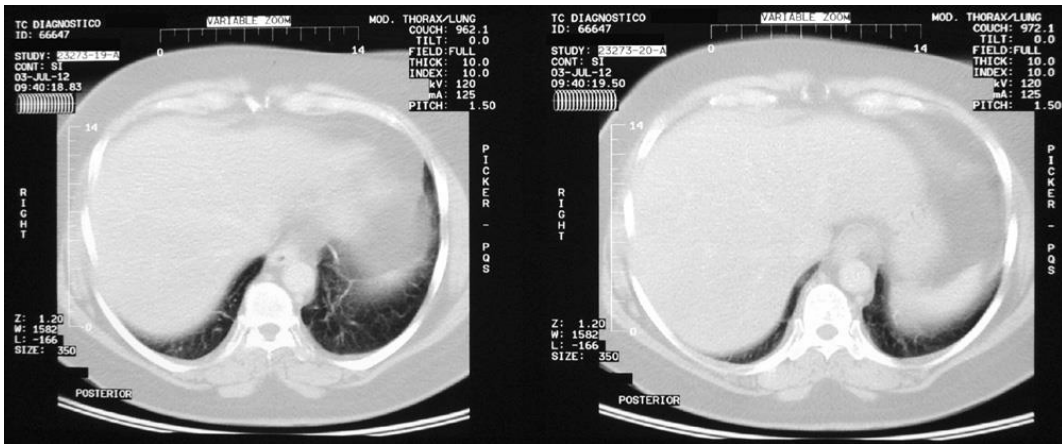
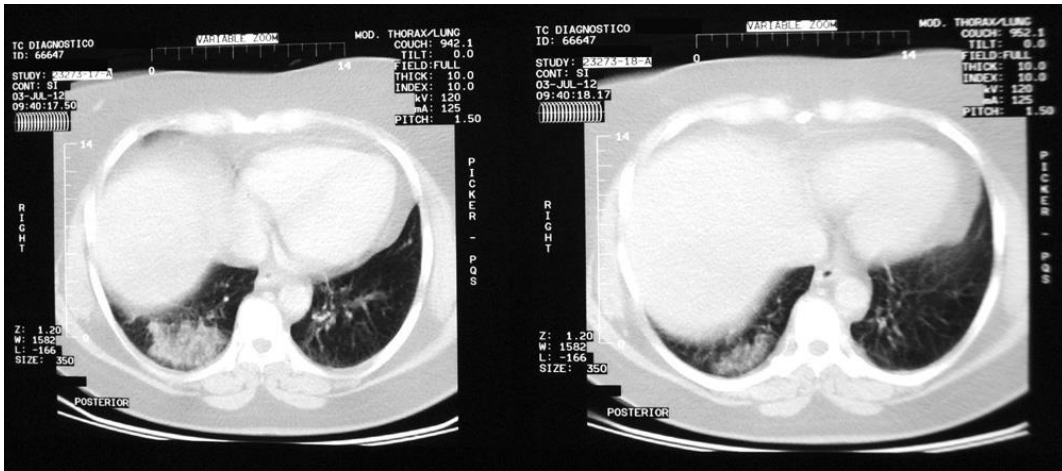
Gases in blood improved, pO₂ improved from 53.8 to 73.0, surmounting respiratory insufficiency, pCO₂ improved from 34.2 to 43.8, la sO₂ de 88.6 improved from 88.6 to 94.5. El pH improved from 7.493 to 7.408 getting out from alkalosis. Lactate lowered from 2.7 to 1.5, showing evidence of recovery and a better prognosis.

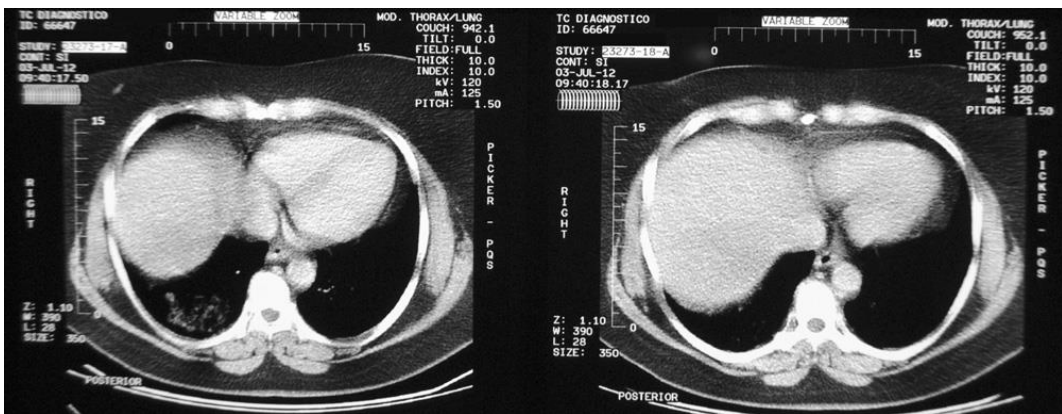
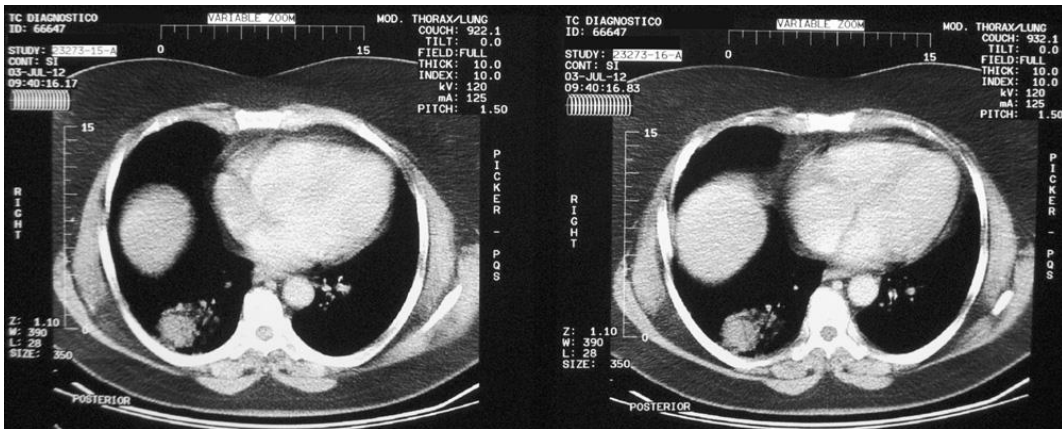
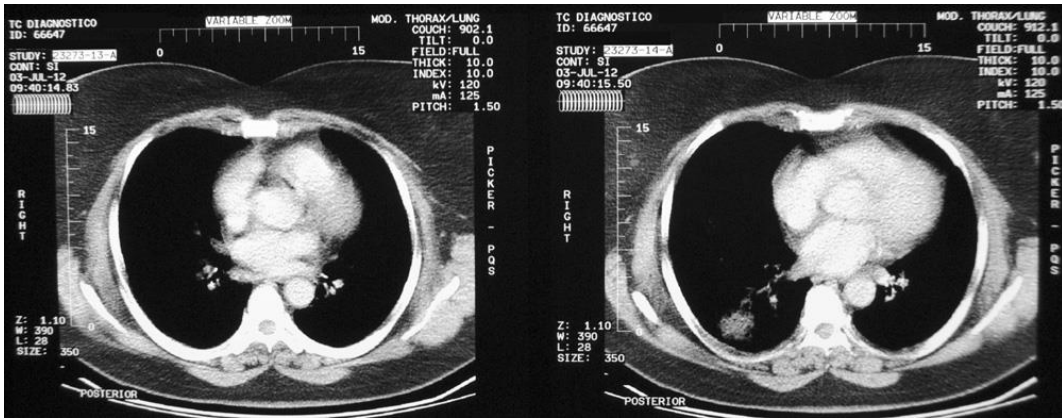
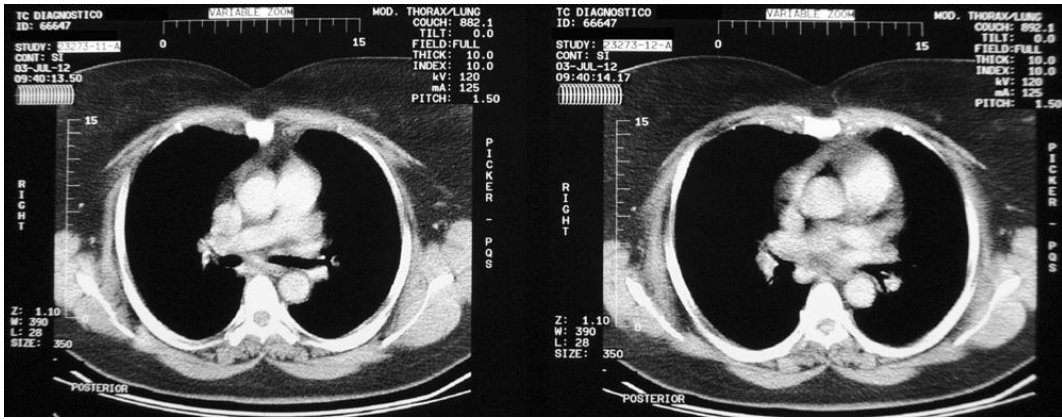
Chest Contrast CT Scan: A technique realized with 10-mm width and increments, programmed in a previous digital radiograph. It confirmed the evidence of pneumonia in the right base, alveolar interstitial filtering in the left base, predominant in the middle field and the apex of the left lung.

An image of alveolar occupation and condensation in the base of the right lung - 9 cm x 4 x 4 approx. in the upper section of the right lower lobe. The same -a bit smaller - image, 2 cm x 1.5 cm. in two places in the left lung. Right isolated 15 m-diameter para-tracheal adenopathy.









Note: The change of generic Dexamethasone to a higher quality commercial brand was prescribed, to receive a better anti-inflammatory effect and an improved medical condition.

Original 75-mg Oseltamivir was obtained. The patient went on receiving 75-mg capsules every 8 hours.

3rd. Day of Hospitalization: July 4, 2012 (3rd day on Oseltamivir)

The patient was in a better general condition, she did not have a fever, she did not cough during the day, and only at night she had a little cough.

Blood pressure: 140/100 – 140/90 mmHg

Temperature: 36° C

Lungs: She had less lung secretions in the right lung and in the left lung, she did not present with fine crackles, but she presented with coarse crackles in the right lung base at inspiration.

Lab Tests on July 4th:

C-reactive Protein: 154.30 mg/l

Amilasuria: 31.0 U/hour (normal value up to 17 U/hour)

Alkaline Phosphatase: 152 U/L

Hematocrits: 34.0%

Hemoglobin: 11.3 gr/dl

Creatinine: 0.65 mg/dl

Serum ionogramm: Na: 141 meq/L

K: 3.5 meq/L

Cl: 106 meq/L

Coagulogram: Normal.

Prothrombine Time: 80%

APTT: 26%

LDH: 313 U/L

All the viral tests reports were negative.

The C-reactive protein lowered to 154.3, inflammation was better, amilasuria still high (31), showing a pancreatic inflammation or lesion that had happened some days before.

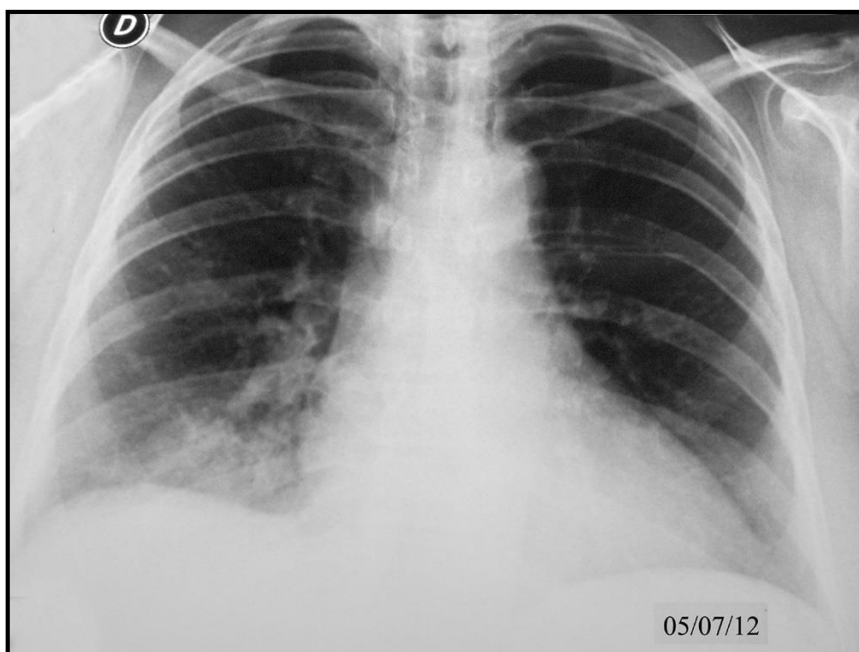
4th. Day of Hospitalization: July 5, 2012 (4th day on Oseltamivir)

The patient was in a much better condition with a 90 % clinical recovery. The cough disappeared completely.

Blood pressure: 120/80 – 140/100 mmHg

Temperature: 36°C

Lungs: No lung secretions were heard, neither fine nor coarse crackles in the right base, or in any lung part, very mild bronchial spasm in the right base.



Chest Rx – July 5th, 2012: a slight reduction in the condensation image with more diffuse borders in the right base, with a slight reduction of the alveolar interstitial infiltrates in the right and left bases. (The radiological evolution improved)

Treatment: Dexamethasone was reduced from 8 mg. to 4 mg. every 6 hours.

5th. Day of Hospitalization: July 6, 2012 (5th day on Oseltamivir)

The patient was a better general condition, she was clinically recovered in 90%.

Blood pressure: 140/90 120/90 mmHg

Temperature: 36.2°C

Heart rate: 75 bpm

Lungs: She did not present with dyspnea at rest, or on exertion. She did not present with spontaneous back thoracic pain, or deep inspiration, she did not present with any kind of crackles in either lung. It was a good fast clinical recovery.

Lab Tests:

Leukocytes: 11000
Hematocrits: 31.4 %
Hemoglobin: 10.2 gr/dl
Creatinine: 0.63 mg/dl
ESR: 8 mm/1st hour
C-reactive protein: 3.51 mg/L (normal value up to 5.00)
Platelet Count: 419000 /mm³
GOT: 35 U/L (normal value 5-34)
GPT: 72 U/L (normal value up to 55)
Alkaline Phosphatase: 134 U/L (Normal value 40-150)
Glutamyltranspeptidase: 94 U/L (normal value 9-36)
LDH: 352 U/L
Cholesterol: 172 mg/dl

Gases in blood:

pH: 7.439
pCO₂: 41.5 mmHg
pO₂: 76.0 mmHg
sO₂: 95.5%

Serum Ionogram: Na: 142.0 meq/L
K: 3.4 meq/L
Cl: 105 meq/L

C-reactive protein lowered to 35, the platelet count lowered and were normal. Hepatic enzymes started to go down, ESR lowered from 14 to 8 mm/1hour, glutamyltranspeptidase was high 94 U/L, the serum ionogram became normal, leukocytes lowered.

A progressive reduction of hematocrits in the period of 6 days but no clinical reason was found, nor a hemorrhage nor other causes. This reduction of hematocrits could be caused by the same prolonged flu through mutation, but it cannot be explained yet by which mechanism this happened.

There was also a progressive reduction in the creatinine (with normal values). There were also proteins in urine, showing a temporary kidney lesion.

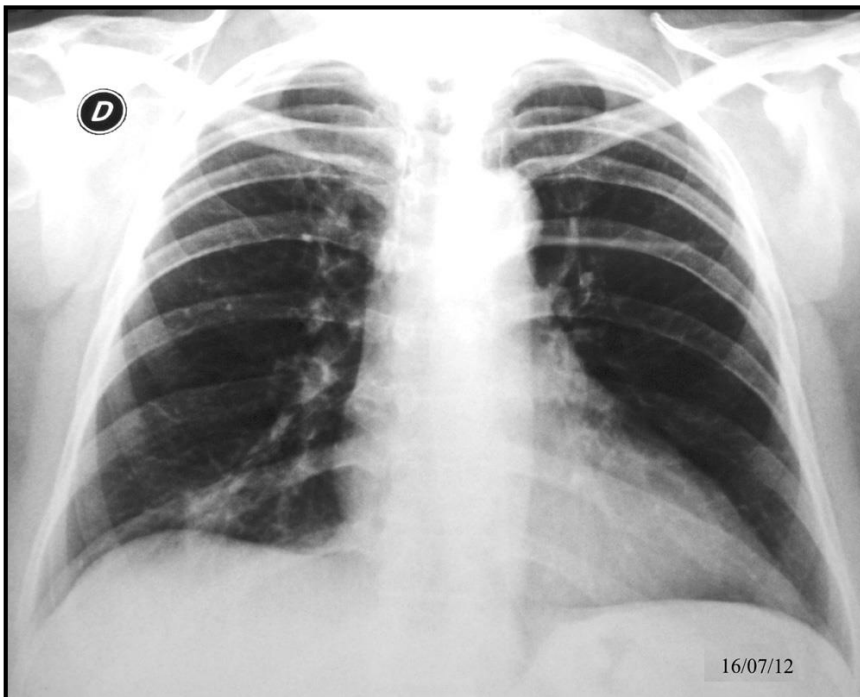
Comments:

What is extraordinary in the evolution of this patient is that with a diagnosis of primary bilateral viral pneumonia with serious lung insufficiency, she recovered in 24 hs. And a recovery of 90% in three days of treatment with

Oseltamivir antiviral. This shows with proofs and evidence that the disease was caused by a mutation of a community-acquired virus. She left the hospital on July 6, 2012, taking the antiviral oseltamivir, 75 mg every 12 hs. for 5 days.

Evolution: 16 July 2012: the patient came back to the office, having finished ten days of treatment with the antiviral Oseltamivir. On examining the patient, she was found to be in good general conditions, blood pressure 150/90, no fever, good lung ventilation without any crackles nor added noise nor bronchospasm. The patient expressed she was fully recovered (100%) and clinically a 100% healing was observed.

The ECG on that day July 16, 2012, was normal.



Chest Rx July 16, 2012: The alveolar interstitial filtering disappeared from both lung bases, sequel image of pneumonia, smaller and rounded in the right base. The bronchovascular congestion disappeared.

Comments:

The patient showed the following diseases: A leukocytosis of 16,000 white cells , predominantly neutrophils.

An intense inflammatory answer, shown by a very high C-reactive protein. Alteration of gases in blood with degree IV respiratory insufficiency.

A pericarditis shown by clinical symptoms.

High platelets (an increase in the coagulation state, with risks of thrombosis).

Mild hepatic disease.

Mild pancreatic inflammation.

Mild temporary kidney disease.

Hydroelectrolytic alteration with low numbers in sodium, potassium and chloride due to chronic use of hydrochlorothiazide.

Negative blood cultures, showing that it was not a bacterial pneumonia.

The Chest Contrast CT Scan agrees with the pneumonia diagnosis and relates to and symptoms at physical examination. What is remarkable is that it detected alveolar interstitial infiltrates in the right upper lung field and left middle and upper lung fields diagnosing that the viral infection spread to the whole of both lungs. There were two smaller pneumonia infections focuses in the left lung which had not been diagnosed by the x-rays. This information provided by the chest contrast CT scan are very important and have to be taken into consideration as it offers diagnostic precision of the presentation and extent of the pneumonia in both lungs. This is the reason why it is advised to request one in any viral pneumonia.

The fast recovery in these cases of Primary Viral Bilateral Pneumonia was due to the Antiviral Oseltamivir, what is a strong evidence and proof . It was confirmed by the signs and symptoms and the effective response to the treatment. Prolonged Influenza by mutation is a viral disease caused by a new mutated community-acquired influenza virus.

This is another case of Prolonged Influenza by mutation in this year 2012, confirmed as a proof and evidence. Besides, this new clinical form of influenza has settled permanently in, and is displacing common influenza in Argentina and in the whole world. It is worrying that international organizations keep this new disease secret causing millions of dead people.

The main wish of saving millions of people makes us keep on working on the spread of the news about this new clinical form of Prolonged Influenza by Mutation, so that it gets recognized, diagnosed and treated.

THANKS

- To God above anything for these 17 years of permatent guidance. I ask God and Jesus Christ to help us solve this serious situation as soon as possible.
- To all the affected patients who could give testimony and to their relatives who also helped with their testimonies in the research.
- To the doctors, nurses and all the stuff who helped with their testimonies and experience in the research.
- To all those who in one way or another helped in the research.
- To my wife and children who accompanied me, backed me and put up with all the difficulties in these last 17 years.
- To Andrés and Gabriel to help move forward with the investigation.

Jorge A. Derna

BIBLIOGRAPHY

- From the autor´s own library.
- Mandell GL, Bennett JE, Dolin R. «Enfermedades infecciosas, principios y prácticas». ED. Elsevier, Madrid, 2006.
- Mandell GL, Bennett JE, Dolin R. «Enfermedades infecciosas, principios y prácticas». ED. Panamericana, Buenos Aires, 1997.
- Osborn AG. «Neurorradiología diagnóstica». ED. Harcourt-Brace.
- Farreras VP, Rozman C. «Medicina interna». ED. Marín S.A. Barcelona, 1978.
- Braunwald E. «Tratado de cardiología». ED. Interamericana, México, 1984.
- Lozada B, Dussaut A. «Marcapasos cardíacos». ED. Celsius, España, 1982.
- Schaposnik F. «Semiología». ED. El Ateneo, Buenos Aires, 1977.
- Mazzei ES, Rozman C. «Semiotecnia y Fisiopatología». ED. El Ateneo, Buenos Aires, 1980.
- Robbins SL. «Patología estructural y funcional». ED. Interamericana, México, 1976.
- Lagman J. «Embriología médica». ED. Interamericana, México, 1976.
- West JB. «Fisiología respiratoria». ED. Panamericana, Buenos Aires, 1981.
- Bonduel AA, Elizalde F, Murtagh J, Rivarola JE. «Manual de medicina infantil». ED. El Ateneo, Buenos Aires, 1979.
- Thompson V, Bertelli J, Zubizarreta J, Campos JR. «Compendio de otorrinolaringología». ED. El Ateneo, Buenos Aires, 1977.
- *Internet: medical and scientific information about the influenza virus, the avian flu virus, the anti-influenza vaccine, antivirals for the influenza virus, the antiviral Oseltamivir, epidemics and pandemics.*

Rationale of the Publication of this Book

The main reason why this book has been published is to let people know about this new undiagnosed disease. So far this information has not been reported in any medical literature. This undiagnosed disease is described in this book so that doctors will know it and recognize it so as to agree on a diagnosis and apply the correct medical treatment in order to heal, improve and prevent or diminish complications, and of course to save lives. Also, it is important that all medical centres and other concerned entities get aware of this problem.

This new disease is a prolonged viral one that affects mainly the respiratory system and other organs and systems of the body. It is called "prolonged influenza" because of its resemblance to the common flu. However, in this case, it is more severe and it lasts longer -up to 30, 60, 90 days or more, with relapses.

Research on influenza and the anti-influenza vaccine from 1998 to 2013. It continued with a greater epidemic, pandemic and endemic incidence since 2013 to 2017.

He described a new disease which was not known yet, "Prolonged Influenza". He warned about the imminent mutation of this contagious disease with the common flu virus and its epidemic in unvaccinated people in 1998. This mutation happened in 2000. The condition appeared in healthy people who had not been vaccinated with the flu vaccine. It is called "Prolonged Influenza through Mutation". There was an epidemic in the years 2004, 2005, 2006, 2007 until 2013. It continued with a greater epidemic, pandemic and endemic incidence from 2013 to 2017 in Argentina and other countries in the world.

This disease is produced due to the action of the virus of the influenza vaccine in 30 % of those who have been vaccinated. The "prolonged influenza" starts a few days after the vaccination, it lasts a long time and it leads to complications; it can be transmitted to others and it can even cause death. Also, the mutation that is produced from the combination with the virus of the common flu has brought about a new mutated virus which is more contagious. The new disease is called "Prolonged Influenza through Mutation".

Because of its major contagious effect, the "Prolonged Influenza through Mutation" has not only replaced the common flu but it also has exceeded it. This is a serious problem as we have suffered an epidemic during the last years, which can still cause a pandemic. If that happened, the virus would absolutely take a foothold in the world.

The influenza virus will mutate and combine with the avian flu virus, increasing its contagious capacity and duration. Its pathological effects and mortality will increase from 50 % to 80 or 90 %, thus producing new epidemics and pandemics killing millions of people. Thus, it is a more lethal and pathological avian flu virus which will bring about economical, social, political, geographical, strategic and other consequences which are impossible to define yet.

For all the reasons mentioned above, this book is dedicated to safeguard life above anything else.

Once again, this matter is presented to the national and international authorities. The mutation already exists, though it is still possible to take the corresponding health measures urgently so as to stop and solve this epidemic.

Another mutation will be produced with the avian flu virus which will also lead to epidemics and pandemics which will kill millions of people.

This global warning is to avoid a new mutation of the avian flu virus and therefore avoid another serious disease.

The medical description of this disease is essentially based on clinical studies and epidemiology. This clinical description is complete, wide and

detailed. Patients have been examined and their relatives have been questioned taking the necessary time, with 95% diagnostic accuracy. There is a clear epidemiologic relationship between this diagnosis and other similar cases along the years, even in those years of investigation.

Physical examinations and complementary methods help doctor to diagnose.

The medical description of this disease is essentially based on clinical studies and epidemiology. This clinical description is complete, wide and detailed, **and is fundamentally based on the questioning to the patient or his relatives. This questioning is very lengthy, performed in the necessary time – longer than the common questioning – thus, there is 95% accuracy in the diagnostic.**